

Original Article

Postmortem computed tomography for diagnosis of cause of death in male prisoners

Saba Sohail,¹ Farhat Hussain Mirza,² Qamar Salam Khan³

Radiology Department,^{1,3} Department of Forensic Medicine,² Dow Medical College, Dow University of Health Sciences, Karachi.

Abstract

Objective: To determine the utility of postmortem CT (PMCT) examination in establishing the cause of death among male prisoners dying in Karachi jails.

Methods: A descriptive study was carried out from February 2006 to September 2007, CT Scan section, Civil Hospital Karachi and the Mortuary, Dow Medical College, Dow University of Health Sciences, Karachi. Adult male prisoners dying in the Karachi central prison and referred to the study setting for determining the cause of death for medico legal purpose were included. Female prisoners and those cases where the final report of cause of death was not available were excluded. CT scan of the vital body regions (head, neck, thorax, abdomen and pelvis) was carried out in all cases. The scan was read and reported by two radiologists. Anatomical dissection based autopsy was carried out by the forensic expert. Final report regarding the cause of death was issued by the forensic expert based on the combined findings, histopathology, toxicology results and circumstantial evidence. The CT scan and autopsy findings were compared and percentage agreement was determined using kappa statistics.

Results: There were 14 cases in all with mean age of 41.2 ± 17 years. The alleged mode of death was custodial torture in all cases. CT scan determined the cause of death to be natural cardio-respiratory failure in 10, strangulation in 01, pulmonary tuberculosis (TB) in 02 and trauma to spine in 01 case. The autopsy determined natural death in 11 and pulmonary TB in 02 and asphyxia in 01. The percentage agreement between CT and autopsy was 92% ($k=0.92$) and between CT and finalized cause of death was 100% ($k=1.0$).

Conclusion: PMCT is as effective as dissection autopsy in identifying pulmonary infections and natural causes of death. It is more effective in identifying vertebral fractures which may exclude hanging and corroborate trauma to spine (JPMA 60:4; 2010).

Introduction

Various known as 'virtual autopsy' or 'virtopsy' the concept of autopsy imaging took its roots from Japan and Switzerland.¹⁻⁴ Conventionally, x-rays have been used in imaging the dead bodies while dissection based autopsy has remained the gold standard for examination of the deceased.^{5,6} It was realized that certain parts of the body such as the neck and the spine are not easily dissected; moreover rigor mortis hinders adequate radiography of skeleton so that spinal fractures may remain undiscovered.^{3,7-9} In fact high neck region and spine are notoriously difficult to dissect even on autopsy.³ Use of advanced computer based imaging techniques such as Computerized Tomography (CT) and Magnetic Resonance Imaging (MRI) can overcome this difficulty which is the rationale behind autopsy imaging.

There have been Western reports of clinical autopsies utilizing autopsy imaging with postmortem CT (PMCT) and/or MRI for a myriad reasons ranging from sudden infant deaths, aortic aneurysm rupture, drowning, brain death diagnosis, hepatocellular carcinoma, tuberculosis, military air mishaps and fatal cerebral gas embolism from compressed air diving.^{5,10-17} The main purpose behind these was academic research and determining survival in a few.

Medico legal autopsy, on the other hand, is a different entity with primary aim at determining the cause of death for medico legal purpose that could be tried at a court of law.⁵ Both the clinical and medico legal autopsy series have been reported from Pakistan.^{18,19} None utilized CT which remains an under utilized modality in local medico legal practice despite its potential of non invasive detailed gross anatomical imaging that can always be reviewed by another observer without repeating the study while a visual first hand examination or a dissection autopsy can not be subjected to the same. Even if one repeats the autopsy, appearances would never be the same as that in the previous examination.

Deaths occurring in custody are often alleged to be unnatural i.e. not caused by ageing, natural cardio-respiratory failure or morbidity. CT in that context can complement the dissection based and visual autopsy to provide hard copy images of the body revealing subtle fractures in anatomically different areas particularly when trauma or physical torture is the alleged cause of death. No such CT-based forensic post mortem study was found in local or western literature till the time of writing these lines.

The objective of this study was to determine the PMCT findings in detecting the cause of death in male prisoners dying in custody with custodial torture being the alleged cause of death.

Methods

This descriptive study was prospectively conducted from February 2006 to September 2007 at the CT scan section, Civil Hospital Karachi and the Mortuary, Dow Medical College, Dow University of Health Sciences, Karachi with collaboration between the Radiology and the Forensic Medicine departments of the institute. Inclusion criteria was male prisoner's dead body referred for PMCT at the study setting from the medico legal sections of Civil Hospital or Jinnah Post Graduate Medical Centre Karachi, for determining the cause of death in alleged case of physical torture. Only those corpses were included where an official requisition from the referring medico legal authority along with confirmed reports of cause of death as surmised by the CT, autopsy, and chemical analysis of body fluids and histopathology of visceral specimens. Female prisoners and those with incomplete data regarding the cause of death were excluded.

PMCT was conducted prior to autopsy and 10-15 mm axial sections, non helical CT sections were acquired from the vault of skull up to the lower gluteal fold including the upper limbs and the genitalia. The scanning protocol was the standard plain scan protocol for every region in terms of pitch, exposure and other technical factors. Lower limbs (from thighs to toes) were only included if specifically requested. All bodies were positioned and clothed as received in order to avoid post mortem artifacts and breaking of rigor mortis.²⁰ CT table was covered with an artifact free radiolucent sheet to avoid artifacts as well as table contamination. No contrast agent of any kind was administered through any body port.

Images obtained were viewed at soft tissues and bone windows both at console and in the hard copy form, with electronic measurements of size and density as and when required. Sections were read for anatomical configuration, densities, edema, skeletal or visceral or cartilage fractures, haemorrhages, foreign bodies, froth or fluid in the air ways, cardiovascular thrombi, soft tissue decomposition signs, and incidental findings such as pneumonic consolidation, tumours, parasitic calcifications, calculi and cysts.

Findings were reviewed by two qualified radiologists with expertise in CT scanning (authors 1 and 3). Visual and dissection-based autopsy was conducted by a senior forensic pathology expert. Final report regarding the cause of death was issued by the forensic expert based on the combined findings, histopathology, and toxicology results and circumstantial evidence.

The identity and circumstances of every case were kept confidential for the purpose of writing this study. The CT scan and autopsy findings were compared and percentage agreement was determined using Cohen's kappa statistics on SPSS version 14. K values range was labeled from -1

(complete disagreement) through 0 (chance agreement) to +1 (complete agreement).

Results

There were a total of 14 cases which fulfilled the inclusion criteria. Detailed history was available in only two cases at the time of reporting the CT scan. Rigor mortis was present in all cases causing difficulty in true positioning of the body particularly of lower limbs. Two cases bore external marks of injury- one on neck suggesting strangulation that the referring authority claimed to be due to hanging (case no. 4), and the other being a bruise in the left mastoid region (case 14) that turned out to be a post mortem haematoma.

The age of the patients ranged from 22 to 75 years with mean of 41.2 ± 17 years and mode of 30 (03 out of 14). Majority (n= 12, 84.71%) were under 50 years of age (range from 24 to 75 years).

Table 1 show the case wise CT and autopsy findings with final cause of death as submitted and contested at the Court of law. PMCT findings consistently present in all the cases were diffuse cerebral edema and dependent lung congestion. Clotted blood was seen in the atria, ventricles,

pulmonary artery and major aortic branches in 02 cases (14.28%). One case each (7.6%) showed signs of decomposition in the form of air in renal parenchyma, pericardial cavity and walls of intestines and thoracic esophagus (Figure A, B). The single case with history of hanging but signs of strangulation showed fracture of thyroid cartilage lamina and diffuse mucosal laryngeal edema with intact cervical vertebrae thus excluding hanging. Age related arterial calcifications and degenerative changes in spine were seen in patients older than 60 years. One case each (7.6%) showed segmental consolidation in left upper lobe; and the other bilateral pleural effusion with collapse and consolidation of lower lobes (Figure C).

CT detected two cases of fractures of distal most spinal column that the dissection and visual autopsy could not find as the vertebral column was not explored in either. The suspected mode of death in both the cases was alleged custodial torture. One of those cases also showed non dependent haematoma in the nasal region.

CT scan determined the cause of death to be natural cardio-respiratory failure in 10, strangulation in 01, pulmonary tuberculosis (TB) in 02 and trauma to

Table: Comparison of the CT and autopsy findings with the final cause of death.

Case number	Age in years	CT findings	Autopsy findings	Final cause of death
1	45	Fracture 5th lumbar vertebra, haematoma at nasion, putrefaction of extremities	haematoma at nasion, putrefaction of extremities	Possible spinal shock
2	44	DBE*, DLC†, clots in atria, ventricles, pulmonary artery and aortic branches	Normal status post mortem	Natural cardio-respiratory failure
3	24	DBE*, DLC†, clot in internal falx	Normal status post mortem	Natural cardio-respiratory failure
4	30	Fractured thyroid cartilage, mucosal edema of larynx, air in pericardium, DBE*, DLC†	Asphyxia	Strangulation
5	42	DBE*, DLC†, cardiovascular clots	Normal status post mortem	Natural cardio-respiratory failure
6	30	DBE*, DLC†	Normal status post mortem	Natural cardio-respiratory failure
7	22	DBE*, DLC†, air in renal parenchyma	Normal status post mortem	Natural cardio-respiratory failure
8	45	DBE*, DLC†	Normal status post mortem	Natural cardio-respiratory failure
9	75	DBE*, pleural thickening+ left upper lobe, apical segment consolidation, coronary+ aortic calcification, degenerative changes in spine	Pulmonary tuberculosis	Pulmonary tuberculosis
10	49	DBE*, DLC†	Normal status post mortem	Natural cardio-respiratory failure
11	30	DBE*, DLC†, bilateral pleural effusion, multi-segmental collapse/consolidation left lung, air in wall of intestine+ thoracic esophagus+ right atrium	Pulmonary tuberculosis	Pulmonary tuberculosis
12	41	DBE*, DLC†, gas filled bowel loops	Normal status post mortem	Natural cardio-respiratory failure
13	35	Fracture 1st sacral segment, cyst in left liver lobe	Normal status post mortem	Possible trauma
14	65	DBE*, DLC†, coronary/aortic/iliac calcifications	Normal status post mortem	Natural cardio-respiratory failure

*= diffuse brain edema, †= dependent lung congestion, cardiovascular clots -all signifying normal status post mortem

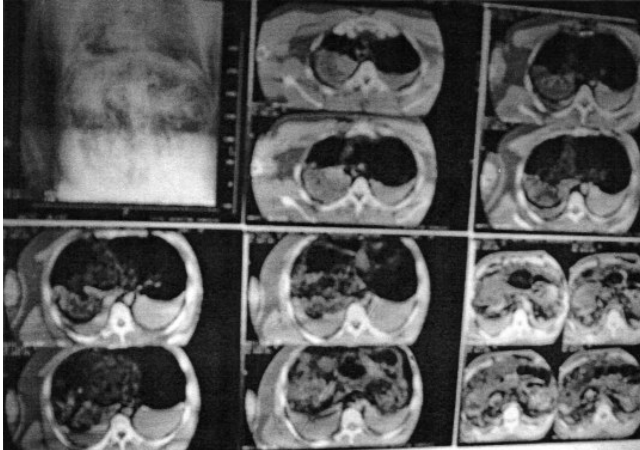


Figure A-C: Postmortem CT scan of a deceased showing soft tissues changes of decomposition along with cardiac thrombi, dependent congestion and fluid in lungs.

spine in 01 case. The autopsy determined natural death in 11 and pulmonary TB in 02 and asphyxia in 01. The percentage agreement between CT and autopsy was 92% ($k=0.92$) and between CT and finalized cause of death was 100% ($k=1.0$).

Discussion

This is the first series from Pakistan reporting the use of CT for post mortem examination and it has shown a very good agreement with conventional autopsy methods. This is besides the superiority in revealing vertebral fractures. Traditionally the local forensic experts usually avail plain radiology services.^{5,6} It is uncommon to employ advanced radiological techniques due mainly to cost and availability limitations.

The studied group comprised of adult male prisoners dying in custody. Death was alleged to be unnatural and PMCT along with traditional autopsy was requested to unravel signs of trauma. However the sign of violent death were visible in only 22% cases.³⁻¹⁴

In two cases, the cause of death was tuberculosis and the rest of the cases had no obvious cause except natural cardio-respiratory failure. A UK based report studying natural deaths in male prisoners also found an increased mortality from respiratory and other infections thus stressing the need for screening and treatment of infectious diseases in the imprisoned.²¹

Only two cases showed fractures of distal spine which were not found in dissection autopsy. In both the cases, spine was not opened. Plain x rays are well known to miss such fractures. Memon et al. utilized CT and radionuclide imaging for detecting equivocal fractures in medico legal cases where the first examining officer's certificate was challenged; they found a markedly superior

diagnostic performance of these advanced modalities in fracture detection over plain x-rays.²² Similar results have been reported in animal models.²³ Even computed radiography has a superior accuracy over film screen radiography in fracture detection by utilizing the effects of edge enhancement and digital image display that improves the observers' performance.²⁴

The PMCT findings in natural deaths all included diffuse cerebral edema, dependent lung congestion, cardiovascular thrombi and intra visceral air which mark the non specific post mortem changes as documented earlier.^{1,10,13,16}

In the single case of strangulation which was originally claimed as that due to suicidal hanging, the claim was ruled out by finding the isolated fracture of the thyroid cartilage without any cervical vertebral fracture. PMCT has proven superiority in identifying atlanto-axial and odontoid fractures particularly when multiplanar reconstruction facilities are available.³

The main limitation of this study was a small sample size and the use of a non helical CT scanner. As for the first, it was due to the local customs that generally discourage the heirs to undertake an autopsy unless compelled by circumstances. Here it was the suspicion of the alleged custodial torture being responsible for death of this relatively younger population that needed to be investigated thoroughly. For the second, the reason was the available technology. Even with that scanner, useful information could be obtained that remained hard copy evidence reproducible in a court of law helping in any later investigation. A recent report has also labeled this approach as 'minimally invasive autopsy' and recommended as a feasible alternative to conventional autopsy.²⁵

The authors strongly recommend that the use of PMCT be employed for investigating high profile unnatural deaths.

Conclusion

PMCT is as effective as dissection autopsy in identifying pulmonary infections and natural causes of death. It is more effective in identifying vertebral fractures which may exclude hanging and corroborate trauma to spine. Natural deaths can be confidently diagnosed in the absence of abnormal findings.

References

1. Thali MJ, Yen K, Schweitzer W, Vock P, Boesch C, Ozdoba C, et al. Virtopsy, a new imaging horizon in forensic pathology: virtual autopsy by post mortem multislice computed tomography (MSCCT) and magnetic resonance imaging (MRI)-a feasibility study. *J Forensic Sci* 2003; 48: 386-403
2. Levy AD, Härke HT, Getz JM, Mallack CT, Caruso JL, Pearse L, et al. Virtual autopsy: two- and three- dimensional multidetector CT findings in drowning with autopsy comparison. *Radiology* 2007; 243: 862-8.

3. Yen K, Sonnenschein M, Thali MJ, Ozdoba C, Weis J, Zwygart K, et al. Postmortem multislice computed tomography and magnetic resonance imaging of odontoid fractures, atlantoaxial distractions and ascending medullary edema. *Int J Legal Med* 2005; 119: 129-36.
4. Grosse AB, Grosse CA, Steinbach LS, Zimmermann H, Anderson S. Imaging findings of avalanche victims. *Skeletal Radiol* 2007; 36: 515-21.
5. Bertram K. In: A textbook of forensic medicine and toxicology. Betram K edit. Churchill Livingstone, London 2005; pp 5.
6. Alker GJ, Oh YS, Leslie EV, Lehotay J, Panaro VA, Escner EG. Postmortem radiology of head and neck injuries in fatal traffic accidents. *Radiology* 1975; 114: 611-7.
7. Alker GJ Jr, Oh YS, Leslie EV. High cervical spine and craniocervical junction injuries in fatal traffic accidents: a radiological study. *Orthop Clin North Am* 1978; 9: 1003-10.
8. Shkrum MJ, Green RN, Nowak ES. Upper cervical trauma in motor vehicle collisions. *J Forensic Sci* 1989; 34: 381-90.
9. Ehara S, el-Khoury GY, Clark CR. Radiologic evaluation of dens fractures. Role of plain radiography and tomography. *Spine* 1992; 17: 475-9.
10. Oyake Y, Aoki T, Shiotani S, Kohno M, Ohashi N, Akutsu H, Yamazaki K. Postmortem computed tomography for detecting causes of sudden death in infants and children; retrospective review of cases. *Radiat Med* 2006; 24: 493-502.
11. Arai A, Shiotani S, Yamazaki K, Nagata C, Kikuchi K, Suzuki M et al. Postmortem computed tomographic (PMCT) and postmortem magnetic resonance imaging (PMMRI) demonstration of fatal massive retroperitoneal hemorrhage caused by abdominal aortic aneurysm (AAA) rupture. *Radiat Med* 2006; 24: 147-9.
12. Quesnel C, Fulgencio JP, Adrie C, Marro B, Payen L, Lember N, et al. Limitations of computed tomographic angiography in the diagnosis of brain death. *Intensive care Med* 2007; 33: 2129-35.
13. Hayakawa M, Yamamoto S, Motani H, Yajima D, Sato Y, Iwase H. Does imaging technology overcome problems of conventional postmortem examination? A trial of computed tomography imaging for postmortem examination. *Int J Legal Med* 2006; 120: 24-6.
14. Couto OF, Dvorchik I, Carr BI. Causes of death with unresectable hepatocellular carcinoma. *Dig Dis Sci* 2007; 52: 3285-9.
15. Hamano J, Shiotani S, Yamazaki K, Suzuki M, Ishikawa H. Postmortem computed tomography (PMCT) demonstration of fatal hemoptysis by pulmonary tuberculosis-radiological-pathological correlation in a case of rupture of Rasmussen's aneurysm. *Radiat Med* 2004; 22: 120-2.
16. Levy G, Goldstein L, Blacher A, Apter S, Barenboim E, Bar-Dayyan Y, et al. Postmortem computed tomography in victims of military air mishaps: radiological-pathological correlation of CT findings. *Isr Med Assoc J* 2007; 9: 699-702.
17. Cole AJ, Griffiths D, Lavender MS, Summers P, Rich K. Relevance of postmortem radiology to the diagnosis of fatal cerebral gas embolism from compressed air diving. *J Clin Pathol* 2006; 59: 489-91.
18. Luqman M, Sattar A, Abbasi S, Satti TM. Pattern of sudden deaths in Armed Forces Personnel-Postmortem Study. *Pak Armed Forces Med J* 1995; 45: 66-71.
19. Sahito MM, Mughal MI, Chang F, Shah SMH, Pirzada SG, Jamali YA, et al. Causes of death in interior Sindh - A medicolegal autopsies study. *Pak Postgrad Med J* 2002; 13: 161-4.
20. Mirza F, Makhdoom P. Importance of correct interpretation of postmortem artifacts in medicolegal autopsies. *J Pak Med Assoc* 1998; 48: 49-50.
21. Fazel S, Benning R. Natural deaths in male prisoners: a 20-year mortality study. *Eur J Public Health* 2006; 16: 441-4.
22. Memon A, Memon U, Siddiqui KA, Yousfani M, Afzal A, Khalil IR. The role of radionuclide imaging and computerized axial tomography to reveal equivocal fractures in medicolegal practice. *Biomedica* 2002; 18: 58-61.
23. Cattenneo C, Marinelli E, Di Giancamillo A, Di Giancamillo M, Travetti O, Viganò L, et al. Sensitivity of autopsy and radiological examination in detecting bone fractures in an animal model: implications for the assessment of fatal child physical abuse. *Forensic Sci Int* 2006; 164: 131-7.
24. Offiah AC, Moon L, Hall CM, Todd-Pokropek A. Diagnostic accuracy of fracture detection in suspected non-accidental injury: the effect of edge enhancement and digital display on observer performance. *Clin Radiol* 2006; 61: 163-73.
25. Weustink AC, Hunik MG, Van dijke CF, Renken NS, Krestin GP, Oosterhui JW. Minimally invasive autopsy; an alternate to conventional autopsy. *Radiology* 2009; 250: 897-904.