

Case Report

Acute mesenteric, Portal and Inferior Vena Cava (IVC) venous thrombosis: Optimal outcome achieved with anticoagulation

Abdul Rehman Alvi, Shahida Bibi, Zia ur Rehman, Sameullah Khan Niazi
Department of Surgery, Aga Khan University Hospital, Karachi.

Abstract

The prevalence and clinical spectrum of acute mesenteric venous thrombosis (AMVT) in Pakistan is largely unknown. The authors report two patients with acute mesenteric, portal and inferior vena cava venous thrombosis confirmed on CT imaging. The diagnoses were established within 24 hours of presentation and both patients were successfully treated with therapeutic heparin during hospital admission and continued on oral warfarin because of hypercoagulable state. The protocol that we currently use is evidence based and is leading to optimal outcome.

Introduction

Acute mesenteric Venous thrombosis (AMVT) is an uncommon but potentially life threatening type of acute mesenteric ischaemia but fortunately comprises 5-15% of all causes.^{1,2} In 1895 Elliott first described the phenomenon of acute mesenteric venous thrombosis and subsequently Abu et

al identified 375 cases of AMVT in international literature since 1911-1984.² In 22 years 72 cases were reported from Mayo clinic (1972-1993) and this comprises 6.2% of all cases of mesenteric ischaemia. The literature reported various aspects of AMVT including probable etiology, presentation, diagnostic modalities and therapeutics.^{2,3} The diagnosis of MVT remained a serious challenge to the clinicians and was often diagnosed on laparotomy with mortality of more than 34%.⁴ Advancement in radiological imaging like the CT scan have enabled the early detection of the disease and opened new avenues in its management.^{3,4} Early diagnosis and better understanding of the disease process have enabled the clinicians to avert the consequences of AMVT by appropriate anticoagulation and opened the door for non-operative management.³

Case Report

The first case was of a 30 year old female who

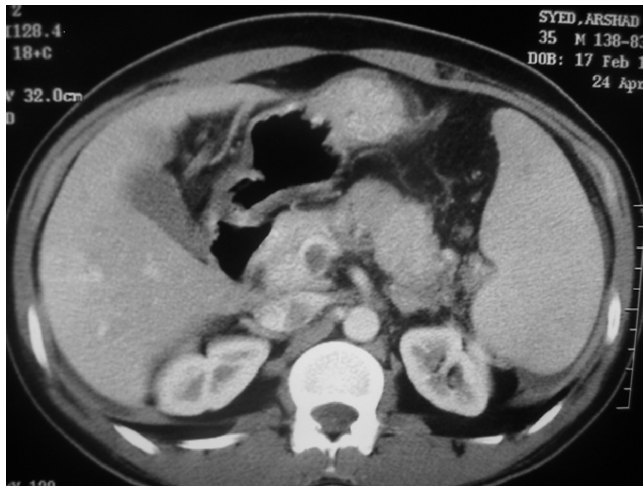


Figure:

presented to the emergency room with complaints of central abdominal pain, nausea and vomiting of 10 days duration. The past history was unremarkable and there was no history of oral or injectable contraceptives. She looked dehydrated but was stable haemodynamically with heart rate of 100/minute, blood pressure of 120/80 mmHg and normal core temperature. Abdomen was distended and tender on deep palpation all over with increased tenderness in right lower quadrant. However, no signs of peritonitis were present. The initial laboratory investigation showed haemoglobin of 11.8 gm/dl (normal range: 11.1-14.5) with haematocrit of 35% (normal range: 35.4-42 %), white cell count of 9.4 (normal range: 4.0-10) $\times 10^9/L$ with 74.6% neutrophils and platelet count of 426 (150-400) $\times 10^9/L$. Her serum amylase, electrolytes, liver function tests, arterial blood gas analysis and coagulation profiles were within normal limits. Plain abdominal X-rays and ultra-sonography were normal. Double contrast CT scan abdomen was done to explain the out of proportion severe abdominal pain. CT scan findings were suggestive of small bowel ischaemia secondary to extensive thrombosis involving the entire superior mesenteric vein, portal vein and partial thrombosis of inferior vena cava was also demonstrated.

After initial fluid resuscitation, she was started on therapeutic intravenous heparin therapy, with an initial bolus of 10000 units followed by heparin infusion. The heparin infusion was titrated to maintain the I.N.R in the range of 2.5 to 3 ratios. She was monitored closely in the high dependent unit and responded very well to anticoagulation therapy, with a decrease in the intensity of abdominal pain and tenderness. Patient was started on oral anti coagulant (Tab.Warfarin) on third day of admission when she was tolerating oral diet. She was discharged on 8th day of admission on therapeutic oral anti coagulant and advised to regularly monitor the Prothrombin Time (PT)

and to keep INR in therapeutic range (2.5-3 ratio).

The serum anticoagulant factors profile was available and showed protein-C of 60% (72-106); protein- S of 5% (65-110), antithrombin III of 94% (80-120) and factor V Leiden of 2.5% (1.75-2.80). On 6 months follow up she remained asymptomatic, continued on oral warfarin, INR was kept at 3 ratio. Patient was advised to continue life long anticoagulant therapy.

The second patient was a 40 year old male who was in his usual state of health until one week back when he developed generalized abdominal pain, which gradually increased in intensity and was associated with anorexia and nausea. His past medical history was significant for deep venous thrombosis of the left leg 18 months back and he was on oral warfarin for a period 6 months prior to the current condition. On clinical examination in the emergency room he was found to be in severe abdominal pain but vital signs were within normal limits. His abdomen was distended and tender all over on deep palpation, however, no signs of peritonitis were present. The initial laboratory investigation showed haemoglobin of 12.8 gm/dl (normal range: 13.7-16.3) with haematocrit of 37.7% (41.9-48.7), white cell count of 8.1 (normal range: 4.0-10) $\times 10^9/L$ with neutrophils of 84%. His serum electrolytes, liver function tests, serum amylase, lipase and arterial blood gas analysis were within normal limits. Abdominal ultrasonography and plain X-rays were normal. The double contrast CT scan of the abdomen revealed thrombosis of superior mesenteric vein, extensive thrombosis of portal vein, thrombus in Inferior Vena Cava (IVC), mild ascites and thickened oedematous colon.

Patient was started on therapeutic intravenous heparin infusion and was monitored closely in high dependent unit with serial APTT and INR to keep these parameters within the therapeutic range. He responded very well on anti coagulant therapy, with decreased abdominal pain and tenderness. The serum anticoagulant factors results were available and showed protein-S of 10% (normal range: 65-110), protein-C of 56% (normal range: 72-106), anti thrombin III 89% (normal range: 80-120), factor V Leiden of 2.02 (normal range: 1.75-2.80), anticardiolipin IGG of 1.5, anticardiolipin IGM of 1.9 and serum homocystein of 15.71 H (normal range: 4.45-12.42).

Patient was discharged on oral warfarin with the advice to continue the drug life long. He remained asymptomatic on 18 months follow up with no evidence of recurrent, portal hypertension or bowel stricture.

Discussion

Acute mesenteric venous thrombosis is an uncommon cause of mesenteric ischaemia with mortality rate of 34-40% in early 1990.⁴ The high mortality was contributed to delay in diagnosis established on exploratory laparotomy. These

patients did not receive peri-operative anticoagulation therapy. Improved understanding of disease process and availability of CT scan changed the management of AMVT with increased emphasis on early anticoagulation therapy and the desired results were achieved in 15 patients with no mortality.⁵ A study from China reported 44 patients with AMVT which were divided into operative and non operative group. The results showed 39 % mortality in operated and 11% in non operated group. The authors proposed early anticoagulation therapy to achieve the best outcome in AMVT.⁶ A study from India in 32 patients with AMVT further consolidated the preference of early anticoagulation in all patients and surgical treatment in cases of peritonitis achieved low mortality.⁷ A retrospective review of 57 patients showed optimal outcome with early diagnosis on CT scan and prompt anticoagulation therapy.⁸ The operative intervention was required only in clinical and radiological signs of bowel infarction and the study did not uphold the mandatory second look laparotomy.

This case series and other reports^{10,11} show that the number of patients with primary AMVT continues to decrease with increased facilities to recognize hypercoagulable state. An apparent increase of AMVT as we have experienced over the past 7 years may be due to improved radiological imaging like 64-sliced CT scan with high resolution angiography facilities and this is also experienced by other centers.⁶⁻⁸

With high index of clinical suspicion in patients with abdominal pain and liberal use of CT scanning, enabled us to confirm the diagnosis of AMVT. Reports suggest that early anticoagulant therapy improves outcome in both medical and surgical treated patients.⁶⁻⁹ Both of the patients were investigated for hypercoagulable state and were found to have protein C and S deficiencies. There are reports of 60-70% secondary AMVT and there is a suggestion to continue lifelong anticoagulation therapy and hence avoid recurrence of the disease.^{10,11}

Our case series shows that non-operative therapy is an option when the diagnosis is confirmed on CT imaging and when the patient does not have peritonitis. Bowel ischaemia

due to AMVT is a reversible process with early anticoagulant therapy.⁶⁻⁸ Prompt diagnosis has allowed us to manage the patients non-operatively with optimal outcome, no mortality and shorter hospital stay. With the protocol to continue oral anticoagulant (Tab. Warfarin) for lifelong in secondary AMVT has proven to be effective with no recurrence on follow up.

Conclusion

In conclusion, acute mesenteric venous thrombosis must be kept in mind as a possible diagnosis with abdominal pain out of proportion to physical findings. Early CT imaging allows for immediate anticoagulation and seems to improve outcome. Patients with AMVT should be screened for hypercoagulable state and patients with secondary AMVT should be on life long anticoagulant treatment to prevent recurrence.

References

1. Rhee RY, Gloviczki P. Mesenteric venous thrombosis. *Surg Clin North Am* 1997; 77: 327-37.
2. McKinsey JF, Gewertz BL. Acute mesenteric ischemia. *Surg Clin North Am* 1997; 77: 307-17.
3. Kumar S, Sarr MG, Kamath PS. Mesenteric Venous Thrombosis. *N Engl J Med* 2001; 345: 1683-8.
4. Rhee RY, Gloviczki P, Mendonca CT, Petterson TM, Serry RD, Sarr MG, et al. Mesenteric venous thrombosis: still a lethal disease in the 1990s. *J Vasc Surg* 1994; 20: 688-97.
5. Joh JH, Kim DI. Mesenteric and portal vein thrombosis: treated with early initiation of anticoagulation. *Eur J Vasc Endovasc Surg* 2005; 29: 204-8.
6. Zhang J, Duan ZQ, Sang Q, Luo YW, Xin SJ. Acute mesenteric venous thrombosis: A better outcome achieved through improved imaging and a changed policy of clinical management. *Eur J Vasc Endovasc Surg* 2004; 28: 329-34. [ISSN 1078-S884]
7. Amarapurkar DN, Patel ND, Jatania J. Primary mesenteric venous thrombosis: a study from western India. *Indian J Gastro Enterol* 2007; 26: 113-7.
8. Salamah SMA, Mirza SM. Acute mesenteric venous thrombosis: Management controversies. *JK Practitioner* 2004; 11: 242-7.
9. Morasch MD, Ebaugh JL, Chiou AC, Matsumura JS, Pearce WH, Yao JS. Mesenteric venous thrombosis; a changing clinical entity. *J Vas Surg* 2001; 34: 680-4.
10. Hilaly MAA, Zidan FMA. Mesenteric vein thrombosis: Is it one disease? *Eur J Vasc Endovasc Surg* 1995; 9: 103-6.
11. Agaoglu N, Turkyilmaz S, Ovali E, Ucar F, Agaoglu C et al. Prevalence of prothrotic abnormalities in patients with acute mesenteric ischemia. *World J Surg* 2005; 29: 1135-8. [ISSN 0364-2313]