

View Box Case - 7

I. Masroor,R. Hashmi (Radiology Department, Aga Khan University Hospital, Karachi.)

A 15 year old boy presented with severe pain and swelling of left knee following a fall from second floor. Xray examination of left knee showed fracture of epiphysial plate of left femur with a chip of metaphysis and posterior and lateral displacement of epiphysis (Figure 1, 2).

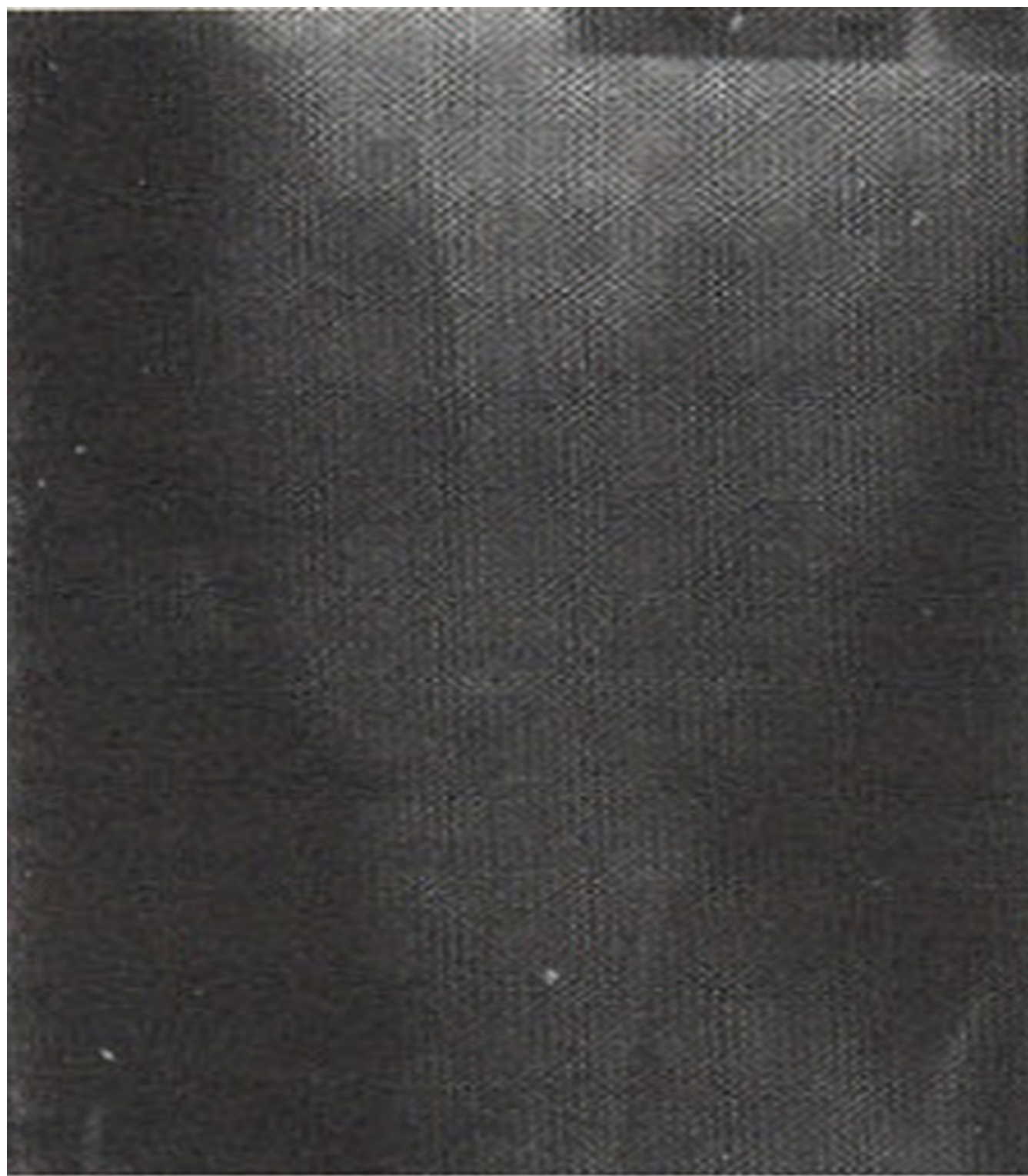

Figure 1. AP view of left Knee.

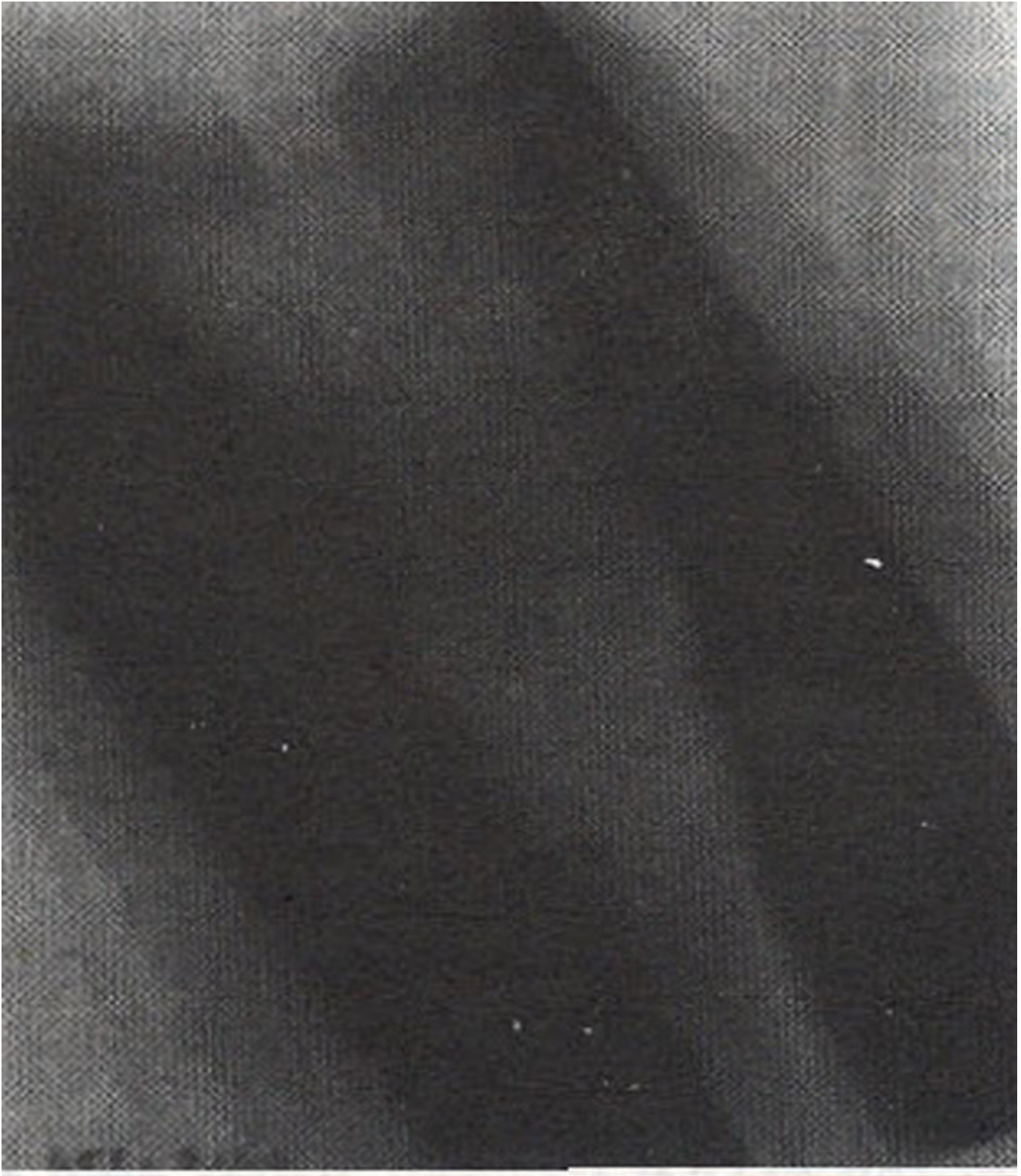


Figure 2. Lateral view of left Knee.

Diagnosis: Salter-Harris Type-II fracture.

Discussion

Because of the unique anatomy and physiology associated with the growth plate complex, an injury to the juxtaarticular region in a child has a significantly different diagnostic and prognostic implication than would a similar trauma in an adult. Injuries to the growth plate are present in almost one sixth of all childhood fractures. As would be expected, as the child becomes more mobile and athletic the incidence of this type of injury will increase and the more violent life led by most boys will be reflected in a relatively increased number of these injuries in males.

Initial examination should have at least two radiographic projections, preferably oriented at right angles to each other. Although cartilage is not distinct from other soft tissues on plain films, the fat planes are usually well identified in children and can often be used to define capsular and cartilage boundaries. Comparison films of the opposite side should be confined to situations in which the diagnosis is not clear, most commonly when the anatomical area is complex or normal variants are frequent. If minimal growth plate widening or epiphysis shift is suspected, a comparison film of the opposite side may be quite helpful, but the routine use of such in all clinical situations is of doubtful utility.

Many classifications of growth plate injury have been formulated. That described by Salter and Harris¹ is most commonly used clinically. (Figure 3).

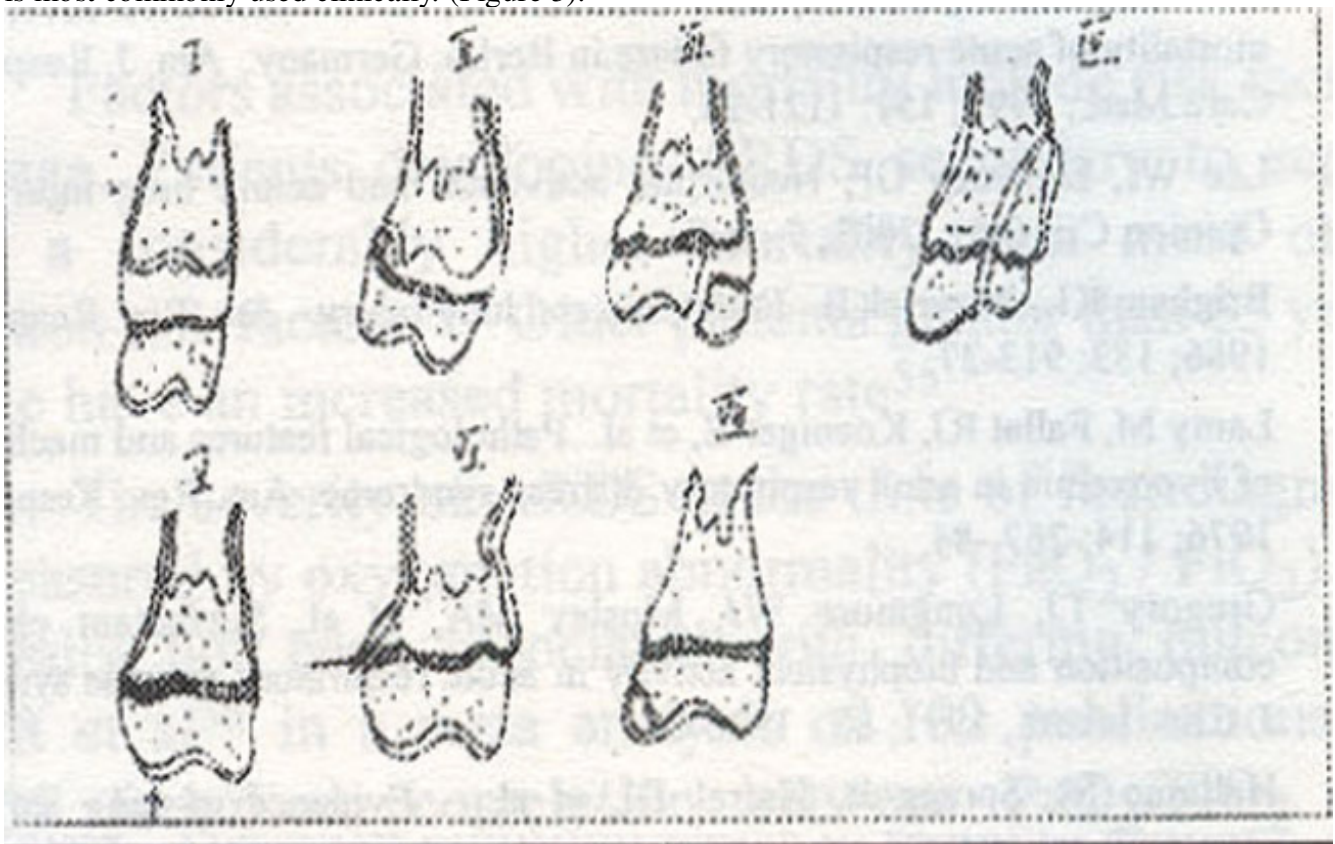


Figure 3. Line diagram showing Salter-Harris classification of epiphysal fractures.

Type I fractures involve the growth plate only, without visible fracture line in either epiphysis or metaphysis. These injuries comprise about 6% of all growth plate injuries and are usually encountered in younger children, except in the proximal humerus and proximal femur, where the preadolescent child is more commonly affected.

The prognosis for full recovery after a type I slip is quite good because only the growth plate is affected. It should be noted, however, that if anatomical reduction is not accomplished, resumption of growth in a displaced position will soon take place and malalignment may follow.

A Type II injury is by far the most commonly seen, occurring in one half to three quarters of all growth plate injuries. It is most common in the prepubertal child and adolescent, involving the distal radius,

distal tibia, and distal fibula, in that order. It involves the growth plate and metaphysis. A prominent metaphyseal corner fragment displaced to the same degree as the epiphysis, is the hallmark of this injury. Again, the prognosis for complete restoration of function is quite good.

Type III injuries are slightly more common than type I. They usually occur in older children in whom a portion of the growth plate has fused. The sharing force passes through the nominated portion of the growth plate and then deviates at a right angle to the growth plate while passing through the epiphysis. The distal and proximal tibia are the most common sites of involvement. In comparison with types II, and I the prognosis in type III injury is not as good.

Type IV injuries comprise about 10% of all trauma to the growth complex. The distal humerus and distal tibia are the areas most commonly involved. The growth plate, metaphysis and epiphysis are all affected. The prognosis in this type of injury is quite guarded. Even with complete reduction of the fracture fragment, the violence done to the functional area of the growth plate may be sufficient that no further growth will take place in this area. Early diagnosis and treatment of growth disturbance can prevent severe deformity².

Type V fracture is quite uncommon, being seen in fewer than 1% of growth complex injuries involves only a crush of the growth plate without visible fracture line. The diagnosis cannot be made with certainty initially. Most of these injuries take place at the knee or ankle.

Type VI injuries are extremely uncommon. Injury to the perichondrium peripheral to the growth may occur as a result of direct trauma, adjacent soft-tissue infection, or thermal injury. The trauma acts as a stimulus to bone formation in the perichondrium.

In type VII injury, only the epiphysis is affected and not the growth plate itself, if the fracture line involves only cartilage, detection by routine radiography is impossible without arthrography or MRI. MR imaging detects abnormalities in the cartilage that are associated with growth disturbances and provides accurate mapping of physeal injuries³. If the fracture line passes through a portion of the ossified epiphysis, however, it will be detected as a bone fragment separated from the main body of the ossification center. If some time has passed after the injury, resumption of this fragment may occur and the only evidence of the trauma will be a small defect in the ossification center. Many of the transchondral injuries included in type VII are known characteristically by synonyms or eponyms, these include osteochondritis dissecans, Osgood-Schlatter disease etc.

In the immediate evaluation of all growth plate complex trauma, the aim of initial diagnosis should be to classify the lesion as appropriately as possible, because this will influence both initial treatment and subsequent prognosis.

Although appropriate treatment can prevent or ameliorate most of the complications resulting from injury to the growth plate, some are inevitable, given the violence applied to this zone. Late complications include decreased growth rate, cessation of growth, ischemic necrosis etc.

References

1. Brown JH, Deluca SA. Growth plate injuries: Salter-Harris classification. *Am. Fam. Physician.* 1992; 46:1180-84.
2. Berson L, Davidson RS, Dormans JP, Growth disturbances after distal tibial physeal fractures. *Foot Ankle Int.*, 2000; 21:54.8.
3. Jaramillo D, Hoffer FA, Shapiro F. MR imaging of fractures of growth plate. *AJR.* 1990; 155: 1261-65.