

Endovascular approach as primary treatment for traumatic carotid cavernous fistula: local experience from Pakistan

Rana Shoaib Hamid,¹ Tanveer-ul-Haq,² Muhammad Shahzad Shamim,³ Syed Faraz Kazim,⁴ Basit Salam⁵

Departments of Radiology,^{1,2,5} Department of Neurosurgery,^{3,4} Aga Khan University Hospital, Karachi, Pakistan.

Abstract

Objective: To evaluate the technical success, complications and outcome of endovascular management of post traumatic carotid cavernous fistula (CCF) in patients presenting at a tertiary care hospital in Karachi.

Methods: Descriptive case series of 26 patients of post traumatic CCF treated by endovascular techniques was carried out at Radiology and Neurosurgery departments of Aga Khan University hospital between January 2010 to March 2010. Medical records and radiology reports were retrospectively reviewed from November 2000 to December 2009. The diagnosis was primarily clinical and was confirmed in all cases by CT or MRI. Endovascular procedures were performed under general anaesthesia through femoral artery or femoral vein approach. Detachable balloons pushable coils and/or glue was used for fistula closure. Follow up was done via medical records and on phone. Technical success and safety of the procedure were analyzed and outcome in terms of symptomatic improvement was recorded wherever available.

Results: Out of a total of 26 patients; 20 were male and 6 were female, with age range of 14 to 62 years, mean age 31.4 ± 12.6 years. Technical success rate of endovascular embolization was 92.3 % (24 out of 26 patients). Procedure could not be performed in 2 patients. In 20 out of 24 patients (83.3%) single session of embolization was performed while 4 patients required 2 sessions due to recurrence. In one of these patients the detachable balloon deflated after 2 hours of deployment and another session of embolization was immediately carried out by deploying a larger sized balloon. Complication rate was 15.3% (n=4) one patient had infarction which recovered completely in 6 months. There was no procedure related mortality. Five patients were lost to follow up. In rest of the 19 patients follow up ranged from 1 to 14 months (Mean 11.0 ± 11.8 months) 8 out of 19 (42.1%) patients showed complete resolution of symptoms and 9 (47.3%) reported improvement.

Conclusion: Endovascular approach is a safe and useful option for treatment of traumatic carotid cavernous fistula.

Keywords: Carotid-cavernous sinus fistula, Carotid artery, Endovascular, Traumatic (JPMA 61:989; 2011).

Introduction

Post traumatic Carotid cavernous fistula (CCF) is a rare complication of moderate to severe head injury in which an abnormal communication develops between internal carotid artery (ICA) and the cavernous sinus. Exact

mechanism of formation of these fistulae has not been clearly understood however it is believed that direct injury at skull base results in torsion and or stretching of carotid siphon. The other possible explanation is impingement of vessels upon nearby bony prominences.¹ Complete disruption of the wall

of the ICA results in direct transmission of highly pressurized arterial blood to the cavernous sinus and ophthalmic veins, leading to venous hypertension.²

Typically, patients with CCF present with ophthalmological abnormalities, and common symptoms include orbital swelling, exophthalmos and visual disturbances. Less commonly cranial nerve palsies and steal phenomena are also seen. Symptoms often occur days or weeks after a head injury.³ If untreated they may lead to significant morbidity resulting in visual loss in upto 90% patients. Based on angiographic findings and flow velocity through the shunts, the fistulae are classified into four types by Barrow.⁴

Surgical treatment although feasible and successful, is often not possible because of anatomical complexity of the region, moreover it is extensive, invasive and carries considerable risks even in the best hands.⁵ Modern neuroradiological techniques have made the therapeutic goals of obliteration of the fistula with preservation of internal carotid artery patency possible in most cases.¹ With improvement in imaging techniques and radiological equipment, especially advent of coils, detachable balloons, and liquid embolic agents, the endovascular closure has now become first line of treatment.^{6,7}

Although the international literature is replete with papers on the role of endovascular closure of CCF, there is no local data from Pakistan in terms of clinical presentation, procedural results and clinical outcome of the procedure. This study was carried out to present the details of our initial experience with the procedure at a tertiary care hospital, in an attempt to evaluate the technical success, complications and outcome of endovascular management of CCF in post traumatic patients. To the best of our knowledge, this will be the first such report from Pakistan.

Patients and Methods

This descriptive case series was carried out at Radiology and Neurosurgery departments of Aga Khan University hospital between January 2010 to March 2010. Medical records and images of those 26 patients were retrospectively reviewed who underwent endovascular treatment for carotid cavernous fistulas between November 2000 to December 2009 at our vascular intervention suite.

All procedures were performed by senior interventional radiologist in angiography suite on a monoplane flat panel DSA unit (Axiom Artis angiography machine Seimen's corporation). Procedures were carried out under general anaesthesia via femoral artery approach in most patients. Venous approach was also adopted if required due to technical difficulty from arterial side. Initially diagnostic cerebral angiography was carried out in all patients

using a 5 Fr headhunter catheter (Cordis Corporation) to define the vascular anatomy, site of fistula and status of collateral circulation. A 6 Fr guiding catheter (MPD, Cordis corporation) was placed in internal carotid artery close to the fistula and the fistula was tried to cross with a micro-catheter (Minitorque KTC 150 Minvasys) mounted with a detachable balloon (GoldValve, CathNet-Science, Paris, France) once the fistula was successfully crossed, the balloon was inflated in cavernous sinus and fistula was closed (Figure-1). If this failed, venous access was made and the cavernous sinus was cannulated with microcatheter from either the inferior petrosal sinus route or through angular / ophthalmic vein and embolization was done by using pushable platinum coils (Figure-2) and/or cyanoacrylate glue. In few patients where it was not possible to cross the fistula site or access cavernous sinus directly due to difficult anatomy and with an available good collateral flow via circle of Willis, the detachable balloon was inflated in distal segment of internal carotid artery of the affected side.

Procedural success was defined as complete closure of fistula, or near complete closure with very minimal residual fistula flow that was likely to undergo spontaneous thrombosis. Failure was defined as incomplete fistula occlusion with the presence of a residual shunt. Post procedure, patients were monitored in a special care unit and serial neurological examinations were carried out. Once clinical condition was stable, patients were discharged, to be followed as outpatient, where if required, angiographic examination and subsequent intervention procedures were also carried out.

For the purpose of this review, clinical records and radiology data was retrieved from medical records, various clinical as well as technical details were recorded on a standardized pre tested proforma. Technical success and safety of the procedure were analyzed and the final outcome, which was described in terms of symptomatic improvement, was recorded wherever available. The outcome was categorized as (a) complete resolution of symptoms (b) improvement and (c) no change. Subjective follow up was also obtained on telephone where the patient failed to follow up personally.

Data from patient's files and radiology reports was collected on performa and analyzed on SPSS version 16. Frequencies and percentages were calculated.

Results

Out of total 26 patients 20 were males and 6 females (age range from 14 to 62 years, mean age 31.4 ± 12.6 years). All patients presented with clinical features of raised ocular pressure and /or cranial nerve dysfunction and initial diagnosis was made on clinical grounds. Final diagnosis was made by CT, MRI or both and on the basis of digital

Table: Procedural complications and embolic agents used for closure of fistula.

Complications	Number	Percentage
Total	04	15.3
Ischaemic infarction	01	3.8
Cranial nerve palsy	02	7.6
Infective endophthalmitis	01	3.8

Embolic material	Number	Percentage
Detachable balloons only	13	54.1
Detachable balloons and pushable coils	06	25
Pushable Coils only	03	12.5
Pushable coils and cyanoacrylate glue	02	8.3

Total procedures: n = 26
Successful procedures : n = 24

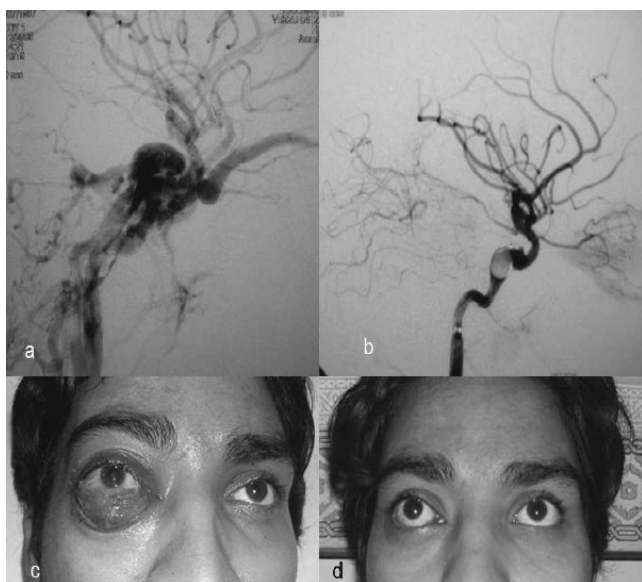


Figure-1: Right internal carotid angiogram (a) demonstrates filling of cavernous sinus and superior ophthalmic vein. Flow in the ICA branches is reduced due to steal phenomenon. Detachable balloon deployed in cavernous sinus, on post embolization angiogram (b) there is no venous filling while good flow can now be seen in ICA branches. (c) Orbital congestion and swelling at presentation. (d) Marked symptomatic resolution on follow up 2 weeks after embolization.

subtraction angiography (DSA). Twenty three (88.4%) patients had direct fistula and three patients had indirect fistula. Technical success rate of endovascular embolization was 92.3% (24 of 26 procedures). In 2 patients, the embolization procedure was unsuccessful and could not be performed. In 19 patients, the procedure was carried out by arterial approach and in five patients, venous approach was adopted. In 19 patients detachable balloons were used for fistula closure (Table). In 17 (70.8%) patients the exact fistula site was successfully crossed and the embolic agent was deployed in cavernous sinus while in remaining seven (29.1%) patients the fistula could not be crossed and hence balloons or coils were deployed in the cavernous part of

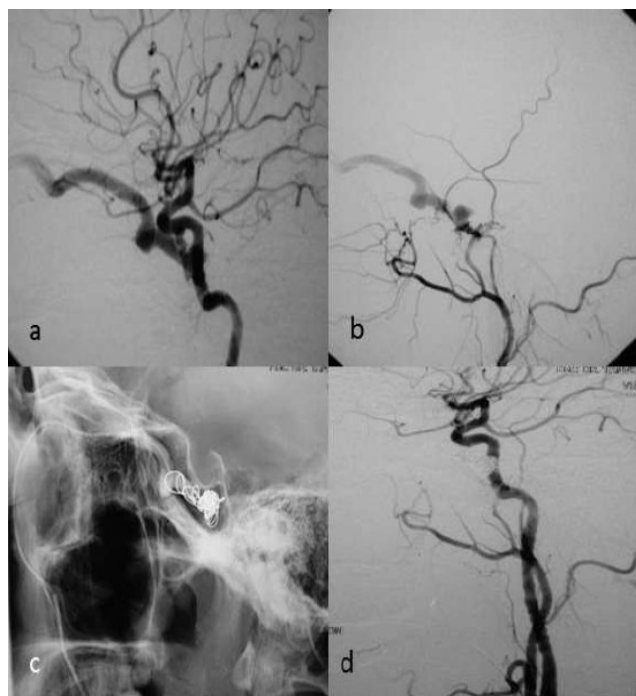


Figure-2: Right internal carotid angiogram (a) demonstrates simultaneous filling of cavernous sinus and superior ophthalmic vein. The fistula is also filling from branches of external carotid artery (b). Multiple coils and glue deployed in cavernous sinus from venous approach, note microcatheter in angular and ophthalmic veins (c). No residual venous filling in post embolization angiogram (d).

ipsilateral internal carotid artery.

In 20 out of 24 (83.3%) patients single session of embolization was sufficient while four patients required another session due to recurrence. In one of these four patients the detachable balloon deflated after 2 hours of deployment and another session of embolization was immediately carried out by deploying a larger sized balloon. Rest of the three patients underwent a repeat session after interval ranging from one week to 7 months.

Complication rate was 15.3 % (n=4) (Table 1). Most severe complication was a transient motor aphasia and hemiparesis in one patient, who had recovered completely at six months follow up. There was no procedure related mortality. Five patients were lost to follow up. In rest of the patients follow up ranged from one to 14 months, with a mean follow up duration of 11 ± 11.8 months. Of the available follow up of 19 patients, eight (42.1%) reported complete resolution of symptoms, nine (47.3%) reported some improvement while two patients reported no significant symptomatic improvement.

Discussion

The estimated incidence of traumatic brain injury (TBI) in Pakistan is 81 per 100,000 with a mortality rate of 15 percent.^{8,9} Approximately 0.2 % of these TBI patients may end up with a CCF. Clinical symptoms of CCF are related to

increased venous pressures and are related to duration since trauma, fistula size, location, arterial anatomy and status of collateral vessels and the adequacy and route of venous drainage. Hallbach et al.¹⁰ has identified potential risk factors of CCF, which may lead to acute deterioration in clinical condition. These include increased intraocular pressure, decreased visual acuity, rapidly progressive proptosis, cerebral ischaemia and haemorrhages. Blindness was seen in 3.1% patients in their series and mortality in 3.9% patients. Based on this study they recommended urgent therapy for cases manifesting high risk features. Before the era of endovascular treatment, various surgical techniques were employed to treat these lesions. Craniotomy or transthemoidal transsphenoidal approach was adopted to access and directly repair cavernous sinus.^{11,12} The surgical approach is complex with variable outcomes and high morbidity, even in the best of centres. Endovascular approach on the other hand has gained popularity, especially in the last decade. Advent of road mapping capability on DSA machines and increasing experience of interventional radiologists with microcatheter techniques has made the endovascular treatment now a method of choice.

The objective of endovascular treatment is to completely occlude the abnormal arterio-venous connections preferably sparing the patency of the internal carotid artery.¹³ However in some cases if the fistula is large and cannot be obliterated, the ICA must be occluded.

The traditional approach has been embolizing the fistula from arterial approach however, in some cases due to multiple arterial feeders transvenous embolization is also adopted and cavernous sinus is directly occluded via inferior petrosal sinus approach. Use of detachable balloons had been standard treatment in the past but some technical difficulties were encountered which included difficulty in negotiating the balloon through defect in the artery, early detachment, deflation, or rupture of the balloon and problems with the balloon valve mechanism therefore other embolic agents like detachable coils, n-Butyl Cyanoacrylate glue and ethylene-vinyl alcohol copolymer (Onyx) are now becoming mainstay of endovascular treatment.^{14,15}

The technical success rate in our series was 92.3% which is comparable to reported literature.^{17,18} Serious complications in our series were infrequent. One patient in our series who developed aphasia and hemiparesis due to ischaemic infarction but recovered after 6 months. Similar complications have been described by other interventionalists¹⁹ with reported improvement over period of few months. Recurrence of fistula was is not an infrequent clinical problem^{19,20} and such patients may require another session of embolization. Four patients in our series had recurrence and were successfully treated by second session of embolization.

Follow up was available in 19 patients and 17 out of these 19 reported either complete resolution or significant improvement. This cure rate of 89.4% is also comparable to reported cure rates of 88-99% by various authors.¹

The authors would like to mention a few limitations of our study. First, being a retrospective review, the study has inherent deficiencies, especially while recording the fine technical details of procedure and clinical examination of patients at presentation as well as at follow ups. Secondly, clinical follow ups were not available for seven patients (26.9%) despite our best efforts at contacting them. Since it is only our initial experience, the number of cases is also small as compared to the series reported from more experienced centers. Lastly, the outcome measure was based on a subjective criteria and follow up angiograms were not acquired in cases where it was not clinically indicated. Despite these limitations, this remains the first reported series of CCF embolization from Pakistan and in our opinion would serve as a baseline for monitoring further regional progress. Larger prospective studies are nevertheless recommended for even better evaluation and more detailed analysis of determinants of complications and outcome.

Conclusion

Endovascular approach is a safe and useful option for treatment of traumatic carotid cavernous fistula. A collaborative approach among clinicians and interventional neuroradiologist is needed in order to offer timely treatment and ensure good outcome.

References

1. Bhatti AA, Raza SS, Bari E, Enam SA, Haq TU, Sajjad Z. Traumatic Carotid-cavernous fistula: Clinical presentation and outcome. *Pak J Neurol Sci* 2007; 2: 213-6.
2. Gemmette JJ, Ansari SA, Gandhi DM. Endovascular techniques for treatment of carotid-cavernous fistula. *J Neuroophthalmol* 2009; 29: 62-71.
3. Koenigsberg RA. Carotid cavernous fistula. (Online) (Cited April 2010). Available from URL: <http://emedicine.medscape.com/article/338870-overview>.
4. Barrow DL, Specter RH, Braun IF, Landman J, Tindall SC, Tindall GT. Classification & treatment of spontaneous carotid cavernous fistula. *J Neurosurgery* 1985; 62: 248-56.
5. Dolenc V. Direct microsurgical repair of intracavernous vascular lesions. *J Neurosurg* 1983; 58: 824-31.
6. Debrun G, Lacour P, Caron JP, Hurth M, Comoy J, Keravel Y. Detachable balloon and calibrated-leak balloon techniques in the treatment of cerebral vascular lesions. *J Neurosurg* 1978; 49: 635-49.
7. Serbinenko FA. Balloon catheterization and occlusion of major cerebral vessels. *J Neuro Surgery* 1974; 41: 125-45.
8. Raja IA, Vohra AH, Ahmed M. Neurotrauma in Pakistan. *World J Surgery* 2001; 25: 1230-7.
9. Chiu WT, LaPorte RE, Raja IA, Bouyoucef KA, Levy A. Head injuries in developing countries. In: Narayan RK, Wilberger JE, Povlishock JT Jr, (edi). *Neurotrauma*. New York: McGraw-Hill; 1996: 907-9.
10. Halbach V V, Heishima GB, Higashida RT. Carotid cavernous fistula: indications for urgent therapy. *Am J Neuro Radiol* 1987; 8: 627-33.
11. Clatterbuck RE. Surgical Treatment of Intracavernous Vascular Lesions: Indications and results. *Management of Cavernous Sinus Pathology Techniques in Neurosurgery*. 2003; 8: 230-7.
12. Barker FG 2nd, Ogilvy CS, Chin JK, Joseph MP, Pile-Spellman J, Crowell RM.

- Transethmoidal transsphenoidal approach for embolization of a carotid-cavernous fistula. Case report. *J Neurosurg* 1994; 81: 921-3.
13. YU Jia-sheng, LEI Ting, CHEN Jin-cao, HE Yue, CHEN Jian, LI Ling. Diagnosis and endovascular treatment of spontaneous direct carotid-cavernous fistula. *Chin Med J* 2008; 121: 1558-62.
 14. Gemmete JJ, Ansari SA, Gandhi DM Endovascular techniques for treatment of carotid-cavernous fistula. *J Neuroophthalmol* 2009; 29: 62-71.
 15. Li MH, Tan HQ, Fang C, Zhu YQ, Wang W, Wang J, et al. Trans-arterial embolisation therapy of dural carotid-cavernous fistulae using low concentration n-butyl-cyanoacrylate. *Acta Neurochir (Wien)* 2008; 150: 1149-56.
 16. Gandhi D, Ansari SA, Cornblath WT. Successful transarterial embolization of a barrow type D dural carotid-cavernous fistula with ethylene vinyl alcohol copolymer (Onyx). *J Neuroophthalmol* 2009; 29: 9-12.
 17. Lewis AI, Tomsick TA, Tew JM Jr. Management of 100 consecutive direct carotid cavernous fistulas: results of treatment with detachable balloons. *Neurosurgery* 1995; 36: 239-45.
 18. Higashida RT, Halbach VV, Tsai FY, Norman D, Pribram HF, Mehringer CM, et al. Interventional neurovascular treatment of traumatic carotid & vertebral artery lesions: results in 234 cases. *AJR Am J Roentgenol* 1989; 153: 577-82.
 19. Chen LZ, Xu MH, Yang DH, Zou YW, Zhang YD. Retrospective study on the endovascular embolization for traumatic carotid cavernous fistula. *Chin J Traumatol* 2010; 13: 20-4.
 20. Yoshida K, Melake M, Oishi H, Yamamoto M, Arai H. Transvenous embolization of dural carotid cavernous fistulas: a series of 44 consecutive patients. *AJNR Am J Neuroradiol* 2010; 31: 651-5.
-