

A 3 year old Girl with Fibrodysplasia Ossificans Progressiva

Pages with reference to book, From 223 To 225

Niloufer Sultan Ali, Riaz Qureshi (Division of Family Medicine, Department of Community Health Sciences, The Aga Khan University Hospital, Karachi.)

Introduction

Fibrodysplasia ossificans progressiva, previously called myositis ossificans progressiva, is a rare genetic condition, inherited as an autosomal dominant disorder with variable penetrance. Most affected patients appear to have had spontaneous mutations. The incidence of this disorder is low, less than 1 per 1,000,000 members of the population¹.

Initially the patient presents clinically with soft tissue swellings, often in the neck and occiput, back, shoulder, over the scapula and proximal parts of the limbs. These soft tissue swellings are oedematous muscle or swelling of a localized group of muscles. These local or diffuse swellings may regress, or may progress to ossification, It is not known that how often the lesions subside spontaneously and how often the ectopic bone formation follows². Remissions and relapses occur during the course of the disease. Heterotopic ossification begins at a mean age of 5 years. Progressive involvement leads to extensive immobility and eventual disability.

Bilateral congenital abnormalities of the great toes is very characteristic of fibrodysplasia ossificans progressiva, seen in more than 90% of patients. Virtually all patients have abnormally shortened great toes, hallux valgus or both. Some patients may have short first metacarpals^{3,4}.

Radiologically there is malformed first metatarsals which are usually elongated with medial angulation distally. The hypoplasia of the articulating proximal phalanx results in hallux valgus deformity. Often both first metacarpals are hypoplastic. These characteristic skeletal findings in association with the fibrous soft tissue mass is diagnostic of fibrodysplasia ossificans progressiva⁵.

Laboratory study results are normal, except for mild elevation of serum alkaline phosphatase levels during early periods of heterotopic ossification¹. The only laboratory finding is an elevated eosinophil count⁶.

The pathophysiology of this disorder is not clear. It has been postulated that there is defective regulation of the induction of endochondral ossification as the predominant pathogenetic mechanism of this disorder¹. Most of the patients may survive well into adulthood but with marked disability. Many of them die as a consequence of restrictive lung disease from ankylosis of the ribs.

The aim of the treatment is to prevent the formation of ectopic bone which causes ankylosis of joints and progressive immobility. Various modalities of treatment have been tried, such as steroids, mineral binding agents or calcification blocking agents such as ethylene-diamin-tetraacetate (EDTA), but all without success².

Disodium ethydrionate (ethane-Hydroxy-1, 1-diphosphonate or EHDP) has been used in the treatment of fibrodysplasia ossificans progressiva to prevent mineralization of areas of active myositis or the remineralization after surgical removal of established ectopic bone^{2,7-9}. Some authors have clearly established some beneficial effect of EHDP on acute progressive cases of fibrodysplasia ossificans progressiva but no demonstrable beneficial effect on the extensive and stabilised lesion. They have found that, most of the newly formed soft tissue swellings regressed within a few days without any evidence of calcification on subsequent x-rays⁷. L. Bruni et al in 1990 have shown very encouraging results with disodium ethydrionate (EHDP) in an 11 year old child with marked disability¹⁰. At present, disodium ethydrionate

(EHDP) is the only agent that has proved to be some how beneficial in such cases.

Case Report

The patient was a 3 year old female child, a product of a normal, full term pregnancy and a normal delivery. Birth weight is not known as the child was born at home. The child is the last sibling, has two elder brothers aged 11 years and 5 years and one sister who is 7 years old. All of them are normal and healthy. The child's parents are Second cousins and both of them are healthy. The child did not suffer from any neonatal complications. Her developmental history was normal.

At the age of 3 months mother had noticed for the first time a swelling over the occiput. There was no history of trauma or injury or any associated constitutional symptoms. Within few weeks, few more soft tissue rtiasses appeared near the occiput and moved gradually towards the mastoid process. The mother had taken the child to a hospital where she was reassured that the child has cephalohaematoma which will resolve. Swellings had regressed to some extent and no more new swellings appeared until two months ago, when the swelling over the occiput reoccurred and two more appeared over the parietal region. Within few weeks the child developed more swellings over left side of the neck and shoulder and upper part of back. Because of the swelling at the neck the range of neck movements was restricted. Again the parents took the child to the same hospital, where x-rays of skull and some laboratory tests were done. Coagulation disorder, cellulitis and rickets were considered in the differential diagnosis. She was reated at this Hospital with various antibiotics. As the swellings, continued to increase, and a conclusive diagnosis could not be ascertained her parents brought the child to the Aga Khan University Hospital Karachi for further assessment and treatment.

The physical Examination, showed a 3 year old female child, weighing 12.8 kg with a height of 92 cm. The muscles in the neck and the upper part of the back were swollen and firm to hard in consistency and she had limited neck movements. No swellings were noted in upper or lower limbs and neither at lower back. Her respiratory, cardiovascular and abdominal examinations were all unremarkable. She had bilateral short great toes with valgus deformity (Figure 1).

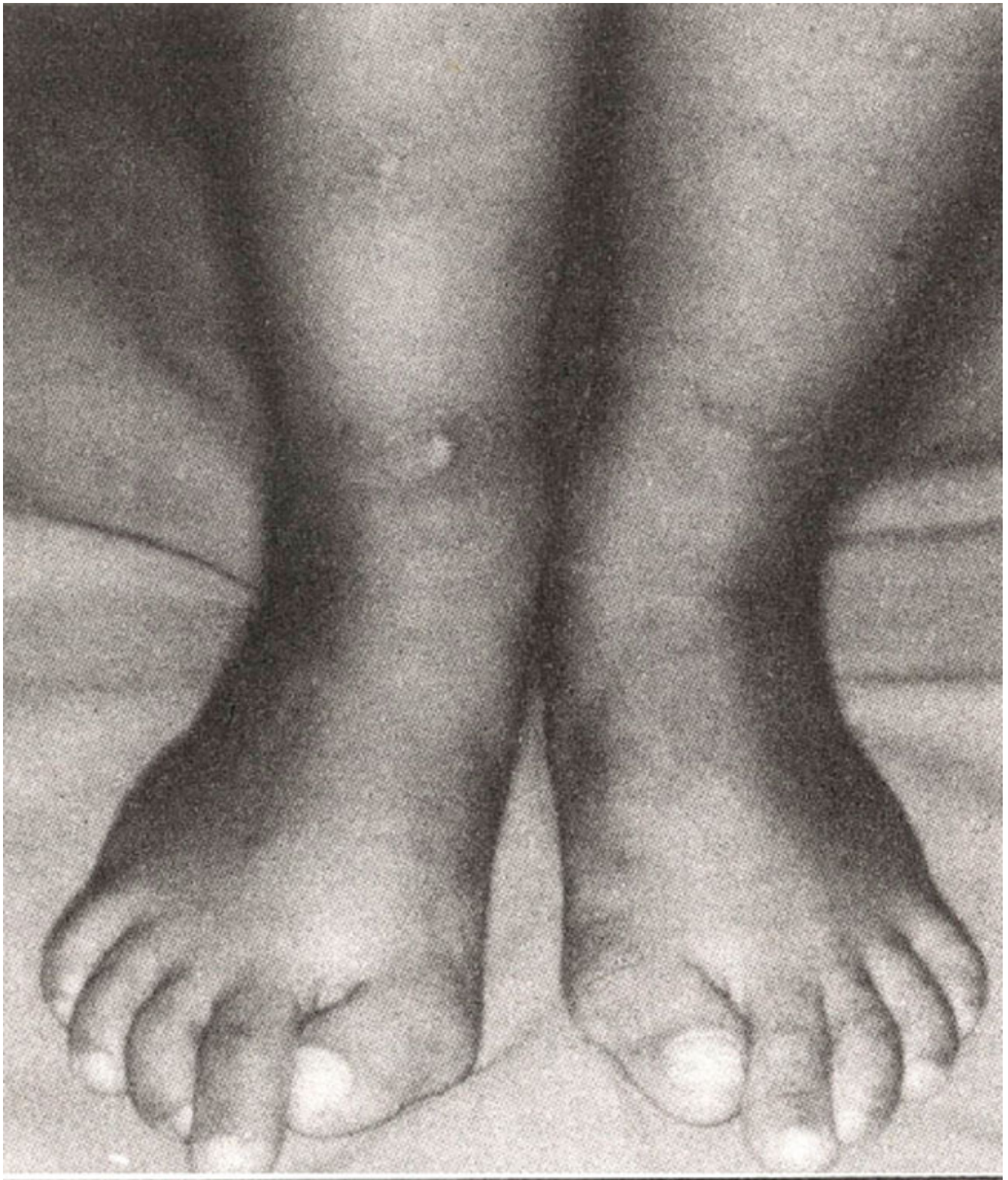


Figure 1. Clinical appearance of feet. Bilateral short great toes with valgus deformity.

Her soft tissue swellings which were bony hard as if ectopic bone had formed and bilateral abnormal great toes provided the initial clue towards the diagnosis of fibrodysplasia ossificans progressiva. Plain radiographs of soft tissue swelling of skull, neck, feet and hands were ordered. Some laboratory tests were also done.

Laboratory Findings. Her haemoglobin was 9.8 gm/dl and haematocrit of 30.9%. She had raised eosinophil count of 10% (n.y. 01 - 06 %) and her serum calcium, phosphorus and alkaline phosphatase were all within normal limits.

Radiological Findings. Plain radiographs of the skull and neck showed soft tissue swellings over the posterior parietal and occipital regions and also the right side of the neck. No calcifications were noted. Radiograph of the feet showed bilateral valgus deformities and malformed first metatarsals and hypoplastic proximal phalanges (Figure 2).

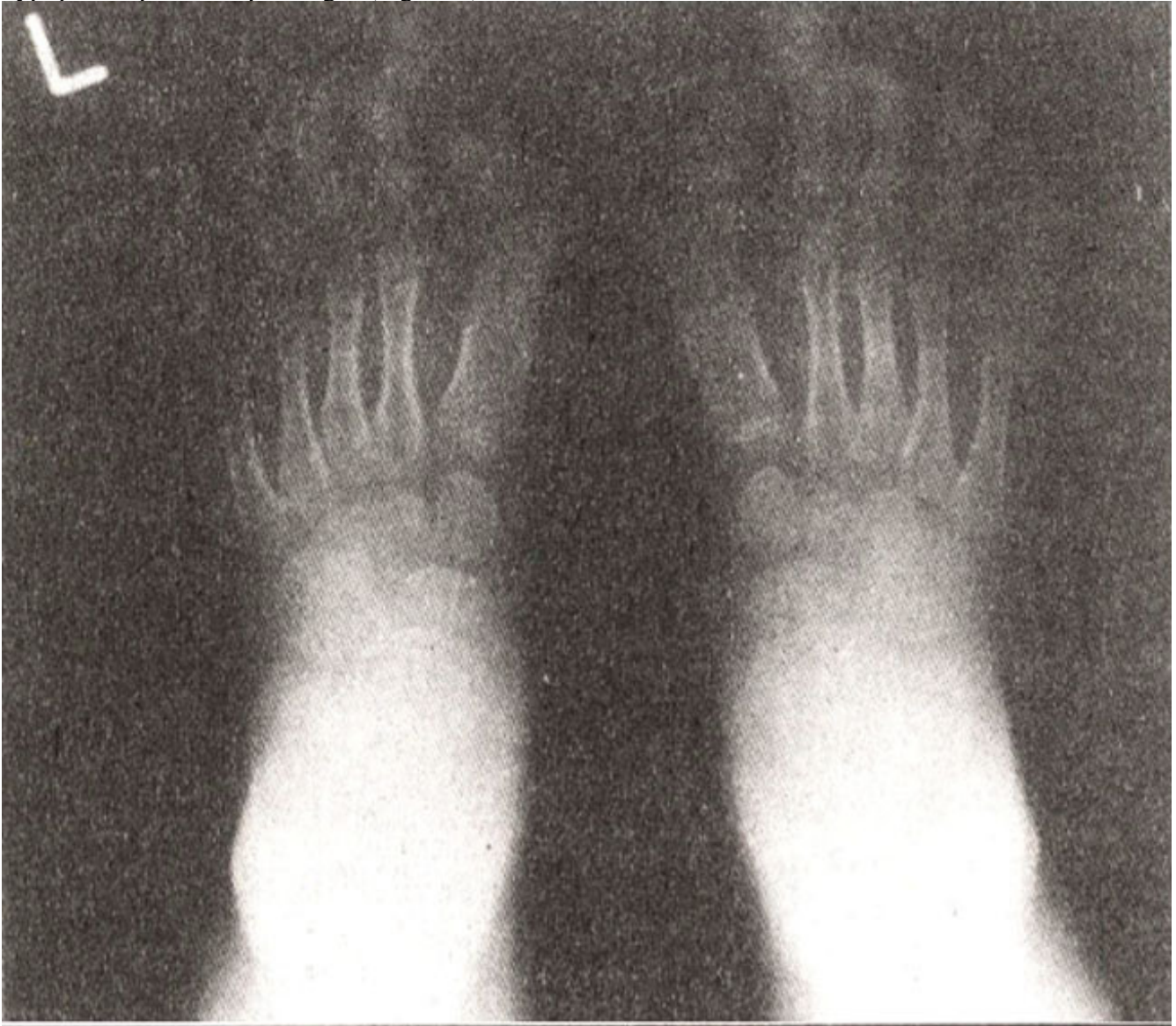


Figure 2. Radiograph of the feet showing hallux valgus deformity with malformed first metatarsals and proximal phalanges.

Radiograph of the hands showed bilateral hypoplasia of the first metacarpals (Figure 3).

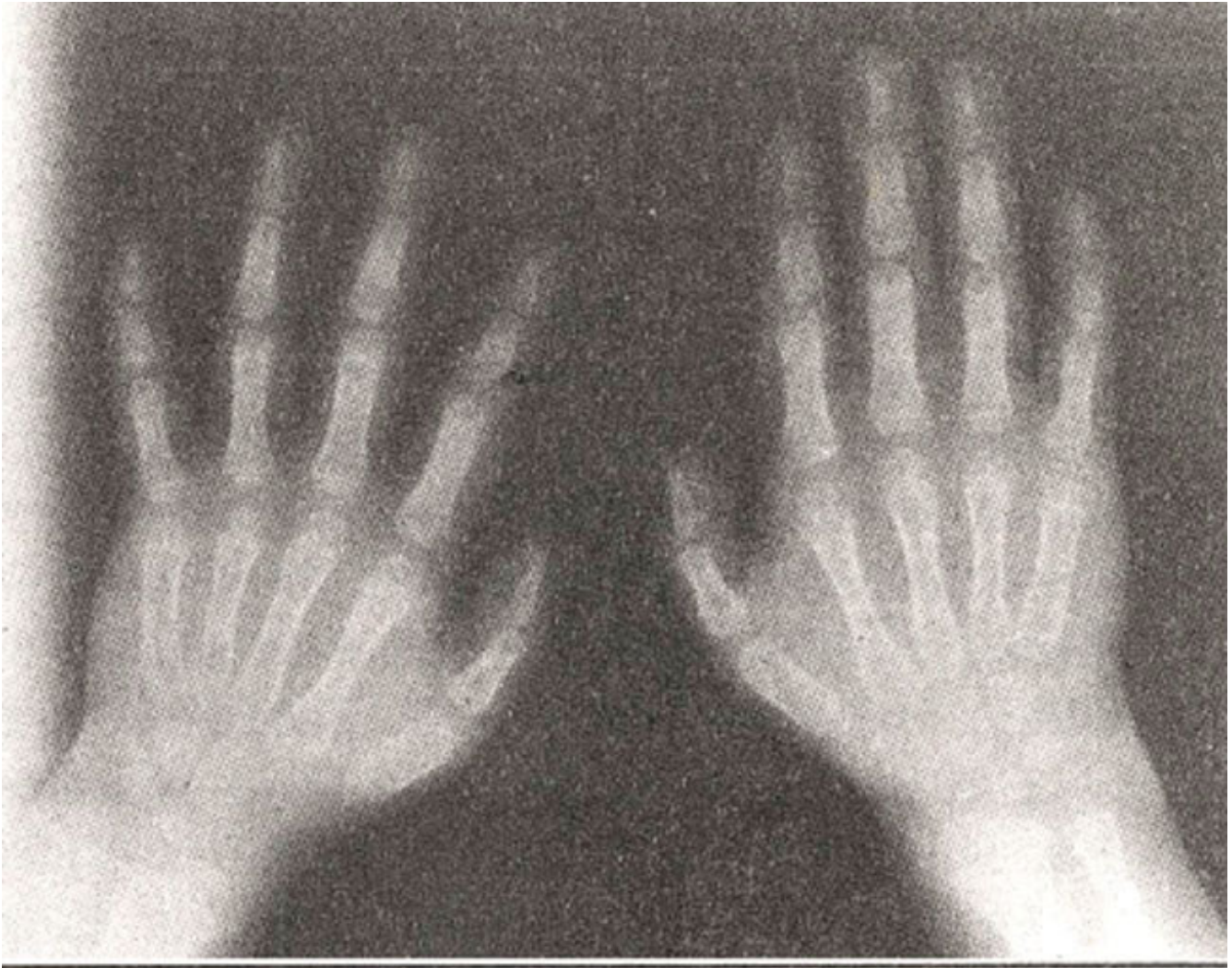


Figure3. Radiograph of the hands showing bilateral hypoplasia of the first metacarpals.

The changes were quite symmetrical on either side. These classic radiological skeletal findings in association with the fibrous soft tissue masses confirmed the diagnosis of fibrodysplasia ossificans progressiva.

She has been started on disodium ethydrionate 10 mg/kg/day orally for a four months cycle. Her baseline serum creatinine was 0.4 mg/dl (0.3 - 0.7) and she will be followed up diligently.

Discussion

The initial clinical presentation is appearance of soft tissue swellings on the neck, occiput or back of a young child. These swellings may regress, subside spontaneously or reoccur or may progress to ossification. So in early course of the disease the plain radiographic findings of the soft tissue masses are non specific prior to ossification. It is usually the soft tissue masses that bring the patient to medical attention.

The first diagnosis in patients with fibrodysplasia ossificans progressiva is often wrong and usually delayed until ectopic ossification begins. In our case an initial diagnosis of haematoma and some coagulation disorder was made at another hospital. This delay in the diagnosis could have been due to failure to recognize the significance of the bilateral abnormal big toes.

On reviewing the past literature it was discovered that many times even ultrasound, CT or the MRI

findings of the soft tissue masses are non specific prior to ossification^{5,11} and even the bone scan will not demonstrate the most acute lesions of fibrodysplasia ossificans progressiva¹². In past in many instances the results of biopsy of an early lesion were misinterpreted as fibromatosis or sarcoma before the roentgenographic appearance of ossification¹³. In fact a lesional biopsy is not needed to make the diagnosis. Biopsy uniformly exacerbates the condition and should be avoided¹³.

In conclusion, this case emphasizes that the early diagnosis of fibrodysplasia ossificans progressiva is based on the clinical findings and radiological demonstration of the skeletal malformations, prior to ossification. The importance of early diagnosis is to potentially save the patient from exposure to trauma, intramuscular injections, biopsy and operations, as all these can precipitate the lesions and exacerbate ossification.

References

1. Sponseller-PD. Localized disorders of bone and soft tissue. In: Morrissy-RT, Weinstein-SL. Pediatric Orthopaedics. 4th ed., Vol. 1, Philadelphia Raven 'Press, 1996: 305-339.
2. Smith-R, Russell-RGG, Woods-CG. Myositis Ossificans Progressiva -Clinical features of eight patients and their response to treatment, J. Bone Joint Surg., 1976,58-B:48-57.
3. Connor-JM, Evans-DAP. Fibrodysplasia ossificans progressiva: the clinical features and natural history of 34 patients. J. Bone Joint Surg., 1982;64B:7683.
4. Thickman-D, Bonakdapour-A, Clancy-M, et al. Fibrodysplasia ossificans progressiva. Am. J. Roentgenol., 1982;139:935-41.
5. Caron-KH, DiPietro-MA, Aisen-AM, et al. MR imaging of early fibrodysplasia ossificans progressiva. J. Comput. Assist. tomogr., 1990;14:3 18-2 1.
6. Turek-SL. Orthopaedics. 4th ed. Vol. 1, Philadelphia: JB Lippincott Company, 1984:684.
7. Bassett-CAL, Donath-A, Macagno-F, et al. Diphosphonates in the treatment of myositis ossificans. Lancet, 1 969~ii :845.
8. Weiss-IW, Fisher-L, Phang-JM. Diphosphonate therapy in a patient with myositis ossificans progressiva. Ann. Intern. Med., 1971 ;74:933-36.
9. Russell-RG, Smith-R, Bishop-MC, et al. Treatment of myositis ossificans progressiva with a diphosphonate. Lancet, 1972;1: 10-12.
10. Bruni-L, Giammaria-P, Tozzi-MC, et al. Fibrodysplasia ossificans progressiva: An 11-year-old boy treated with a diphosphonate. Acta. Paediatr. Scand., 1990;79:994-98.
11. McAteer-JE, Hallam-LA, Hendry-GMA. Ultrasonic appearances of the early changes in fibrodysplasia ossificans progressiva. Br. J. Radiol., 1990;63:809-12.
12. Carter-SR, Davies-AM, Evans-N, et al. Value of bone scanning and computed tomography in fibrodysplasia ossificans progressiva. Br. J. Radiol., 1989;62:269-72.
13. Kaplan-FS, Tabas-JA, Gannon-FH, et al. The histopathology of fibrodysplasia ossificans progressiva. An endochondral process. J-Bone-Joint-Surg., 1 993;75(AM): 220-30.