

Idiopathic pulmonary haemosiderosis presenting as severe iron deficiency anaemia — a case from Pakistan

Noureen Afzal,¹ Ammara Mushtaq,² Arshalooz Rahman,³ Sonia Qureshi⁴

Department of Paediatrics, Aga Khan Secondary Hospital, Karimabad,¹ 2nd Year Medical Student, Dow Medical College, Dow University of Health Sciences,² Department of Paediatrics, Aga Khan University Hospital,^{3,4} Karachi.

Corresponding Author: Noureen Afzal. Email: noureen.afzal@aku.edu.

Abstract

Idiopathic pulmonary haemosiderosis is an uncommon disorder, which is characterized by iron deficiency, recurrent haemoptysis and diffuse parenchymal infiltration on chest radiograph. We report an 8 year old child who had past history of multiple blood transfusions with diagnosis of iron deficiency anaemia and recurrent chest infection since the age of 2 1/2 year. At the age of 8 years, the child presented with fever and severe respiratory distress requiring intubation and ventilation. On Chest X-ray, bilateral white out was found and CT scan lung showed diffuse alveolar involvement. Lung biopsy confirmed haemosiderin-laden macrophages. Child was put on steroids and despite severe anaemia (Hb 3.2 g/dl), he showed improvement and survived. To our knowledge, this is the first case of idiopathic pulmonary haemosiderosis reported from Pakistan.

Keywords: Haemosiderosis, Iron deficiency anaemia, Haemoptysis, Steroid, Haemosiderin-laden macrophages.

Introduction

Idiopathic pulmonary haemosiderosis (IPH) is a rare but potentially lethal disorder in young children with an unknown aetiology and reported incidence of 0.24 to 1.23.¹

The diagnosis of IPH is based on exclusion of other more common causes of intrapulmonary haemorrhage or other extrapulmonary diseases. Diagnosis is suggested by the triad of haemoptysis, anaemia and pulmonary infiltrates and is secured by the finding of haemosiderin-laden macrophages (siderophages) in broncho-alveolar lavage fluid.

In a study, 17 patients with IPH had anaemia and cough as initial clinical presentation.² Pallor being the presenting symptom without cough in patients with IPH has been reported unusual and such patients are considered to have been diagnosed erroneously.³

The clinical course and management of IPH has been extremely variable, and some of the patients continue to have pulmonary haemorrhage regardless of aggressive interventions. The use of corticosteroids has been thought to be effective in

decreasing the frequency of haemorrhage although its role still remains controversial as some studies suggested that corticosteroid therapy failed to alter the long-term course or prognosis of IPH.^{4,5}

Case Report

We present here a case of an eight and a half year old boy admitted through emergency services to a private care sector hospital in Karachi, Pakistan with symptoms of intermittent low grade fever with dry cough for five days and one day history of sudden onset of shortness of breath. There were no other constitutional symptoms. On examination, the boy was anxious, pale and cyanosed with marked respiratory distress. Vitals were deranged with pulse rate of 155 per minute, respiratory rate of 60 per minute and blood pressure of 103/75 mm Hg. The boy had an oxygen saturation of 45% at room air with decreased air entry bilaterally with widespread coarse crepitations as positive systemic signs. Owing to his respiratory distress he was intubated. On Intubation, there was 10ml of fresh blood from endotracheal tube (ETT) after which the patient was transferred to the Paediatric Intensive Care Unit (PICU). The laboratory tests showed a hypochromic, microcytic

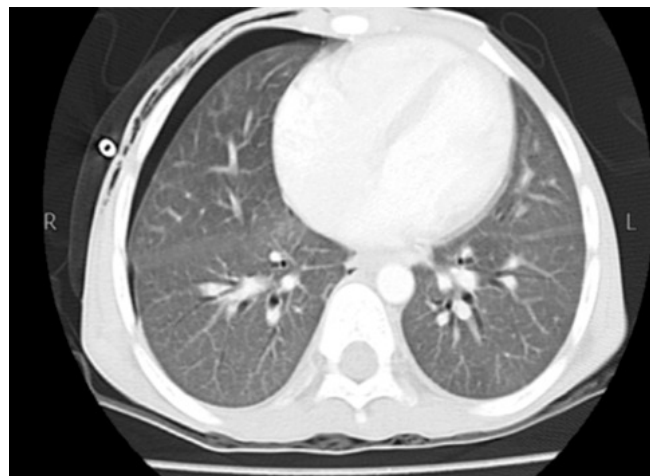


Figure-1: CT scan chest.

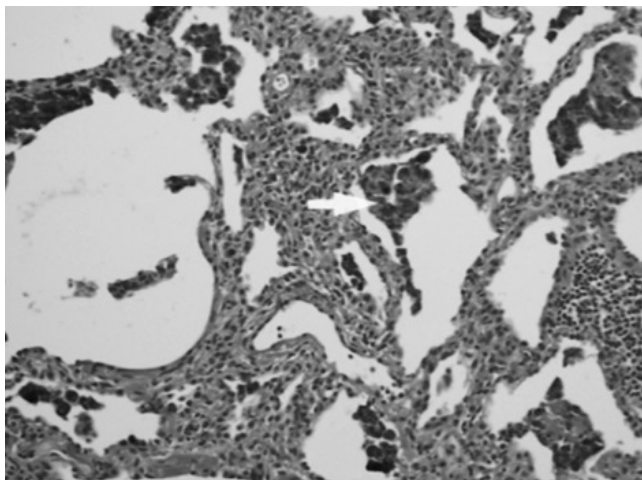


Figure-2: Alveoli laden with haemosiderin.

anaemia (Hb: 3.2g/dl, haematocrit 11.6, MCV 60.4 and MCHC 27.7). The septic parameters including total TLC counts, CRP and ESR were in normal range. Multiple blood cultures were sent from the ICU but they revealed no growth. Workup for haemolysis showed normal Reticulocyte Count and Coombs' test. Arterial blood gases persistently showed hypoxia. The post intubation X-rays was done as shown in Figure-1.

In PICU the boy required high ventilator parameters and inotropic support and was started on meropenem, and vancomycin along with supportive management. C-Xray was done showed bilateral white out (Figure-1) so methylprednisolone (2mg/kg/dose 6 hourly for 48 hours) was started considering the diagnosis of acute respiratory distress syndrome. Child was later put on prednisolone (2mg/kg/day) for 2 weeks. CT lung was also performed to see interstitial lung disease as shown in Figure-2.

The child's past medical history revealed he had multiple admissions since age 2 ½ years of age for blood transfusions due to Iron Deficiency Anaemia. There was an ICU admission at age 3 ½ years for fever and cough, and afterwards monthly hospital visits for the same complaints which were treated with nebulization and antibiotics. A bone marrow aspiration was done that revealed hypochromic, microcytic indices, absent Iron storage and blast cells <5%. There was no evidence of granuloma or malignancy. He had been on iron and folate supplementation for past year as well. With this history, clinical exam and investigations the probability of pulmonary haemosiderosis was considered and lung biopsy was performed which showed haemosiderin-laden macrophages in the alveoli and interstitium.

The child remained in the PICU for 9 days. He showed marked improvement after steroid therapy and was extubated and shifted to special care and put on prednisolone and

cyclophosphamide. He developed hematuria on cyclophosphamide so he was put on azathioprine. Child was discharged on prednisolone and azathioprine. He was followed up in the clinic. He is thriving well with no further need of blood transfusion. The steroids were tapered and no recurrence has yet taken place.

Discussion

Idiopathic pulmonary haemosiderosis is a rare disease in Paediatrics. Although aetiology remains unknown, IPH is considered to be an immune mediated disease. The finding of Anti-neutrophil Cytoplasmic Antibody (ANCA) is thought to be a sign of poor prognosis for pulmonary progression,⁶ and it was not found in our case. IPH is a rare disease characterized by the triad haemoptysis, iron deficiency anaemia, and parenchymal infiltrate on chest X-ray, however only of these might manifest initially.⁷ These symptoms might lead to misdiagnosis of other common diseases like pneumonia, tuberculosis, foreign bodies, cardiac disease or bleeding disorders.⁸ Also, haemoptysis in our case was initially wrongly explained by parents and was mistaken for haematemesis, therefore, it is important to distinguish between the two in a clinical setting.^{8,9} Other studies, however, have included different respiratory symptoms, such as recurrent cough, wheezing, and tachypnea.⁷ Though less frequently, IPH clinical status might also include hepatosplenomegaly, pallor and clubbing.⁷ In a recent study evaluating 28 cases of IPH, 100% had cough while around 90% had haemoptysis and chest infiltrates, 75% had anaemia while only 58% had the classical triad of haemoptysis, iron deficiency anaemia, and parenchymal infiltrate on chest X-ray. Initial manifestations of IPH were cough and haemoptysis in 50% of cases while 30% had anaemia.⁸

Iron deficiency anaemia requiring multiple blood transfusions was the most marked symptom in our case and many other previous cases reported^{1,2,7,9,10} and it can be the only presenting symptom in IPH.⁴ In our case, anaemia was more severe than in other cases.^{1,2,7,9} More severe anaemia in IPH patients has been hinted to result in poor outcome,² but our case thrived well.

Our patient presented with fever, cough and respiratory distress. Child had a history of multiple transfusions of packed cell previously with diagnosis of severe iron deficiency anaemia, recurrent chest infection was treated with nebulization. There was a history of haemoptysis. The symptoms were very vague therefore diagnosis was delayed. In our patient there was 6 years delay between symptoms and diagnosis.

Our case responded well to steroids and survived. Even though the aetiology of the disease is unknown and there are no large controlled studies on IPH, immunosuppressive agents have

been the mainstay of treatment.^{1,7} To decrease the episodes of haemorrhage and bleeding, steroids in high dose are considered the treatment of choice initially.^{1,7} However, there have been reports on the ineffectiveness of steroids in some patients wherein, the alternatives can be other immunosuppressive agents like azathioprine, chloroquine, methotrexate and cyclophosphamide.^{1,7,9} Lung transplant maybe considered for chronic treatment and in two of the reported cases, IPH recurred after lung transplantation.⁹ Studies indicate varied response to immunosuppressants; early active and extended courses of immunosuppressive therapy may improve the prognosis. Our patient showed improvement on Prednisolone. Saeed et al² found that 5 years survival of patients with IPH was 86% because of long term aggressive therapy with immunosuppressants. Treatment is continued according to patient's need.²

Another study presented a similar case but it was diagnosed relatively earlier, i.e. nine months after the onset of symptoms.¹⁰ In a retrospective review of 26 iph cases, the mean gap between onset of symptoms and diagnosis was 30 months.⁷ The reasons for delay in diagnosis include focus on more common disorders with similar presentation, absence of characteristic triad and unawareness about this rare condition.⁷ Therefore, the diagnosis of IPH is made after exclusion of other possible causes and unresponsiveness to treatment of other suspected morbidities. The gold standard for IPH diagnosis is lung biopsy but finding of haemosiderin-laden macrophages on bronchoscopy or gastric aspirate or sputum along with presence of chronic pulmonary symptoms is sufficient to diagnose the case.⁷

Conclusion

Idiopathic pulmonary haemosiderosis although a rare entity, should be considered in patients with long term iron deficiency anaemia and multiple transfusions without any obvious cause. It will prevent unnecessary laboratory analysis, blood transfusions and improve patient's outcome in a timely manner.

References

1. Almutairi A, Behbehani N, Mohammed TMM. Idiopathic Pulmonary Hemosiderosis. *Kuwait Med J* 2009; 41: 146-8.
2. Saeed MM, Woo MS, MacLaughlin EF, Margetis MF, and Keens TG. Prognosis in pediatric idiopathic pulmonary hemosiderosis. *Chest* 1999; 116: 721-5.
3. Nielsen V.R., Valerius N.H. Idiopathic pulmonary hemosiderosis. A cause of severe iron deficiency anemia in childhood. *Ugeskr Laeger* 1995; 157: 176-8.
4. Chen KC, Hsiao CC, Huang SC, Ko SF, Niu CK. Anemia as the Sole Presenting Symptom of Idiopathic Pulmonary Hemosiderosis: Report of Two Cases. *Chang Gung Med J* 2004; 27.
5. Chryssanthopoulos C, Cassimos C, Panagiotidou C. Prognostic criteria in idiopathic pulmonary hemosiderosis in children. *Eur J Pediatr* 1983; 140: 123-5.
6. Milman N, Pedersen FM., Idiopathic pulmonary haemosiderosis. Epidemiology, pathogenetic aspects and diagnosis. *Respir Med* 1998; 92: 902-7.
7. Kabra SK, Bhargava S, Lodha R, Satyavani A, Walia M. Idiopathic Pulmonary Hemosiderosis: Clinical Profile and Follow up of 26 Children. *Indian Pediatr* 2007; 44: 333-8.
8. Zhang X, Wang L, Zhang M. Clinical Study of 28 Cases of Paediatric Idiopathic Pulmonary Haemosiderosis. *J Trop Pediatr* 2010; 56: 386-90.
9. Sunilkumar BM, Sathishkumar KM, Somashekhar AR, Maiya PP. Idiopathic Pulmonary Hemosiderosis. *J Pediatr Sci* 2010; 6: 56.
10. Derbent M, Ozçay F, Saatçi U, Ozbek N. Severe iron deficiency anemia in a child with idiopathic pulmonary hemosiderosis: a case report. *Turk J Pediatr* 2002; 44: 258-60.