

# Helical CT scan with 2D and 3D reconstructions and Virtual Endoscopy versus conventional endoscopy in the assessment of airway disease in neonates, infants and children

Mahira Yunus

Al-Noor Hospital Makkah, KSA.

Email: mahiraabubakar@gmail.com

## Abstract

**Objectives:** To study the use of helical computed tomography 2-D and 3-D images, and virtual endoscopy in the evaluation of airway disease in neonates, infants and children and its value in lesion detection, characterisation and extension.

**Methods:** Conducted at Al-Noor Hospital, Makkah, Saudi Arabia, from January 1 to June 30, 2006, the study comprised of 40 patients with stridor, having various causes of airway obstruction. They were examined by helical CT scan with 2-D and 3-D reconstructions and virtual endoscopy. The level and characterisation of lesions were carried out and results were compared with actual endoscopic findings. Conventional endoscopy was chosen as the gold standard, and the evaluation of endoscopy was done in terms of sensitivity and specificity of the procedure. For statistical purposes, SPSS version 10 was used.

**Results:** All CT methods detected airway stenosis or obstruction. Accuracy was 98% (n=40) for virtual endoscopy, 96% (n=48) for 3-D external rendering, 90% (n=45) for multiplanar reconstructions and 86% (n=43) for axial images. Comparing the results of 3-D internal and external volume rendering images with conventional endoscopy for detection and grading of stenosis were closer than with 2-D minimum intensity multiplanar reconstruction and axial CT slices. Even high-grade stenosis could be evaluated with virtual endoscope through which conventional endoscope cannot be passed. A case of 4-year-old patient with tracheomalacia could not be diagnosed by helical CT scan and virtual bronchoscopy which was diagnosed on conventional endoscopy and needed CT scan in inspiration and expiration.

**Conclusion:** Virtual endoscopy [VE] enabled better assessment of stenosis compared to the reading of 3-D external rendering, 2-D multiplanar reconstruction [MPR] or axial slices. It can replace conventional endoscopy in the assessment of airway disease without any additional risk.

**Keywords:** Helical CT, Computed tomography, Airway stenosis. (JPMA 62: 1154; 2012)

## Introduction

Non-invasive imaging of the airways has made remarkable progress in the past decade. The introduction of multi-row detector CT scanners has made it possible to acquire high-resolution images of the upper, central and segmental airways within a short time. The CT data can subsequently be reconstructed into elegant two-dimensional (2-D) reformations and three-dimensional (3-D) images, including internal virtual endoscopic (VE) renderings that closely simulate images from conventional endoscopy. Non-invasive cross-sectional airway imaging has also progressed from a static technique to one that provides a dynamic assessment.<sup>1,2</sup>

Multi-detector helical CT has increased the speed of scanning, motion artifacts are reduced and it creates even higher quality 2-D and 3-D reformation images<sup>3</sup> compared

to single-detector helical CT scan.

## Patients and Methods

The retrospective, observational study was conducted at Al-Noor Hospital, Makkah, Saudi Arabia, from January 1 to June 30 2006, and included 60 patients, divided into two groups. Group I was the Control group having 20 children. Group II was the Study group. It had 40 children. Their were 26 males and 14 females who were referred to the Radiology Department by chest physicians for the evaluation of stridor.

All patients were subjected to history-taking and clinical examination with special emphasis on prematurity, associated medical problems and intubation details, including the date of first intubation, duration and size of the endotracheal tube, number of intubations and if any intubations had been traumatic. Helical CT scanning was

carried out followed by endoscopy.

Statistical analysis was carried out using SPSS version 10. Simple descriptive statistics such as mean  $\pm$  SD were used for continuous variables, while frequency and percentages were used for categorical data. Conventional endoscopy was chosen as the gold standard and the evaluation of virtual endoscopy was made in terms of sensitivity and specificity of the test.

Unenhanced helical CT examination was performed on a 4-rowed multi-detector LightSpeed Plus scanner (General Electric Medical Systems) with the following protocol: collimation/table feed/reconstruction increment 2.5mm/3.75mm/1mm from the nasal cavity to the carinobronchial septum. Then 2-D minimum intensity projections (minIP) in the form of multiplanar reconstructions [MPR] and multiplanar volume reconstructions [MPVR] were done. After that 3-D reconstruction in the form of external rendering [tissue transition projection, TTP] and internal rendering [virtual endoscopy, VE] were performed on the Advantage Windows workstation (General Electric Medical Systems). For optimal orientation within the airways and evaluation of the surrounding structures, virtual endoscopy was performed in the multiview mode in combination with dynamic axial and multiplanar reformatted imaging. Tracheostomy tubes were removed whenever possible before scanning to avoid image artifact. Iodinated contrast media was only employed when it was necessary to view surrounding vasculature.

Oral sedation was administered before examination (chloral hydrate, 50 mg/kg body weight). If the initial dose failed, more chloral hydrate was given up to a maximal dose of 1 g. Additional intravenous (IV) midazolam (Dormicum) was given (0.2-0.5 mg/kg body weight) if oral sedation failed. The patients were carefully monitored for vital signs such as pulse, rate and oxygen saturation during and after the examination.

Imaging data for all patients were analysed and compared with the findings of conventional endoscopy and/or operative findings obtained within 20 days of the CT.

For conventional endoscopy, nasal assessment was done by rigid Hopkins 300 nasal endoscope with angle of 0, 30 degree and a diameter of 2.7 mm. The nasal mucosa was decongested prior to endoscopy with topical Afrin.

We used a 3 mm endoscope after topical anaesthesia and decongestion with topical Afrin and lidocaine. This procedure was done in the supine or sitting position. Pre-medication with intramuscular (IM) atropine 0.4-0.6 mg and IV diazepam 2-5 mg (up to 10mg) were given 15 minutes before bronchoscopy.

While the patient were usually lying supine or semi-recumbent, the upper airways were anaesthetised with lidocaine nebulizer 1% concentration, in addition to lidocaine gel 2% applied to the nose before the procedure.

Additional small quantities of lidocaine were instilled through the bronchoscope as needed to control cough (maximum dose of lidocaine was limited to 4mg/kg of body weight).

Fiberoptic bronchoscopy was done using Olympus BF (P10 and XT20) flexible fiberscope. Bronchoscopy was performed through a nasal route; otherwise an oral route was used in cases of small nose, deviated septum or big nasal polyps.

During bronchoscopy, the patients were monitored by automated blood pressure and pulse oximetry. Oxygen supplementation was used to achieve an oxygen saturation of at least 90%.

After bronchoscopy, the patients were observed for the onset of complications (mainly bleeding, pneumothorax and hypoxaemia) and until the effects of sedative drugs had subsided and the gag reflex had returned.

Rigid bronchoscopy was done in cases of foreign body removal, using the Wolf's universal bronchoscope with Lumina telescope via an endotracheal tube under general anaesthesia by means of IV barbiturates and muscle relaxant. Images were recorded on a Sony cyber-shot digital still camera from the monitor.

## Results

The Control group had 20 children (12 males and 8 females) of ages ranging from 1 day to 7 years. They had

**Table-1: Regions and number of lesion in the study group.**

Site of lesion	No. of patients	No. of lesions
Nasal cavity	11(27.5%)	16(32%)
Laryngeal	12(30%)	12(24%)
Tracheal	11(27.5%)	16(32%)
Bronchial	6(15%)	6(12%)
Total	40	50

**Table-2: Pathologic entities encountered.**

Pathology	Number of lesions
Choanal atresia	9(18%)
Choanal stenosis	7(14%)
Subglottic stenosis	11(22%)
Subglottic foreign body	1(2%)
Tracheal stenosis	15(30%)
Bronchial stenosis	5(10%)
Endobronchial foreign body	1(2%)
Tracheomalacia	1(2%)
Total	50

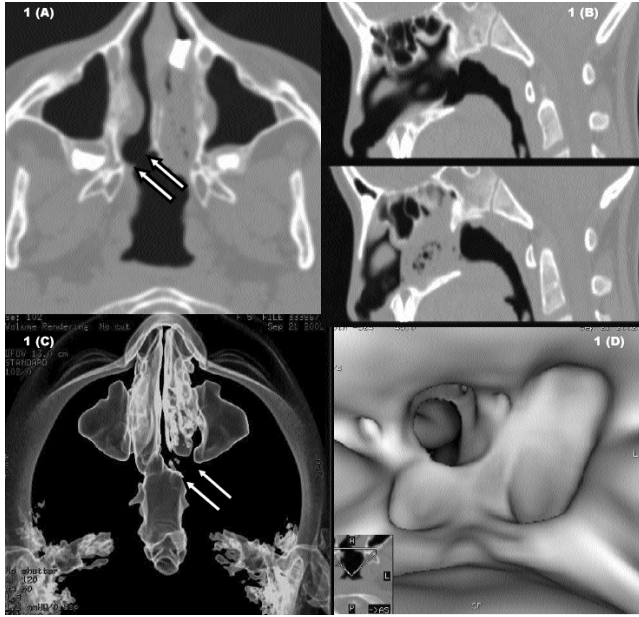


Figure 1: 5-year-old child with history of difficulty in breathing. (a) Axial image shows complete atresia of left nasal choana. Note small spurs at right nasal choana (arrows) which cause choanal stenosis. (b) 2D sagittal reformatted images show complete occlusion of left nasal choana. (c) 3D external reconstruction shows non-continuity of the nasopharyngeal air column on left side (Arrows). (d) 3D internal reconstruction through the nasopharynx confirmed complete atresia of the left nasal choana and partial obstruction of the right choana.

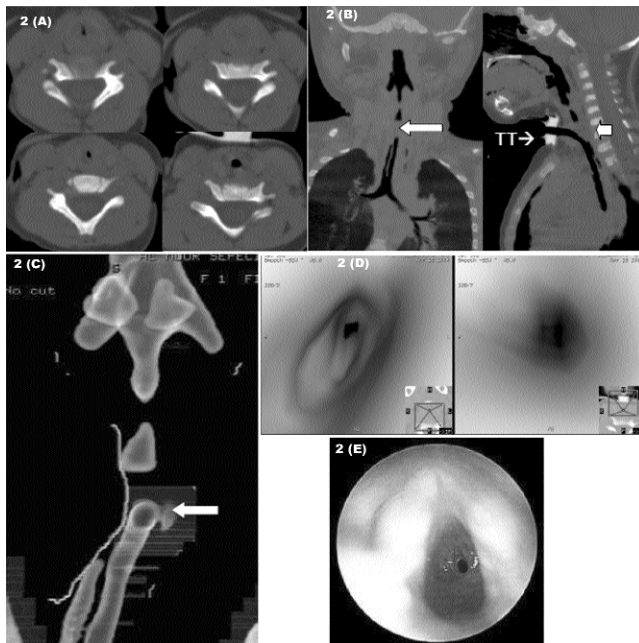


Figure-2: Four-month-old infant with acquired subglottic stenosis from intubation. (a): Axial CT sections show site of stenosis (curved arrow). (b): Coronal and sagittal and reconstruction images show two stenotic segments (the distal stenosis is marked by straight arrow). Tracheostomy tube (TT) is also shown. (c): 3D external reconstruction shows two stenotic segments, cranial one is in subglottic region and caudal one is in trachea; tracheostomy tube is marked by TT. (d) Virtual endoscopic view of stenosis, assessing the stenotic segment from above and below. (e) A close-up view of the stenosis as viewed in conventional endoscopy.

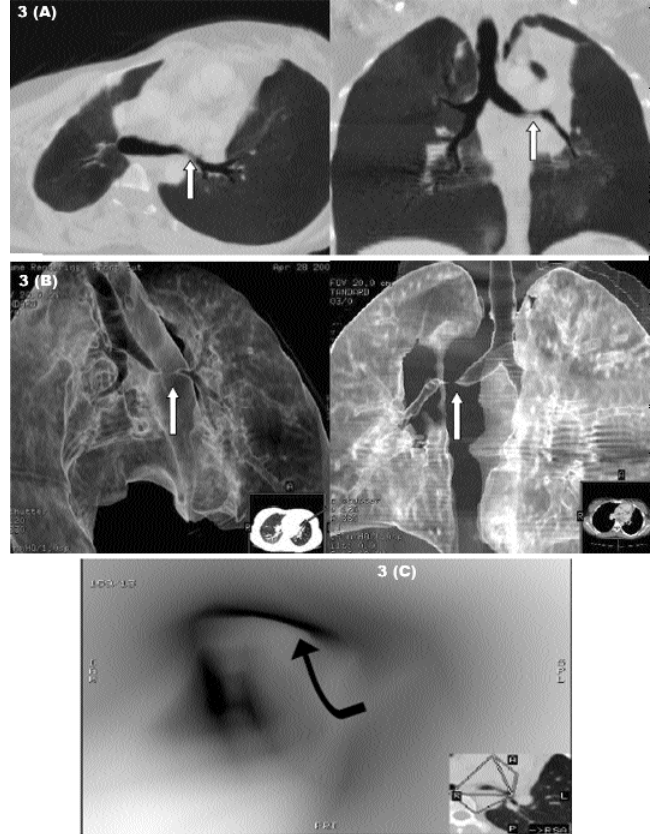


Figure-3: 14-year-old girl with persistent collapse of anterior segment of left upper lobe. (a): 2D multiplanar volume reconstruction images (axial and coronal) show stenosis in the left main bronchus. (b): 3D Tissue transition projection in different views display the left bronchial stricture and bronchial tree of both lungs. (c) Virtual endoscopy shows narrowed left bronchial lumen. Conventional endoscopy and biopsy revealed endobronchial tuberculous.

Table-4: Lesion detectability on CT images for 51 lesions encountered.\*

	2-D		3-D	
	Axial	MPR	TTP	VE
Lesions detected	43 (86%)	45 (90%)	48 (96%)	49 (98%)

\* One case with tracheomalacia could not be diagnosed with helical CT scan. MPR: Multiplanar reconstruction. TTP: Tissue transition projection. VE: Virtual endoscopy.

been referred to the Radiology Department for causes not related to the airways. Helical CT scan for airways was performed in these children after taking consent from the parents. Group II was the Study group and included 40 children of ages ranging between 1 day and 14 years. They had been referred for the evaluation of stridor.

Anatomical regions involved in the study population (Table-1), and the different pathologic entities encountered (Table-2) were noted down.

Nasal cavity and laryngeal regions were the most

**Table-3: Comparison between conventional and virtual endoscopy in the 50 lesions encountered.**

Lesion	Conventional	Virtual	Comment
Choanal Atresia	9	9	Conventional endoscopy was more accurate as regard the cause of obstruction e.g. bony or membranous
Choanal stenosis	7	7	
Subglottic stenosis	11	11	Severe stenosis in 4 lesions could not be passed by conventional endoscope versus 1 lesions by VE **
Subglottic FB	1	1	VE guided interventional endoscope for removal.
Tracheal stenosis	10	15	5 lesions were not seen by conventional endoscope due to marked proximal stenosis (4 subglottic and 1 tracheal) which interfere with passage of the endoscope. **
Bronchial stenosis	5	5	Extra-luminal masses could not be detected in 2 lesions.
Endobronchial FB	1	1	VE guided conventional endoscope for removal
Tracheomalacia	1	-	VE could not diagnose this lesion.
Total	45	49	

\*\*Both virtual endoscopy (VE) and conventional endoscopy concurred with the diagnosis of marked stenosis (71-99%) in 5 lesions, but neither the length nor the distal view of trachea could be visualised during conventional endoscopy. With VE, retrograde views could be obtained and measurements of these lesions could be achieved at all angles. FB: Foreign body.

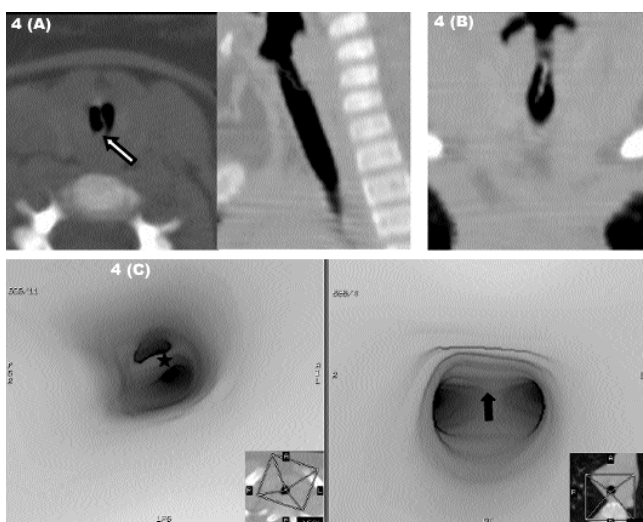


Figure-4: 4-year-old child with history of stridor. (a) Axial image shows foreign body (FB) impacted in the subglottic region and bisecting the lumen. (b). Sagittal and coronal multiplanar volume reconstruction show the craniocaudal extent of the FB. (c) Virtual endoscopy: upper images are antegrade views that show the FB (star) in subglottic region. No other lesions down to carina (arrow). Pre-operative VE-guided removal of this FB by interventional endoscopy.

common sites affected. Choanal atresia and/or stenosis (Figure-1), subglottic and tracheal stenosis (Figure-2), and bronchial stenosis (Figure-3) were the commoner lesions observed, while foreign body aspiration (Figure-4) was also noted in the study.

The case of a 4-year-old patient with tracheomalacia could not be diagnosed by helical CT scan and virtual bronchoscopy due to dynamic nature of the disease and non-cooperative status in this age group.

Comparison was also done between conventional and virtual endoscopic findings in the 50 lesions encountered in the study (Table-3), while the detectability of lesions by different imaging protocols of CT scan was also tabulated (Table-4).

## Discussion

The larynx in paediatrics differ from the larynx in the adults. It is relatively smaller than in the adults, higher in the neck and is more difficult to see. The epiglottis is surrounded by loose connective tissue. Rough instrumentation may encourage the inflammatory oedema to surround the laryngeal inlet. In addition, the mucosa in the subglottis is lax and full of mucous glands, and easily becomes oedematous. Laryngeal spasm occurs more easily in the child than in the adult. The childhood larynx seems to be physiologically more brittle.<sup>3</sup>

Conventional endoscopic assessment of the respiratory tract carries some risks, especially in children because any trauma in the laryngeal region may cause severe stridor and respiratory obstruction.

The risk of conventional endoscopy opens the way for attempts to locate a new diagnostic tool without risk, and virtual endoscopy is one of the developments in this field.

The newer multi-detector helical CT techniques allow very short acquisition time, and, hence, respiratory motion artifacts are reduced. They also reduce radiation exposure.<sup>4</sup>

In our study, axial images were the least sensitive in lesion detection. This was due to several limitations, including limited ability to detect subtle airway stenosis, under-estimation of the craniocaudal extent of disease, difficulty in displaying the complex relationships of the airway to adjacent mediastinal structures, inadequate representation of airways oriented obliquely to the axial plane and difficulty in assessing the interfaces and surfaces of airways that lie parallel to the axial plane. Another relative limitation of axial CT scanning is the generation of a large number of images for review, especially with multi-detector scanners, which may generate data sets containing hundreds of images; and adequate assessment of airways

needs proper windowing which depends on subjective assessment so that stenosis could be under- or over-estimated due to intra- and inter-observer variation. These limitations are also described in literature.<sup>5</sup>

The creation of 2-D and 3-D images reformatted from the original axial CT data set can help to overcome these limitations. Such images also offer other potential advantages, including the following: improved diagnostic confidence of interpretation; enhanced communication among radiologists, clinicians, and patients; improved pre-procedural planning; and reduction of a large axial CT data set to a few images. However, it is important to recognize that 2-D and 3-D images do not actually provide or create new information from the original axial CT data set. Rather, they offer a complementary way of viewing the same data. The axial images are the gold standard of images and remain an important point of reference for optimal interpretation.<sup>5</sup> They also assist the recognition of artifacts from motion or retained secretions.

CT scan for visualising the airways is usually carried out without IV contrast, but intravenous contrast may be used if mediastinal mass or lymphadenopathy or vascular anomaly is suspected, causing extrinsic impression on the trachea or bronchi. IV contrast was used in one case in which extraluminal pathology was suspected. This was in agreement with a study<sup>6</sup> which stated that the use of IV contrast agents is not necessary for imaging the airway unless there is a suspected paratracheal abnormality such as enlarged lymph nodes or a thyroid mass.

With regard to the phase of respiration for imaging, CT scanning of the airway is routinely obtained at end-inspiration during a breath-hold. Additional imaging sequences obtained during dynamic breathing or at end-expiration can be helpful in the assessment of tracheomalacia.<sup>7</sup> In our study, it was not possible to use such techniques in this age group.

Two different methods for 2-D reformation were used in our study. The first one was multiplanar reconstructions (MPR) which are single-voxel-thick sections that may be displayed in the coronal and sagittal planes, orthogonal to a point of reference, or in a curved fashion along the axis of the airway. The second method was multiplanar volume reconstructions (MPVR) which comprise a thick slab of adjacent thin slices and represent a block of contiguous MPR images. These techniques were also described by earlier studies<sup>8</sup> which stated that 2-D images were the easiest reformations to generate and could be interactively performed in real-time at the CT scanner console. Unlike 3-D reconstructions, they do not require the transfer of data to a separate workstation.

Besides, 2-D reformation images performed along

the axis of the airway offer the advantage of quickly displaying the Regional extent of a stenosis on a single image. A review of such images can aid pre-procedural planning prior to surgery. Despite this advantage, MPR and MPVR showed poorer results with over- or underestimation of stenosis compared to VE or conventional endoscopy. This belongs to the need of proper windowing which was subjective. This observation is also available in literature.<sup>9</sup>

There are two basic types of 3-D reconstruction images of the airway, involving internal and external rendering. Both types involve post-processing of CT scan data at a 3-D workstation. Internal rendering, also referred to as virtual endoscopy, provides an intraluminal perspective. This method combines helical CT data and virtual reality computing techniques to allow the viewer to navigate through the airways in a fashion similar to that of conventional endoscopy.<sup>10</sup>

External 3-D rendering of the airways also referred to as Tissue Transition Projection, TTP, or as virtual double contrast depicted the external surface of the airway and its relationship to adjacent structures. This method improves the detection of subtle airway stenosis and help in the assessment of complex airway abnormalities. These images also depict the craniocaudal extent of airway stenosis with a higher level of accuracy than axial images. These findings were also reported by earlier studies which found that 3-D external rendered images provided important supplemental information by enabling a more precise evaluation of the shape, length and/or degree of the airway stenosis.<sup>11</sup>

Inner-surface reconstruction calculated from helical CT data sets offers a new diagnostic option for upper airway assessment. Using special software, it is possible to create a continuous overview on the inner surface of hollow viscera on a monitor, similar to an endoscopic view<sup>12</sup> and is called Virtual bronchoscopy, which is a novel computed tomography (CT) based imaging technique that allows non-invasive intraluminal evaluation of the tracheobronchial tree. Several studies have shown that virtual bronchoscopy can accurately show the lumen and diameter of trachea, the left and right main stem bronchi and down to the fourth order of the branches and bronchial orifices.<sup>13</sup> Morphology of the carina can be evaluated accurately and the images look similar to those seen with Fibreoptic bronchoscopy (FB).

According to the results of this study, VE was the most sensitive in lesion detectability (98%), followed by external 3D volume rendering (96%). Axial images were the least sensitive. Our results are comparable with a study,<sup>14</sup> where the accuracy of axial CT images was 96%, while accuracy of coronal and sagittal reconstructions was 96% and 96.5%. When virtual bronchoscopy was performed the

accuracy was increased to 98%. This high level of accuracy in the assessment of location and the extent of lesion is further confirmed by other recent studies as well.<sup>15</sup>

In our study, the airway assessment by VE revealed stenosis in 6 cases (1 tracheal atresia, 4 subglottic stenosis and 1 tracheal stenosis) which were confirmed by conventional endoscope. The technique not only depicts the site of stenosis, but also the craniocaudal extent (length), width of the lesion and visualization of the undersurface of the lesions.<sup>15</sup> In addition, effects of stenosis on lungs distally can also be observed at the same time like atelectasis, hyperinflation, air trapping or mucous plugging.<sup>16</sup> One of the greatest advantages of virtual over conventional endoscopy is viewing the airway beyond the site of the stenosis, which enables one not only to rule out any synchronous lesion distally but VE-enabled accurate definition and assessment of all fixed airway lesions.

Virtual bronchoscopy is also useful in visualising external compression on the bronchial wall not involving the mucosa. These compressions can be due to extraluminal tumour, enlarged lymph node or fibrotic mass.<sup>17</sup>

Considering the upper airway, CT virtual endoscopy of the nasopharynx from a posterior view provides visualisation of the eustachian tube openings in reference to the choanae and nasopharyngeal walls; an area difficult to appreciate with conventional CT.<sup>18</sup> In addition to delineating normal anatomy, CT and VE are valuable in defining the type and extent of the disease.

In this study, 11 patients had 16 choanal lesions; 9 were choanal atresia (4 patients had bilateral atresia and one had unilateral); and 7 were choanal stenosis (one patient had bilateral stenosis and five patients had unilateral disease). The study showed that compared to choanal stenosis, choanal atresia was relatively more common. These findings are in agreement with earlier studies.<sup>19</sup> Bilateral choanal atresia in the neonate is a medical emergency that should be treated as early as possible. CT is a valuable and easily accessible diagnostic tool in this regard.

Once choanal atresia or stenosis has been diagnosed, transnasal surgical treatment of congenital choanal atresia is difficult. A limited view to the surgical field often accounts for poor results. An occurrence of a re-stenosis is frequently observed, requiring difficult revision surgery. CT-guided surgical planning considerably improves the treatment outcome.<sup>22</sup>

In this study one patient with tracheomalacia was missed on VE which was diagnosed by conventional bronchoscopy due to the dynamic nature of the disease. This weakness of static virtual bronchoscopy can be overcome by the paired end-inspiratory and dynamic expiratory Multi-

detector computed tomography (MDCT) imaging along with newer cine CT methods in both adult and paediatric patients. This technique could not be performed in our case due to lack of cooperation.<sup>7,23</sup>

Among the disadvantages of virtual bronchoscopy is its inability to depict mucosal changes and subtle mucosal lesions are currently missed which necessitates the performing of conventional bronchoscopy.<sup>18</sup> Besides, virtual bronchoscopy is unable to perform therapeutic procedures, like foreign body removal, although it can diagnose the presence of foreign body like in the current study where two patients were diagnosed to have foreign body on virtual bronchoscopy which was confirmed afterwards on conventional bronchoscopy. Although foreign body removal cannot be achieved by virtual bronchoscopy, but its main application lies in providing the exact location of the suspected foreign body, guiding the conventional endoscope. However, it fails to disclose the exact nature of the lesion.<sup>19</sup>

Pre-procedure virtual bronchoscopic guides conventional bronchoscope, while transbronchial biopsy increases the success rate of the biopsies, specially for peripheral lesions and lesions that are not visible while bronchoscopy or are neither involving the mucosa nor distorting the airways. The success rate of transbronchial biopsy for lesions that are visible during the procedure is 94%, but it falls to 50% for lesions that are not visible.<sup>24,25</sup>

Diagnostic sensitivity of virtual bronchoscopic-guided transbronchial biopsy for peripheral lesions of more than 30mm is 90% and for lesions less than 30mm, it is 79%.<sup>26</sup>

## Conclusion

Helical CT with 3D evaluation was accurate in assessing the length, width and shape of all stenosis in the study. It was useful in the diagnosis, measurement, definition and pre-operative planning of airway stenosis. Images proved to be efficient and can replace the conventional endoscopy, permitting a reliable endoluminal 3D view and evaluation of the surrounding anatomical structures. Despite its limitations, virtual endoscopy can provide valuable pre-procedural guidance.

## Acknowledgement

The author is grateful to Dr Ahmad Haroon, Consultant Radiologist, Department of RP Medicine and Pulmonology, Al-Noor Specialist Hospital, Makkah, Saudi Arabia.

## References

1. Hoppe H, Dinkel HP, Walder B, von Allmen G, Gugger M, Vock P. Grading airway stenosis down to the segmental level using virtual bronchoscopy.

- Chest 2004; 125: 704-11.
2. Klingenbeck-Regn K, Schaller S, Flohr T, Ohnesorge B, Kopp AF, Baum U. Subsecond multi-slice computed tomography: basics and applications. *Eur J Radiol* 1999; 31: 110-24.
  3. Pracy R. Congenital diseases of the larynx. In: Scott-Brown WG, Ballantyne JC, Groves J, editors. *Scott-Brown's Diseases of the ear, nose, and throat*. London: Butterworths; 1979; pp 309-28.
  4. De Wever W, Vandecaveye V, Lanciotti S, Verschakelen JA. Multidetector CT-generated virtual bronchoscopy: an illustrated review of the potential clinical indications. *Eur Respir J* 2004; 23: 776-82.
  5. Salvolini L, Bichi Secchi E, Costarelli L, De Nicola M. Clinical applications of 2D and 3D CT imaging of the airways--a review. *Eur J Radiol* 2000; 34: 9-25.
  6. Naidich DP, Gruden JF, McGuinness G, McCauley DI, Bhalla M. Volumetric (helical/spiral) CT (VCT) of the airways. *J Thorac Imaging* 1997; 12: 11-28.
  7. Gilkeson RC, Ciancibello LM, Hejal RB, Montenegro HD, Lange P. Tracheobronchomalacia: dynamic airway evaluation with multidetector CT. *AJR Am J Roentgenol* 2001; 176: 205-10.
  8. Quint LE, Whyte RI, Kazerooni EA, Martinez FJ, Cascade PN, Lynch JP, 3rd, et al. Stenosis of the central airways: evaluation by using helical CT with multiplanar reconstructions. *Radiology* 1995; 194: 871-7.
  9. Rapp-Bernhardt U, Welte T, Doehring W, Kropf S, Bernhardt TM. Diagnostic potential of virtual bronchoscopy: advantages in comparison with axial CT slices, MPR and mIP? *Eur Radiol* 2000; 10: 981-8.
  10. Hopper KD, Iyriboz AT, Wise SW, Neuman JD, Mauger DT, Kasales CJ. Mucosal detail at CT virtual reality: surface versus volume rendering. *Radiology* 2000; 214: 517-22.
  11. Remy-Jardin M, Remy J, Artaud D, Fribourg M, Duhamel A. Volume rendering of the tracheobronchial tree: clinical evaluation of bronchographic images. *Radiology* 1998; 208: 761-70.
  12. Rodel R, Rodenwaldt J, Hommerich CP. [Inner surface imaging of laryngeal and tracheal stenosis by spiral-CT: role of a new diagnostic procedure]. *Laryngorhinootologie* 2000; 79: 584-90.
  13. Polverosi R, Vigo M, Baron S, Rossi G. [Evaluation of tracheobronchial lesions with spiral CT: comparison between virtual endoscopy and bronchoscopy]. *Radiol Med* 2001; 102: 313-9.
  14. Hoppe H, Walder B, Sonnenschein M, Vock P, Dinkel HP. Multidetector CT virtual bronchoscopy to grade tracheobronchial stenosis. *AJR Am J Roentgenol* 2002; 178: 1195-200.
  15. Grenier PA, Beigelman-Aubry C, Brillet PY. Nonneoplastic tracheal and bronchial stenoses. *Radiol Clin North Am* 2009; 47: 243-60.
  16. Yedururi S, Guillerman RP, Chung T, Braverman RM, Dishop MK, Giannoni CM, et al. Multimodality Imaging of Tracheobronchial Disorders in Children. *Radiographics* 2008; 28: e29.
  17. Fleiter T, Merkle EM, Aschoff AJ, Lang G, Stein M, Gorich J, et al. Comparison of real-time virtual and fiberoptic bronchoscopy in patients with bronchial carcinoma: opportunities and limitations. *AJR Am J Roentgenol* 1997; 169: 1591-5.
  18. Finkelstein SE, Summers RM, Nguyen DM, Stewart JH, Tretler JA, Schrupp DS. Virtual bronchoscopy for evaluation of malignant tumors of the thorax. *J Thorac Cardiovasc Surg* 2002; 123: 967-72.
  19. Sodhi KS, Aiyappan SK, Saxena AK, Singh M, Rao K, Khandelwal N. Utility of multidetector CT and virtual bronchoscopy in tracheobronchial obstruction in children. *Acta Paediatr* 2010; 99: 1011-5.
  20. Thomas BP, Strother MK, Donnelly EF, Worrell JA. CT virtual endoscopy in the evaluation of large airway disease: review. *AJR Am J Roentgenol* 2009; 192: S20-30; quiz S1-3.
  21. Petkovska L, Petkovska I, Ramadan S, Aslam MO. CT evaluation of congenital choanal atresia: our experience and review of the literature. *Australas Radiol* 2007; 51: 236-9.
  22. Westendorff C, Dammann F, Reinert S, Hoffmann J. Computer-aided surgical treatment of bilateral choanal atresia. *J Craniofac Surg* 2007; 18: 654-60.
  23. Lee KS, Boiselle PM. Update on multidetector computed tomography imaging of the airways. *J Thorac Imaging* 2010; 25: 112-24.
  24. Martini N, McCormick PM. Assessment of endoscopically visible bronchial carcinomas. *Chest* 1978; 73(5 Suppl): 718-20.
  25. Vining DJ, Liu K, Choplin RH, Haponik EF. Virtual bronchoscopy. Relationships of virtual reality endobronchial simulations to actual bronchoscopic findings. *Chest* 1996; 109: 549-53.
  26. Iwano S, Imaizumi K, Okada T, Hasegawa Y, Naganawa S. Virtual bronchoscopy-guided transbronchial biopsy for aiding the diagnosis of peripheral lung cancer. *Eur J Radiol* 2011; 79: 155-9.
-