

# Graft Versus Host Disease Following Blood Transfusion During Coronary Artery Bypass Grafting

Pages with reference to book, From 279 To 281

Tahir S. Shamsi, Serajuddaula Syed ( Departments of Haematology and Bone Marrow Transplantation and Pathology, Ziauddin Medical University Hospital, Karachi. )

Mohammad Rehman ( Department of Cardiac Surgery, Orthopaedic and Medical Institute, Karachi. )

Javed Kazi ( Department of Pathology, Sindh Institute of Urology and Transplantation, Karachi. )

Transfusion associated graft versus host disease (TA-GVHD) is an uncommon but fatal complication of blood transfusion and is characterised by fever, skin rash, bone marrow hypoplasia, liver impairment and diarrhoea. Typically, it develops 7-14 days following blood transfusion in an immunocompromised recipient but occasionally it has been reported in immunocompetent patients<sup>1</sup>. The development of TA-GVHD depends upon the number of viable T lymphocytes transfused from the donor to the recipient. In immunocompetent recipients, it is associated with HLA homozygosity of the donor; recipient being heterozygous for that particular antigen<sup>2</sup>. Its exact incidence is unknown but seems to be higher in countries where shared haplotypes are common. We describe two cases of TA-GVHD following blood transfusion from first degree relatives during coronary artery bypass grafting (CABG).

## Case 1

A 62 years male had a CABG operation performed for ischaemic heart disease during which he received 3 units of whole fresh blood donated by his first degree relatives. He made an unremarkable recovery and was discharged from the hospital on 10th day following the operation with a normal blood count and biochemical profile. He did not have any relevant drug history or known skin disorder. Three days later, he became pyrexial and developed a rash on his abdomen. He was readmitted to the hospital with a temperature of 101°F, a generalised erythematous rash, jaundice and diarrhoea. On admission, he was pancytopenic with a haemoglobin of 10 g/dl, white cell count  $0.2 \times 10^9/l$ , platelet count  $1 \times 10^9/l$ , total bilirubin 5.6 mg/dl, SGPT 760 iu, alkaline phosphatase 440 iu. Renal functions and electrolytes were normal. Blood and urine cultures were taken on admission did not grow any organism.

A diagnosis of transfusion associated graft versus host disease was made. An urgent bone marrow aspiration and skin biopsy was carried out to confirm the clinical diagnosis. High dose methylprednisolone, GM-CSF, piperacillin and ceftazidime were started. Bone marrow aspiration showed marked bone marrow hypoplasia and increased number of macrophages showing haemophagocytic activity as shown in Figure 1.

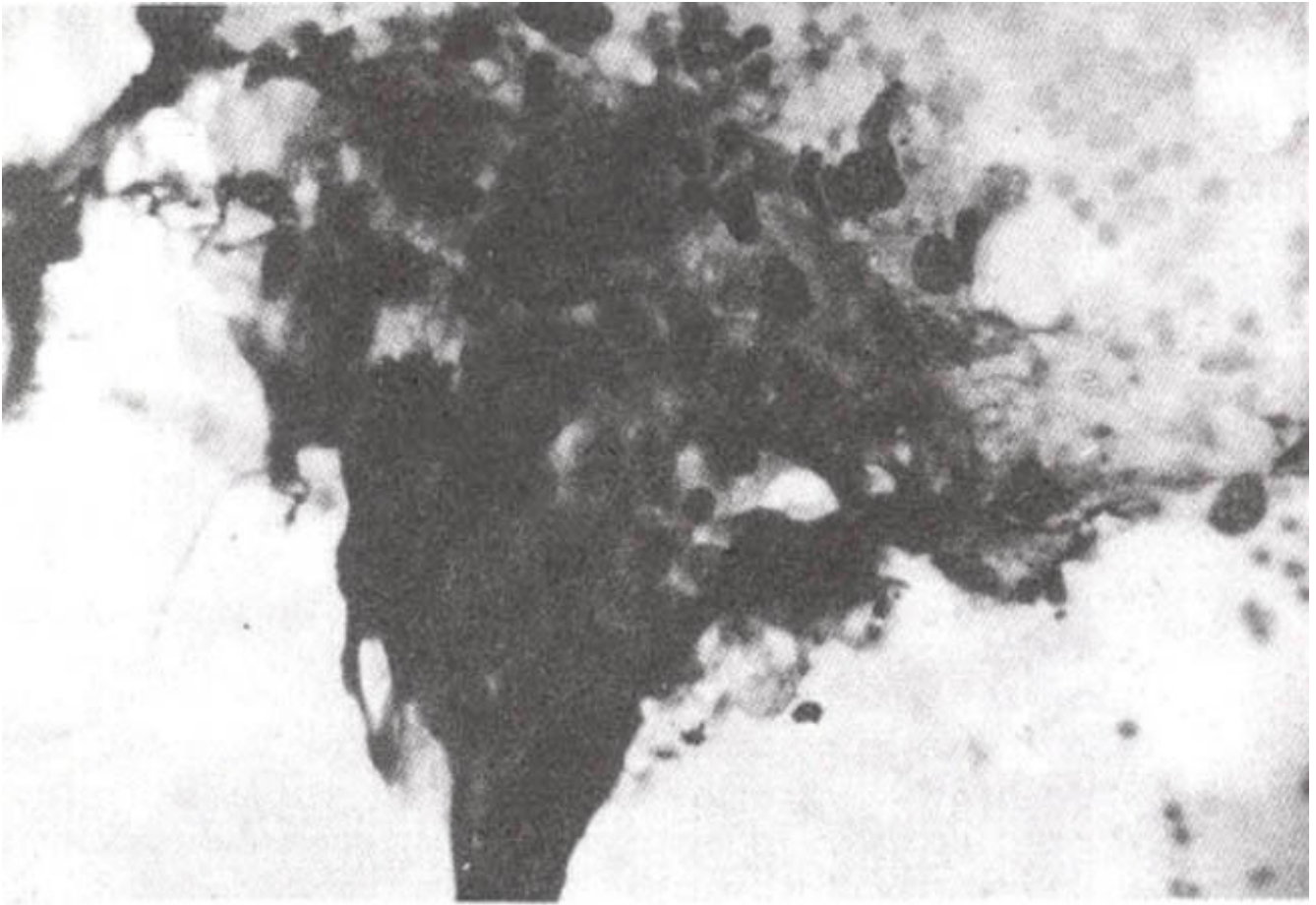


Figure 1. Bone marrow fragment shows hypocellularity and clusters of macrophages involved in haemophagocytosis.

Skin biopsy showed eosinophilic keratin bodies, satellite cell necrosis, dermo-epidermal clefts, a sparse mononuclear cell infiltration and marked dermal collagenisation as shown in Figure 2.

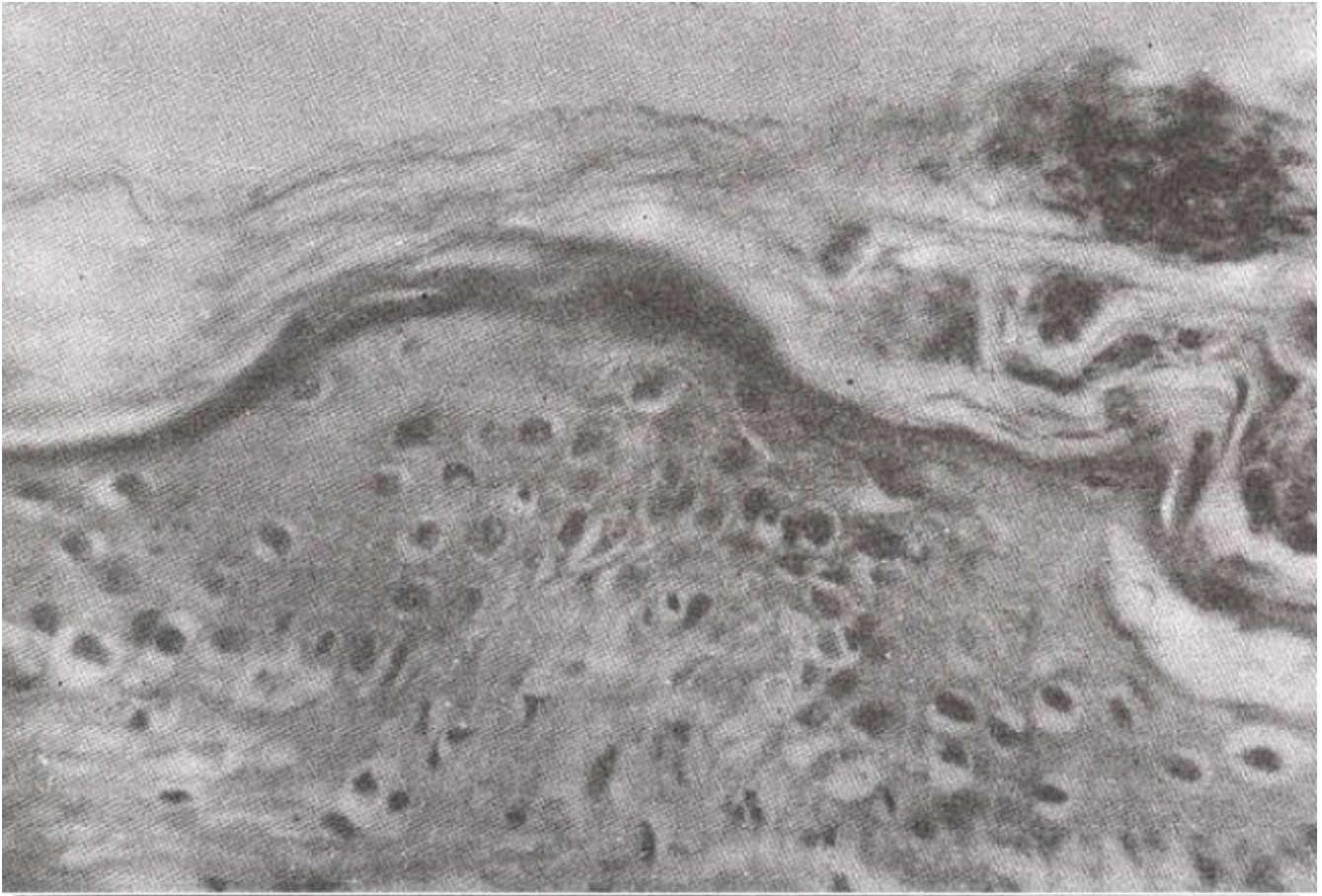


Figure 2. Histology of skin shows eosinophilic keratin bodies, dermo-epidermal clefts and satellite cell necrosis.

During next 24 hours, he developed multi-organ failure and was put on to a ventilator but he continued to deteriorate and died.

## Case 2

A 59 years old male had a CABG operation performed for ischaemic heart disease. During the operation, he was transfused 4 units of fresh whole blood, 2 of them were donated from his sons while the other 2 were from professional donors. Postoperatively, he made an unrecoverable recovery and was discharged on the 9th postoperative day.

On the day of discharge, he was well apart from a rash which was noted on his hands and feet. His full blood count showed a haemoglobin of 11.6 gm/dl, white cell count of  $4.3 \times 10^9/l$  and a platelet count of  $2 \times 10^9/l$ . He developed fever and dyspnea a day following discharge from the hospital and the rash spread to all over his body. Twenty-four hours later, dyspnea worsened and the temperature rose to  $103^\circ F$ . He was readmitted to the hospital with high grade fever, maculopapular rash, severe shortness of breath and diarrhoea.

On examination, he was tachycardiac, his blood pressure was normal and temperature was  $102.6^\circ F$ . There was a generalised erythematous skin rash all over his body which was more pronounced on abdomen, hands and feet and he was noted to be jaundiced. His full blood count revealed pancytopenia i.e. a haemoglobin of 10 gm/dl, white cell count of  $1.1 \times 10^9/l$ , platelet count  $140 \times 10^9/l$ , total bilirubin was 3.7 mg/dl, SGPT 433 iu, alkaline phosphatase was 580 iu, urea was 110 mg/dl, creatinine was 2.8 mg/dl and a bone marrow aspirate revealed a hypocellular marrow with absent myeloid

precursors and scanty erythroid and megakaryocyte progenitors. Macrophages were present in abundance and showed pronounced haemophagocytic activity (Figure 1). Blood and urine cultures taken on admission did not grow any organism.

A diagnosis of transfusion associated graft versus host disease was suspected and high dose methylprednisolone at a dose of 1.0 gram per day was started. To control a possible infection, he was put on piperacillin and tobramycin for neutropenic fever and granulocyte macrophage colony stimulating factor (GM-CSF) to stimulate bone marrow. Twelve hours after admission, white cell count further fell to  $0.4 \times 10^9/l$ . Patient's condition deteriorated during next 24 hours and he died. Skin and liver biopsies could not be done because of the rapid downhill-course.

## Discussion

The clinical presentation of these two cases were suggestive of classical TAGVHD in immunocompetent hosts; blood transfusion from first degree relatives, onset of symptoms 7-14 days post transfusion which included erythematous rash, fever, bone marrow hypoplasia, diarrhoea, liverfunctionimpairment, multi-organfailure and fulminant course leading to death. This diagnosis was substantiated by skinbiopsy only in case 1, the secondcase clinically mimicked with TAGVHD but could not be confirmed by tissue diagnosis. Bacteriological specimen taken at the time of admission did not grow any organism, because of rapid downhill course, only one set of blood culture could be taken. Though the clinical diagnosis was made relatively early and high dose methylprednisolone was initiated within 48 hours of presentation but both patients died, within 2-3 days.

Graft versus host disease was first described in animals in 1950's when bone marrow was infused from parents to F1 hybrid mice, resulting in a syndrome of erythema, rash, jaundice and death from wasting and infections<sup>3</sup>. Classically GVHD is seen in the recipients of allogeneic bone marrow transplantation<sup>4</sup>. In humans, TAGVHD was first described in children with severe combined immunodeficiency<sup>5</sup>. Since then most cases have been reported in either congenital or acquired immunocompromised patients receiving un-irradiated blood transfusion<sup>6-11</sup>. The occurrence of TAGVHD in normal immunocompetent people was described following cardiac surgery in population groups who share common HLA haplotypes<sup>7,12-14</sup>.

The exact cause of TAGVHD is not known. In immunocompetent recipients, TAG VHD seems to occur due to HLA disparity in class I antigens; donor being homozygous for a given antigen while recipient is heterozygous<sup>12,13</sup>. Recipient recognises donor's cells as self while donor's lymphocytes recognise non-identical HLA haplotype and mount an immunological reaction leading to cellular destruction. Estimates of HLA homozygous transfusions being given to unrelated individuals for the same haplotype have been calculated to be from 1 in 1600 to 1 in 48,500 in different population groups<sup>2,12</sup>. In population groups who share common HLA haplotypes, incidence of TAGVHD is estimated to be 1 in 659 in CABG patients<sup>7</sup>. Given that 10 millions donations are transfused annually in the United States, only a handful cases are reported. This suggests either a gross under-reporting, under recognition and/or due to an unknown protective mechanism.

Early stages of TA-GVHD can not be differentiated clinically from sepsis, drug reaction or viral reaction. But a florid case is usually suspected by its clinical course. It is important to diagnose this condition clinically and differentiated from other skin conditions like Steven's Johnson syndrome. In fact we had a similar case which was diagnosed as drug induced bone marrow suppression associated with Steven's-Johnson syndrome who in retrospect might have had TA-GVHD.

Its diagnosis is confirmed by characteristic changes seen histologically in the skin and liver<sup>2,15</sup>. An important lesson to be learnt from these cases is that blood transfusion is hazardous and should be taken seriously. Only screened blood from healthy blood donors should be accepted for transfusion

which may prevent transfusion related viral transmission but this will not prevent TAG VHD. Immunosuppressed patients e.g., Hodgkin's disease, bone marrow transplant recipients, severe combined immunodeficiency patients and neonates are at particularly increased risk of this fatal condition. TAGVHD can be prevented by avoiding transfusions of directed donations from first degree relatives, use of high performance leukocyte depletion filters and irradiating blood products at a dose of 2500 cGy before transfusion in at risk patients<sup>1,2</sup>, But its treatment remains unsatisfactory and carries a mortality of more than 90%. So far high doses of intravenous steroids and cyclosporin have been used. There is only one successfully treated patient reported in the literature who was managed with monoclonal antibodies anti-OKT<sup>16</sup>.

## References

1. Anderson KC and Weinstein HJ. Transfusion associated graft versus host disease. *N. EngI. J. Med.*, 1990;323:31:5-21.
2. Wiliamson LM and Warwick RM. Transfusion-associated graft versus host disease and its prevention. *Blood transfusion*, 1995;9:25 1-61.
3. Trentin JJ. Mortality and skin transplantability in irradiated mice receiving isologous or heterologous bone marrow. *Proc. Soc. Exp. Biol. Med.*, 1956;92:688-89.
4. Hathaway WE, Githens JR, Blackburn WR et al. Aplastic anaemia, histiocytosis and erythroderma in immunologically deficient children. *N. EngI. J. Med.*, 1965;273 :953-58.
5. Thomas ED, Storb R, Clin RA et al. Bone marrow transplantation. *N. EngI. J. Med.*, 1975;292:832-902.
6. Dinsmore RE, Straus DJ, Pollack MS et al. Fatal graft versus host disease following blood transfusion in Hodgkin's disease documented by HLA typing. *Blood*, 1980;55 :832-34.
7. Juji T, Takahashi K, Shibata Yet al. Post transfusion grail versus host disease in immuno-competent patients after cardiac surgery in Japan. *N. EngI. J. Med.*, 1989;321 :56-60.
8. Spitzer TR, Cahill R, Cottler FM et al. Transfusion induced graft versus host disease in patients with malignant lymphoma. *Cancer*, 1990;66:2346-49.
9. Baglin TP, Joysey VC, Horsford Jet al. Transfusion associated graft versus host disease in patients with Hodgkin's disease and T-cell lymphoma. *Transfusion Med.*, 1992;2:195-99.
10. Maung ZT, Wood AC, Jackson GH et al. Transfusionassociated graftversus host disease in fludarabine treated B-chronic lymphocytic leukaemia. *Br. 3. Haematol.*, 1994;88:649-52.
11. Zulain GB, Roux E, Tiercy JM et al. Transfusion associated graft versus host disease in a patient treated with Cladribine (2- chlorodeoxyadenosine): demonstration ofexogenous DNA in various tissue extracts by PCRanalysis. *Br 3. Haematol.*, 1995,89:83-89.
12. Wagner FF, Flegel WA. Transfusion associated graft versus host disease: risk due to homozygous HLA haplotypes. *Transfusion.*, 1995;35:284-91.
13. Thaler M, Shamiss A, Orgad S et al. The role of blood from HLA homozygous donors in fatal transfusion associated graft versus host disease after open heart surgery. *N. EngI. 3. Med.*, 1989;321 : 25-28.
14. Shakikabara T and Juji T. Post transfusion grail versus host disease after open heart surgery. *Lancet*, 1 986;ii: 1099-1101.
15. Appleton AL, Sviland L, Pearson AD et al. Diagnostic features of transfusion associated grail versus host disease. *J. Clin. Pathol.*, 1994;47:541 -46.
16. Yasukawa M, Shinozak F, Hato T et al. Successful treatment of transfusion associated graft versus host disease. *Br. J. Haematol.*, 1994;86:83 1-36.