

Severe Hypercalcemia in Tuberculosis

A. Soofi, A. Malik, J. Khan, S. Muzaffar*

Departments of Medicine and Pathology*, The Aga Khan University, Karachi.

Introduction

Hypercalcemia is known to occur in granulomatous diseases.¹ Sarcoidosis is the most common granulomatous disease causing hypercalcemia. Tuberculosis, fungal granulomas, berylliosis and lymphomas are other conditions that are associated with disorders of calcium metabolism.² Hypercalcemia, although occurs infrequently, is a well recognized complication of active tuberculosis. Severe hypercalcemia has been rarely reported in literature. The reported incidence of hypercalcemia in TB varies widely between countries, probably because of variations in the Vitamin D and calcium intake, the amount of sun exposure and differences in study population.³ We describe here a case of severe hypercalcemia in a patient with abdominal tuberculosis.

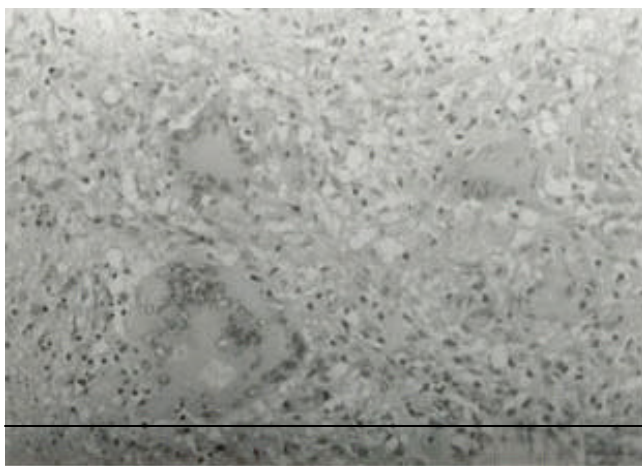
Case Report

A 55 years old male presented with low grade fever, generalized weakness, weight loss, abdominal distension and constipation for 4 months and urinary frequency for 2 months. On examination, he looked cachectic with distended abdomen. There was no peripheral lymphadenopathy. Neurological and chest examination were normal.

Abdominal examination revealed gross ascites. Laboratory workup showed normocytic normochromic anemia with a hemoglobin of 10.8 gm/dl, white blood cell count of $9 \times 10^9/L$ with normal differentials, albumin of 2.4gm/dl, corrected hypercalcemia of 15.:mg/dl, raised alkaline phosphatase (764 I.U/L) with normal parathyroid hormone level (19.7 pg/ml) and progressive renal failure. His serum creatinine rose from 0.9mg/dl two months prior

to emergency room presentation to 4.1 mg/dl three days post hospital admission. Ultrasound abdomen showed gross ascites and multiple hypochoic lesions in right lobe of liver.

Diagnostic ascitic fluid tap revealed exudative ascites (glucose 97 mg/dl, protein 5500mg/dl, leukocyte count 400/mm³ with 97% lymphocytes). Ascitic fluid smear for Acid Fast Bacilli and culture were negative. Ascitic fluid cytology did not show any malignant cells. Computed Tomography scan of abdomen showed diffuse peritoneal thickening with abdominal lymphadenopathy, irregular pleura, thickening of posterior wall of stomach, lesser curvature, antrum and omentum. Ultrasound guided trucut biopsy of peritoneum revealed chronic granulomatous inflammation. Granuloma was composed of epitheloid cells, multinucleated giant cells, plasma cells and lymphocytes (Figure).



The patient was started on rifampicin 450mg, isoniazid 300mg, ethambutol 1200mg and pyrazinamide 1500mg once daily for two months with aggressive hydration. He showed marked improvement within three weeks of therapy. His calcium and creatinine decreased to 9.1 mg/dl and 1.7mg/dl respectively. For the maintenance phase, he was continued on isoniazid and ethambutol for six months.

Discussion

Hypercalcemia is not an uncommon problem seen in medical practice. More than 90% of cases are due to primary hyperparathyroidism and malignancy. Other causes besides granulomatous diseases include vitamin D intoxication, hyperthyroidism, thiazide diuretics, lithium, milk alkali syndrome and immobilization.

The diagnosis of tuberculosis in this case was made on the presence of typical histology showing epitheloid granuloma, symptomatic hypercalcemia and improvement with antituberculous chemotherapy. A case of

hypercalcemic crisis as the presenting manifestation of abdominal tuberculosis has been described by Ramanathan et al.⁴ Our finding of rapid response of hypercalcemia to anti tuberculosis treatment is consistent with the case reported by Tan et. al. in which hypercalcemia in a patient with abdominal tuberculosis lymphadenopathy returned to normal within one month of anti-tuberculosis treatment.⁵

Hypercalcemia manifests as polyuria, polydipsia, vomiting, dehydration, constipation and mental obtundation in absence of CNS disease. ECG finding is shortened QT interval. In patients with tuberculosis, hypercalcemia is usually mild and asymptomatic.⁶ It may occur in all forms of tuberculosis - both pulmonary and extra pulmonary. The difference in serum calcium levels among different forms of tuberculosis has not been found to be statistically significant. However very high levels have been noted in patients with disseminated tuberculosis and pulmonary tuberculosis with pleural effusion. Severe hypercalcemia, as was in this case, has been infrequently reported. In a series from Hong Kong,⁷ only 2 out of 318 patients with active TB had hypercalcemia severe enough to be treated with hydration and steroids. The causes of severe hypercalcemia associated with TB quoted in literature are Vitamin D/calcium supplementation and renal failure.⁸ Our patient was not receiving any supplements so the probable cause of severe hypercalcemia in our patient was impaired renal function.

Our patient was cachectic and had hypoalbuminemia. Both, protein caloric malnutrition and hypoalbuminemia are common observations in patients with active tuberculosis. In a study done by Liam et. al., 66% of patients with active TB had hypoalbuminemia at the time of diagnosis.⁹ The reasons for this are mostly chronic ill health as a result of TB and malnutrition related to low socioeconomic background.

Regarding the mechanism of hypercalcemia, there is evidence that extra renal 1-alpha hydroxylation of 25 hydroxy cholcalciferol to 1,25 dihydroxycholecalciferol brought about by macrophages plays an important role in causing hypercalcemia in tuberculous patients.¹⁰ This 1-enzyme activity in macrophages is regulated by gamma interferon or endotoxin. It is thought that 1,25 dihydroxycholecalciferol can improve the capacity of activated macrophages to kill mycobacteria.¹¹ This activity usually has local effects to enhance all cell-mediated immunity to TB. However if produced in a large quantity, spillage may occur into circulation resulting in hypercalcemia.

Symptomatic hypercalcemia is managed by aggressive hydration and occasionally short courses of systemic corticosteroid to bring down the serum calcium level as was done in our patient.

In conclusion, we suggest that TB should be excluded in any febrile patient with hypercalcemia especially in countries where tuberculosis is endemic.

References

1. Abbasi AA, Chemplavil JK, Farah S, et al. Hypercalcemia in active pulmonary tuberculosis. *Ann Intern Med* 1979;90:324-8.
 2. Sharma OP. Hypercalcemia in granulomatous disorders: a clinical review. *Curr Opin Pulm Med* 2000;6:442-7.
 3. Davies PD, Church HA, Brown RC, et al. Raised serum calcium in tuberculosis patients in Africa. *Eur J Respir Dis* 1987;71:341-4.
 4. Ramanathan M, Abdullah AD, Sivadas T. Hypercalcaemic crisis as the presenting manifestation of abdominal tuberculosis: a case report. *Med JMalaysia* 1998;53:432-4.
 5. Tan TT, Lee BC, Zainuddin BM, et al. Hypercalcemia in a patient with tuberculous mediastinal lymphadenopathy. *Singapore Med J* 1991;32:87-9.
 6. Chan CH, Chan TY, Shek AC, et al. Severe hypercalcaemia associated with miliary tuberculosis. *J Trop Med Hyg* 1994;97:180-2.
 7. Chan TY. Symptomatic hypercalcaemia is rare in tuberculous patients in HongKong. *Ann Trop Med Parasitol* 1996;90:663-4.
 8. Yavuz H, Ozel A, Erkul I. Tuberculosis and hypercalcemia. *Pediatr Infect Dis J* 1994;13:758-9.
 9. Liam CK, Lim KH, Srinivas P, et al. Hypercalcaemia in patients with newly diagnosed tuberculosis in Malaysia. *Int J Tuberc Lung Dis* 1998;2:818-23.
 10. Vidal M, Ramana CV, Dusso AS. Statl-vitamin D receptor interactions antagonize 1,25-dihydroxyvitamin D transcriptional activity and enhance statl mediated transcription. *Mol Cell Biol* 2002;22:2777-87.
 11. Isaacs RD, Nicholson GI, Holdaway IM. Miliary tuberculosis with hypercalcaemia and raised vitamin D concentration. *Thorax* 1987;42:555-6.
-