

Extradural Extramedullary Hematopoiesis: a rare MRI Diagnosis with atypical Features

M. N. Ahmad, N. Uddin*, S. Muzaffar**, S. N. Adil**, Z. Tasneem*
Departments of Radiology, Pathology**, Intern*, Aga Khan University Hospital, Karachi.

Introduction

Extra-medullary hematopoiesis occurring in spinal epidural space with resulting cord compression is rare. We report a case of extra-medullary hematopoiesis causing thoracic spinal cord compression in a patient of myelofibrosis. Because of atypical MRI findings, it posed a significant diagnostic challenge. Therefore, we have discussed MRI features of this rare complication in correlation with relevant literature. Pathophysiology and management of this entity are also presented.

Case Report

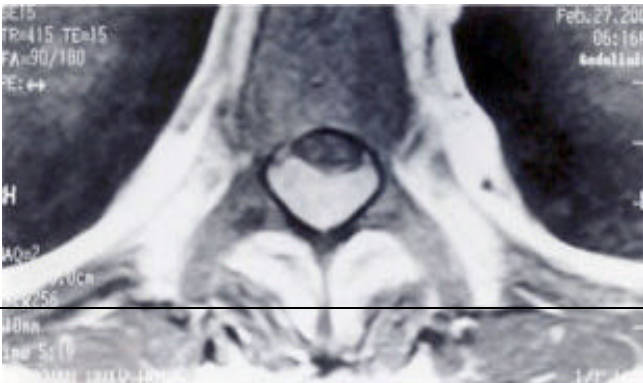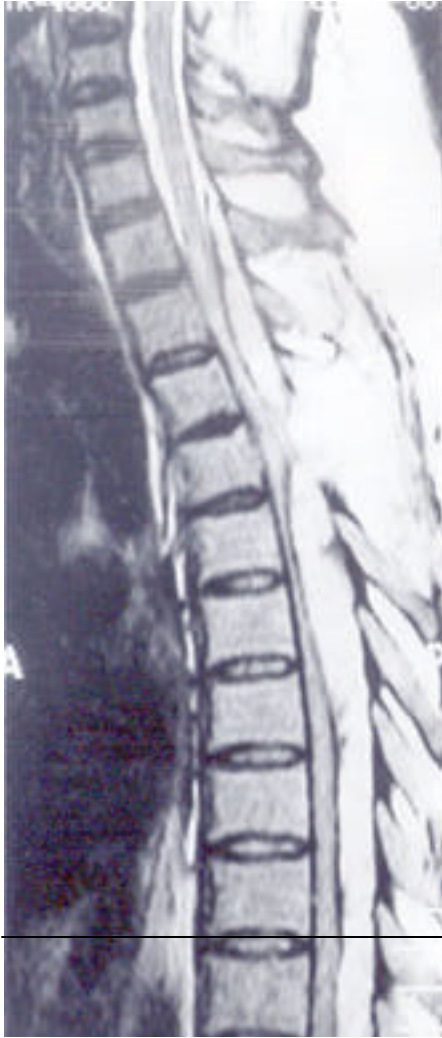A forty year old male, ex-smoker, presented with pain in lower back for six months and weakness in both legs for four months. These symptoms were progressive in nature making him unable to walk without support. He was complaining of sensory loss up to thoracic level. He had no history of fever, weight loss, jaundice, blood transfusion or trauma. Past history was significant for gouty arthritis.

On examination, he was conscious. Speech and other higher mental functions were normal. He was unable to walk without support. There was decreased bulk and strength of both legs with 2/5 power proximally and distally. Reflexes were exaggerated and Babinski's sign was positive. He also had decrease sensation up to T4 dermatome. Upper limbs were normal and rest of the examination was unremarkable. Laboratory investigations revealed hemoglobin of 129 g/l (130-180 g/l), Red blood cell count was $4.9 \times 10^{12}/l$ ($4.5-6.5 \times 10^{12}/l$), Hematocrit 0.40 (0.40-0.54), MCV 90.7 fl (76-100 fl), MCH 26.1 pg (27-32 pg) and WBC count $10.9 \times 10^9/l$ ($4.0-11.0 \times 10^9/l$) with $8.06 \times 10^9/l$ (74 %) polymorphs ($2.0-7.9 \times 10^9/l$). Peripheral blood smear was notable for leucoerythroblastic

picture showing nucleated RBCs, occasional polychromatic cells, myelocytes and metamyelocytes. X-ray chest was normal. X-ray spine showed loss of normal lumbar curve, lumbar osteophytes and spurs. There was no fracture, lysis or bony contusion. Para-vertebral soft tissues were normal. Pedicels of L5 shows hazy appearance and margins were not clearly defined.

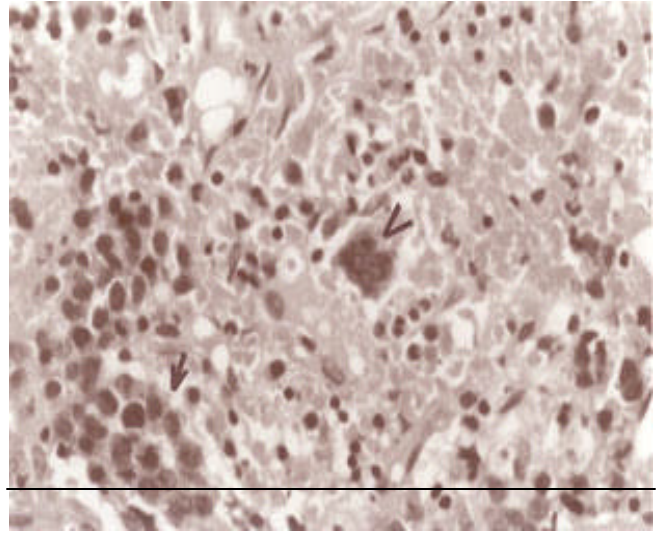
The MRI examination demonstrated an extra-dural linear mass on the posterior aspect of spinal cord, causing significant compression of the dorsal spinal cord especially at the level of C5-C6. It was extending approximately from the disk of C7/T1 down to D12/L1 level. The mass was isointense to the spinal cord on the T1 weighted pulse sequences without contrast, but on T2 weighted sequences it was hyperintense (Figure 1). After contrast injection, the mass appeared to be diffusely intense and enhancing, indicating this to be cellular in nature and not in favor of blood or abscess (Figure 2). The vertebral body bone marrow signals were reduced, generally, indicating possible bone marrow infiltration or significant red marrow conversion. There was no evidence of pre-or para-vertebral mass.

Based on clinical and radiological findings the diagnosis of spinal cord compression by a mass possibly lymphoma or extra-dural hematopoiesis was suggested. However, absence of a pre- or para- vertebral mass made the diagnosis of extradural extramedullary hematopoiesis, questionable. He received high dose steroids and spinal laminectomy was done at T1-T2 level; it revealed a bleeding & reddish colored mass. On histopathological examination it turned out to be an extramedullary hematopoietic tissue, because it exhibited both erythroid and myeloid cell lines. Megkaryocytes were also identified. There was no evidence malignancy or granuloma formation (Figure 3).



To diagnose the underlying condition, causing extramedullary hematopoiesis, a bone marrow examination was performed. The marrow findings were consistent with the picture of myelofibrosis because of increase fibrosis with very few normal erythroid and myeloid precursors. Reticulin staining showed marked increase in Reticulin fibers.

Correlating all the information and investigations a



final diagnosis of myelofibrosis causing extra-dural extramedullary hematopoiesis culminating in spastic paraparesis because of cord compression, was made. For the treatment of neurological deficit he was referred for radiotherapy.

Discussion

Extension of marrow through and beyond its bony encasement is called extra-medullary hematopoiesis (EMH). It occurs as a response to chronic hematological stress. The most frequent sites of EMH include spleen, liver and kidney; less commonly, heart, lymph nodes, thymus or adrenal glands and pre or para-vertebral spaces are involved.¹ EMH afflicting the epidural space and resulting in spinal cord compression is rare.² The first description of spinal cord compression caused by EMH was published in 1954³ and 75 cases have been reported in literature yet.⁴ However, less than 10 cases of EMH had only spinal involvement without effecting the usual sites and presenting as paraparesis, similar to our case. Although the most reported patients of EMH in epidural space are thalassaemic⁵, it has been described in other chronic anemias such as sickle cell anemia⁶ and sideroblastic anemia⁷, as well as in myeloproliferative disorders like polycythaemia vera⁸, myelofibrosis⁹ and myelodysplastic syndrome.¹⁰ Other conditions causing spinal EMH includes chronic eosinophilic leukemia, hepatocellular carcinoma and Paget's disease.¹¹⁻¹³

The most frequent site of epidural involvement is in the thoracic region.^{2,9} According to some it may be because of the narrow diameter of spinal cord in this region¹⁴ but other authors describe that the reasons are not completely understood.^{2,15} Similarly, the source of epidural hematopoietic tissue is also controversial. Some studies hypothesize it as an extension of blood forming elements through weakened trabecular bone in to epidural

compartment.⁵ This is supported by reports of radiological continuation of epidural masses and intramedullary marrow.⁵ Others propose that these hematopoietic tissues arise from the rests of primitive blood forming precursors present particularly in the thoracic epidural space.^{9,16}

MRI is the gold standard and technique of choice in the evaluation of this condition.^{4,10} Before MRI, Computer tomography (CT) and/or CT Myelography were in use.¹⁷ MRI findings of spinal EMH, reported previously, include higher signal intensity to both spinal cord and adjacent vertebral marrow on T1 weighted, spin echo and T2 weighted sequences whilst contrast enhancement is variable.¹⁸ However in the case report of EMH due to a specific sub-type of myelodysplastic syndrome, the mass appeared hypo-intense on T2 images which may be attributed to excessive iron deposition.¹⁰ In our case the mass was Iso-intense to the cord on T1 weighted sequences but on T2, it was hyper-intense (Figure 1). The variation in signal intensity of the mass on T1 can be attributed to the relative proportions of fat and water. Because Yellow marrow, by virtue of its increased fat content is hyperintense on T1 weighted images. Whereas red marrow demonstrates low signal intensity reflecting increased water content.¹⁹ Contrast enhancement on T1 sequences was also noted (Figure 2). Initially it appeared as epidural lymphoma because epidural lymphoma is iso-intense to the cord on T1 weighted images²⁰ and slightly hyper-intense on T2 weighted sequences while contrast enhancement is variable.¹⁸ Therefore, it was difficult to precisely differentiate between the two based on MRI alone. In addition, the absence of a pre and para-vertebral mass made the diagnosis of EMH, doubtful. Biopsy eventually made the final diagnosis.

Treatment of spinal cord compression due to EMH is controversial.^{10,18} Surgery, Radiotherapy, Blood transfusions and Hydroxy Urea are used in different combinations.^{5,10,15,17,21}

In conclusion, EMH is a differential diagnosis of Spinal cord compression and should be suspected in the patients with chronic anemia, myeloproliferative disorders and thalassemia. Although most cases demonstrate typical features on MRI, there are reported deviations, like the one presented here. This can pose a significant diagnostic challenge in the settings where timely detection and treatment of the disease is crucial.

References

1. Close AS, Taira Y, Cleveland DA. Spinal cord compression due to extramedullary hematopoiesis. *Ann Intern Med* 1958;48:421-27
2. Kalina P, Hillstrom MM. MR of extramedullary hematopoiesis causing cord compression in Beta-Thalassemia. *Am J Neuroradiol* 1992;13:1407-9.
3. Gatto I, Terrana V, Biondi L. Compressione sul midollo spinale da proliferazione di midollo osseo nello spazio epidurale in soggetto affetto da malattia di Cooley splenectomizzato [Compression of the spinal cord from proliferation of bone marrow in the epidural space in patient affected from Cooley's splenectomy]. *Haematologica* 1954;38:61-76.
4. Rey J, Gagliano R, Christides C, et al. Compression medullaire par des foyers d'hematopoiese extra medullaire au cours de la thalassemie. [Spinal cord compression caused by extramedullary hematopoiesis foci in the course of thalassemia]. *Presse Med* 2001;30:1351-3.
5. Pantongrag-Brown L, Suwanwela N. Case report: chronic spinal cord compression from extramedullary hematopoiesis in thalassemia - MRI findings. *Clin Radiol* 1992;46:281-3.
6. Lewkow LM, Shah I. Sick cell anemia and epidural extramedullary hematopoiesis. *Am J Med* 1984;76:748-51.
7. Haffez DS, Sawaya R, Udvarhelyi GB, et al. Spinal epidural extramedullary hematopoiesis with cord compression in patient with refractory sideroblastic anemia. *J Neurosurg* 1982;57:399-406.
8. Kalina P, Zaheer W, Drehobl K. Cord compression by extramedullary hematopoiesis in polycythaemia vera. *Am J Radiol* 1995;164:1027-28.
9. Cook G, Sharp RA. Spinal cord compression due to extramedullary hematopoiesis in myelofibrosis. *J Clin Pathol* 1994;47:464-5.
10. Dibbern DA Jr, Loevner LA, Lieberman AP, et al. MR of thoracic cord compression caused by epidural extramedullary hematopoiesis in myelodysplastic syndrome. *Am J Neuroradiol* 1997;18:363-6.
11. Julien J, Broustet A, Trojani M, et al. Compression de la moelle epiniere par un foyer de myelopoiese dans l'espace epidural au cours d'une leucemie a forte composante eosinophile. [Spinal cord compression by extramedullary hematopoiesis in chronic eosinophilic leukemia]. *Sem Hop* 1981;57:598-600.
12. O'Connor JF, Levinthal GN, Sheets R, et al. Spinal extramedullary hematopoiesis secondary to hepatocellular carcinoma: case report and literature review. *J Clin Gastroentrol* 1997;25:466-9.
13. Ducloux JM, Maugars Y, Moreau A, et al. Hematopoiese extramedullaire. Une cause singuliere de compression medullaire pagetique. [Extramedullary hematopoiesis. An unusual cause of Pagetic spinal cord compression]. *Rev Rhum. Ed Fr* 1993;60:23-7.
14. Heffner RR, Koehl RH. Hematopoiesis in the spinal epidural space. *J Neurosurg* 1970;32:485-8.
15. Lau SK, Chan CK, Chow YYN. Cord compression due to extramedullary hematopoiesis in a patient with thalassemia. *Spine* 1994;19:2467-70.
16. Amirjamshidi A, Abbassioun K, Ketabchi SE. Spinal extradural hematopoiesis in adolescents with thalassemia. *Childs Nerv Syst* 1991;7:223-5.
17. Papavasiliou C, Gouliamos A, Vlahos L, et al. CT and MRI of symptomatic spinal involvement by extramedullary hematopoiesis. *Clin Radiol* 1990;42:91-2.
18. Alorainy IA, Al-Asmi AR, del-Carpio R. MRI features of epidural extramedullary hematopoiesis. *Eur J Radiol* 2000;35:8-11.
19. Stoller DW, Steinkirchner TM, Porter BA. Marrow images. In: Stoller, D.W., eds. *MRI in Orthopedics and Sport Medicine*. 2nd ed. Philadelphia: Lippincott-Raven, 1997, pp. 1163-229.
20. Boukobza M, Mazel C, Touboul E. Primary vertebral and spinal epidural non-Hodgkin's lymphoma with spinal cord compression. *Neuroradiology* 1996;38:333-7.
21. Konstantopoulos K, Vagiopoulos G, Kantouni R., et al. A case of spinal cord compression by extramedullary hematopoiesis in a thalassaemic patient: a putative role for hydroxyurea? *Haematologica* 1992;77:352-4.