

Evaluation of Urethrovesical Junction Mobility by Perineal Ultrasonography in Stress Urinary Incontinence

Pages with reference to book, From 2 To 5

Fuat Demirci, Umur Kuyumcuoglu, Melunet Uludogan, Husnu Gorgen, Zeki Sahinoglu, M. Nuri Delikara (Zeynep Kamil Women and Children Hospital, Department of Obstetric and Gynaecology, Uskudar, Istanbul, Turkey.)

Abstract

Perineal ultrasonographic measurements of the cephalocaudal and the ventrodorsal components of urethro-vesical junction (UVJ) movement at rest and stress was performed in 35 patients of stress urinary incontinence (SUI) and 20 continent controls. The cephalocaudal distance of UVJ from the pubis at rest position was almost similar in both continent and incontinent groups, but there was significant difference during stress. The cephalocaudal mobility and the ventrodorsal distance from the pubis was markedly different between the two groups, both at rest and during stress. However, the ventrodorsal mobility was similar in both groups. It is concluded that the UVJ mobility of SUI cases was higher on the cephalocaudal axis than the ventrodorsal axis. The distance between UVJ and the pubis was more on the ventrodorsal axis as compared to the control group and UVJ passed down the pubic symphysis in 63% of SUI cases during stress (JPMA 46:1, 1996).

Introduction

Stress urinary incontinence (SUI) is a condition defined as involuntary passage of urine during stress. It is more common in parous women and leads to hygienic and social problems. It is secondary to inefficient conduction of intra-abdominal pressure to hypermobile urethro-vesical junction (UVJ) due to weakened supportive tissues^{1,2}.

UVJ makes a rotational movement during stress both on ventro-dorsal and cephalo-caudal axis.

Evaluation of the anatomical situation and the degree of mobility has been performed by Q-tip test³, lateral cystourethrograph^{4,5}, videourethrocytography⁶ and more recently by perineal^{5,7-9}, transvaginal¹⁰⁻¹³, and transrectal^{14,15} ultrasonography, which are reliable and relatively safe methods since neither x-ray nor any contrast material is needed.

Perineal ultrasonography provides a more topographical view and is superior to the transvaginal and transrectal approach since it is easy to apply and it is not affected by movement during stress.

Patients and Methods

Thirty-five diagnosed but unoperated cases of stress urinary incontinence (SUI) were included in the study. Twenty additional cases hospitalized for gynecological problems other than SUI (pelvic tumor, myoma uteri, abnormal uterine bleeding) and similar to the study group in age, parity and weight were studied as controls.

In order to evaluate the UVJ by ultrasound, a 14 French Foley catheter was passed in each patient in a dorsolithotomy position. The balloon of the catheter and the urinary bladder were filled with 0.9% NaCl solution, 5 ml and 300 ml respectively. A 3.5 MHz probe of a Hitachi EUB 305 ultrasound machine covered with a sterile glove was placed on the sagittal axis of the perineum after sterile gel application. The image was frozen and placed on one side of the screen when the inferior edge of the symphysis pubis, the bladder, UVJ and the urethra were visualized. Then the patient was asked to strain and again the image was frozen and placed on the other half of the screen. The intersection point of

coronal plane passing through the UVJ detemuned by the Foley catheter and the horizontal plane passing below the symphysis pubis was marked during rest and stress positions and the distance in between was measured by the same operator both as cephalocaudal and ventrodorsal components (Figures 1 and 2).

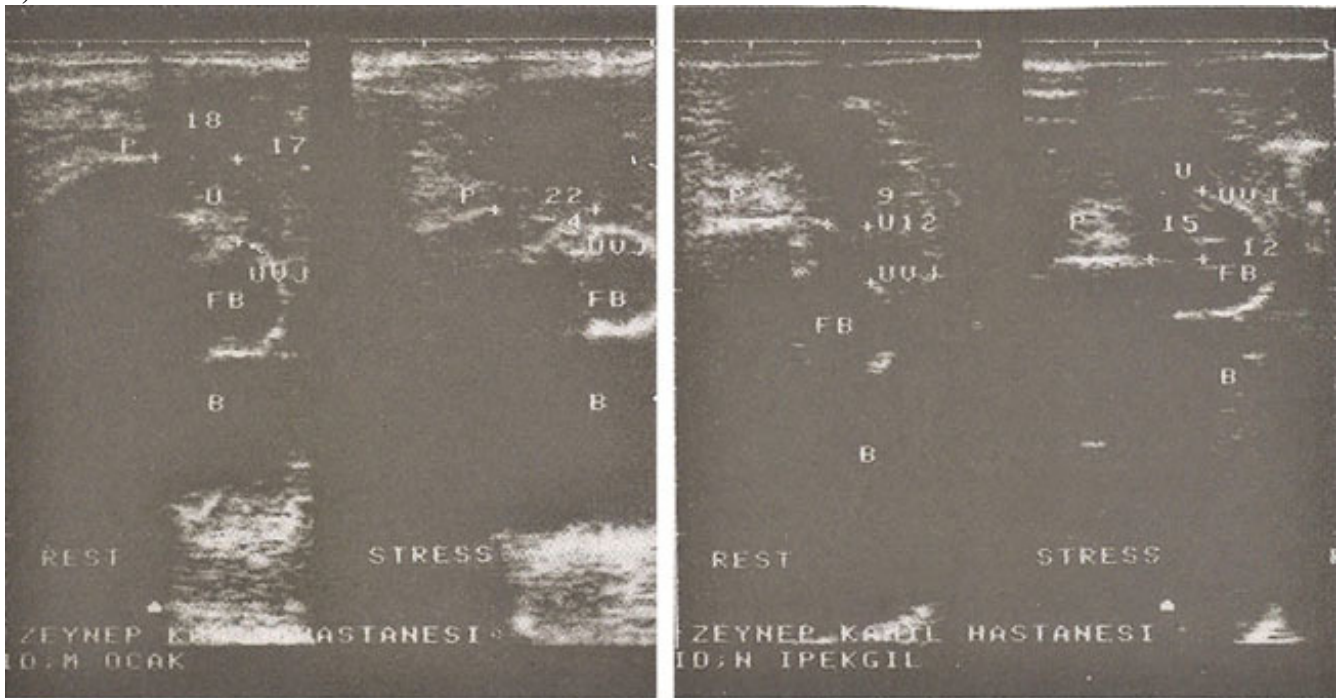
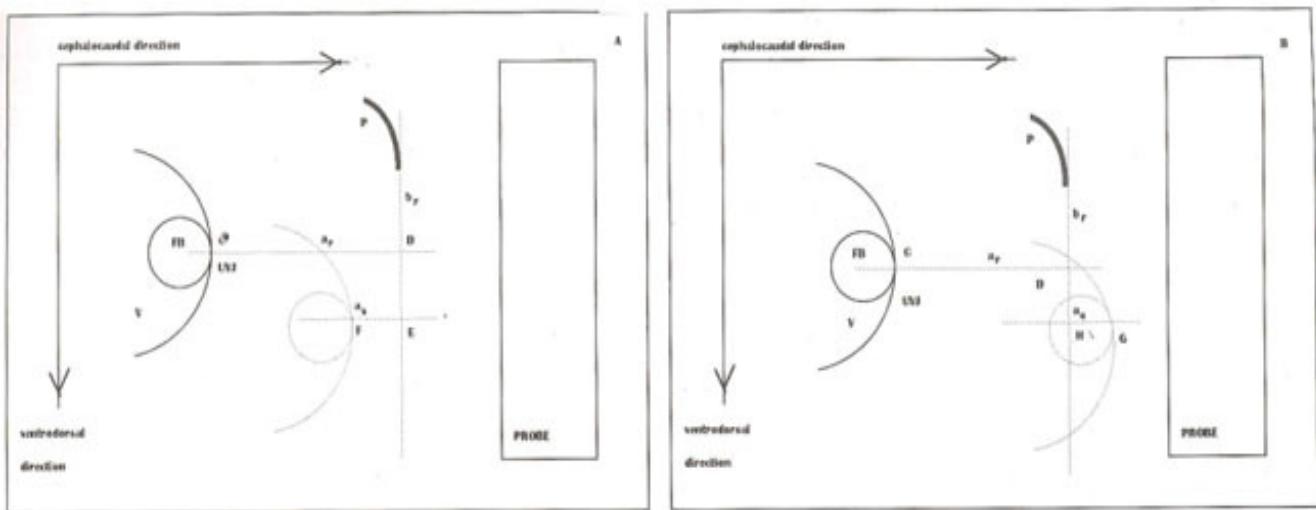


Figure 1. The appearances of the UVJ mobilities. First: The UVJ does not pass the pubis during stress. Δa : 19mm Δb : 2mm. Second: The UVJ passes the pubis during stress. Δa : 21mm Δb : 1 mm. Top: Rest position. Bottom: Stress position.



A: The UVJ does not descend the pubis during stress. B: It descends the pubis during stress.

P: Pubis V: Vesica UVJ: Urethrovesical Junction FB: Foley Balloon
r: rest $a_r = C - D$ $b_s = P - E$ $\Delta a = a_r - a_s$ (cephalocaudal mobility)
s: stress $a_s = F - E$ $b_r = P - D$ $\Delta a = a_r + a_s$ (when the UVJ passes the pubis)
 $\Delta b = b_s - b_r$ (ventrodorsal mobility)

Figure 2. The situation of the UVJ during stress and rest positions by perineal ultrasonography.

General physical examination was performed in all patients and controls. Incontinent patients

underwent standard urodynamic investigation to establish the diagnosis of genuine stress urinary incontinence, other types of incontinence or non-incontinence in accordance with the definitions of the International Continence Society¹⁶. Average values of groups and standard deviations for age, parity, weight and the ultrasonographic variables (ar, as, Aa, br, b, AB) were calculated and comparisons were made for the continent group and incontinent group, using the chi square test and student's t-test.

Results

There were no significant differences between continent and incontinent cases in terms of age, parity and weight (Table I).

Table I. Distribution of cases according to age, parity and weight.

mean ± SD	SUI(+)	SUI(-)	P Value
Age	38.8±4.2	39.1±4.1	N.S.
Parity	3.4±1.3	3.3±1.2	N.S.
Weight	70.2±6.1	69.4±5.8	N.S.

Table II. Mean cephalocaudal and ventrodorsal UVJ mobility (in mm) of cases (at rest and/during stress).

	ar	as	Δa	br	bs	Δb
SUI(+)	17.5±5.3	4.2*±10.1	21.5±8.7	13.6±7.7	23.2±6.3	9.6±5.9
SUI(-)	18.3±2.9	10.4±5.6	7.9±5.7	7.1±6.0	14.5±7.1	7.4±3.7
p	N.S	p<0.001	p<0.001	p<0.01	p<0.001	N.S

*The UVJ passes down the symphysis pubis.

Table II shows the UVJ mobility in patients and controls. Although, in the control group, UVJ was higher on the cephalocaudal axis at rest position compared to the incontinent group, there was no statistically significant difference. However, UVJ was found to be below the symphysis pubis for an average of 4.2 mm in the incontinent group during stress, whereas, the mean for the control group was 10.4 mm above the symphysis (p<0.001) (Table II). In addition, the cephalocaudal mobility (Aa) was 21.7 mm in the study group and 7.9 mm in the control group (p<0.001).

During the ventrodorsal movement UVJ was found at a mean distance of 13.6 mm from the symphysis pubis for the incontinent group at rest (br) and 7.1 mm for the control group (p In the incontinent group UVJ was below the symphysis pubis during stress in 22 of cases (62.85%) whereas, this was not observed in any of the control cases.

Discussion

We used a different method of perineal ultrasonography in a recent study, which has now been standardized in this study. This method has not been used by any other investigators. Kohom et al⁷, Gordon et al⁸, and Caputo et al⁹ did not take any reference points during perineal ultrasonography and

measured the difference between the positions of the UVJ during rest and stress conditions as the only parameter. In this study, the inferior edge of the symphysis pubis was used as a reference point and cephalocaudal and ventrodorsal components of the UVJ movement was measured during rest and stress. These two components were previously measured only by transvaginal or transrectal ultrasonography. Taking the inferior edge of the symphysis pubis as reference point enabled us to analyze the UVJ movement in more than one direction (ar, as, br, bs, .Aa, Ab) and to locate its position more precisely (Figures 1,2).

Benson et al¹⁷ found UVJ to be hypermobile in SUI patients on perineal ultrasonography. Mobility of UVJ in their control group was 4.0 mm, compared to 7.3 mm in our control group. The main reason for this difference is the low mean parity (1.2) and the age range (17-35 years) in their control group. In our study, the mean parity was 3.3 and mean age was 39.1 years. As age and parity increase, UVJ mobility also increases.

Weil et al¹³ measured the cephalocaudal and ventrodorsal components of UVJ mobility by transrectal ultrasonography in 33 incontinent and 22 continent patients. The cephalocaudal mobility was statistically significant in contrast to the ventrodorsal mobility. In their study, the ar values were 22.7 mm and 15.6 mm in the continent and incontinent group respectively and were significantly different ($p < 0.0001$).

In our study, although the ar value of the control group was more than the incontinent group, the difference was not found to be significant. This might be due to the difference of ages in the two groups. Bergman et al¹⁵ standardized the mobility of UVJ by transrectal ultrasonography. Investigating patients with pelvic relaxation and grouping them as continent and incontinent, they had found the UVJ mobility over 10 mm in all cases of SUI (mean 16 mm); whereas, the mean UVJ mobility in the control group was 2 mm. Their method of measurement for UVJ movement was between rest and stress positions and hence was different from ours. Bergman's criterion of 10 mm has also been accepted and applied by other investigators.

Johnson et al¹⁰ measured the vertical component of UVJ mobility in 279 incontinent patients in 271 of whom the mobility was 10 mm. In 64 continent patients UVJ mobility was 0.32 mm. They also noted the UVJ mobility to be below 10 mm (mean 0.21 mm) in surgically corrected cases and demonstrated a correlation between the UVJ stability and urinary continence.

In our study, although the cephalocaudal position of UVJ of the incontinent patients at rest (ar) was lower to the UVJ of the control group, there was no statistically significant difference. In contrast, the difference of UVJ positions during stress and the difference of mobility (Aa) were significantly different ($p < 0.001$). In the control group UVJ was not found below the symphysis pubis during stress, whereas 65% of cases of the incontinent group had their UVJ's below this plane (mean 4.2 mm). This suggests that UVJ of incontinent patients is not at a very low position during rest but because of hypermobility moves during stress.

When the ventrodorsal component was analyzed, UVJ of the incontinent patients at rest (ar) was found to be placed more dorsally ($p < 0.01$). However, the UVJ mobility during stress was similar in both groups. This means that UVJ is placed more dorsally in incontinent patients at rest position.

It is concluded that during perineal ultrasonography, position of UVJ can be evaluated in a more topographical fashion when inferior edge of pubic symphysis is used as a reference point. This method can be used as a screening test in the preoperative period to demonstrate the anatomical defect and also to evaluate the surgical success in the postoperative period. It might also be helpful to diagnose the mixed type of SUI cases where detrusor instability accompanies UVJ mobility. In addition, by observing the stability of UVJ in cases where only urethrovaginal sphincter injury is present, the diagnosis of type III SUI¹⁸ can be made. Perineal ultrasonography can be used for evaluation of all types of SUI.

References

1. Enhorning. G. Simultaneous recording of intravesical and intraurethral pressure. *Acts Chir. Scand.*, 1971;276 (suppl): 1-68.
2. Jeffcoate, T.N.A. and Roberts, H. Observations on stress incontinence of urine. *Am. J. Obstet. Gynaecol.* 1952;64:721 -738.
3. Crystale, CD., Charme, L.S. and Copeland, W.E. Instrument and method Q-tip test in stress urinary incontinence. *Obstet. Gynaecol.*, 1971 ;38:313-315
4. Hodgkinson, C.P., Damb, H.P. and Kelly, W.T. Instrument and method. Urethrocystogram. Metallic bead chain technique. *Clin. Obstet. Gynaecol.*, 1958;1:668-677.
5. Kolbl, H., Bernaschek, G. and Wolf, G. A comparative study of perineal ultrasound scanning and urethrocystography in patients with genuine stress incontinence. *Arch. Gynaecol. Obstet.*, 1988;244:39-45.
6. Dundas, D., Hilton, P., Williams, J.E. et al. Aetiology of voiding difficulties post colposuspension. In proceedings Twelfth Annual Meeting of International Continence Society, Leiden; Krips Repro Meggel, poster, 1982, pp. 1-13.
7. Kohom, E., Scioscia, A.C., Jeanty, P. et al. Ultrasound cystourethrography by perineal scanning for assessment of female stress urinary incontinence. *Obstet. Gynaecol.*, 1986;68:269-274.
8. Gordon, D., Pearce, M., Norton, P. et al. Comparison of ultrasound and lateral chain urethrocystography in the determination of bladder neck descent *Am. J. Obstet. Gynaecol.*, 1989; 160:182-185.
9. Caputo, R.M. and Benson, J.T. The Q tip test and urethrovesical junction mobility. *Obstet. Gynaecol.*, 1993;82:892-896.
10. Johnson, 3D., Lamensdorf, H., Hollander, IN. et al. Use of transvaginal endosonography in the evaluation of women with urinary incontinence. *J. Urol.* 1992;147:421-425.
11. Kil, P.J.M., Hoekstra, 3W., Vander, .Meijden, A.P.M. et al. Transvaginal ultrasonography and urodynamic evaluation after suspension operations; Comparison among the Gittes, Stamey and Burch suspensions. *J. Urol.*, 1991;146:132-136.
12. Quinn, M.J., Reynon, J., Mortensen, N.J. et al. Vaginal endosonography in the post-operative assessment of colposuspension. *Br. J. Urol.*, 1989;63 :295-300.
13. Weil, E.H.J., Van, W., Van-Doom, E.S.C. et al. Transvaginal ultrasonography: A study with healthy volunteers and women with genuine stress urinary incontinence. *Eur. Urol.*, 1993;24:226-230.
14. Bergman, A., Ballard, C.A and Platt, I. D. Ultrasonic evaluation of urethrovesical Junction in women with stress urinary incontinence. *J. Clin. Ultrasound*, 1988;16:295-300.
15. Bergman, A., Vermesh, M., Ballard, C.A. et al. Role of ultrasound in urinary incontinence evaluation. *Urology*, 1989;33 :443-444.
16. International Continence Society. First, second and third report on the standardization of terminology of lower urinary tract function. *Br. J. Urol.*, 1976;48:39-42., 1977;49:207-210., 1980;52:348-350.
17. Benson, J.T., Summers, SE. and Pitunan, S. Definition of normal female pelvic floor anatomy using ultrasonographic techniques. *J. Clin. Ultrasound*, 1991;19 275-82
18. Raz, S., Little, NA., Juma, Si. Female urology. in: Walsh P.C. eds. *Campbell's Urology*. 6th ed. West Philadelphia. Pennsylvania, W.B. Saunders, 1992, pp. 2782-2828.