

Moyamoya Disease of Childhood as a Cause of Recurrent Cerebral Ischemic Attacks - A Case Report

Pages with reference to book, From 17 To 18

Shahnaz Ibrahim (Departments of Paediatrics, The Aga Khan University, Karachi.)

S. Shiraz Hyder (Departments of Medicine, The Aga Khan University, Karachi.)

Moyamoya as a cause of occlusive recurrent cerebral angiopathy has been described mostly in Japan although cases have been reported worldwide. In our review of local literature, no case has so far been described in this part of the world. A case of a young boy with recurrent seizures and ischemic attacks is being presented who was diagnosed as having moyamoya disease.

Case Report

A three and half years old male child presented with a one day history of high grade fever, rash, right sided focal seizures and right hemiparesis. He was well and had developed normally till 9 months of age when he contracted measles and had a generalized tonic clonic seizure. One year later he had another generalized seizure with fever and a month later a third seizure which was focal in nature after which he developed hemiparesis. The weakness was more pronounced in the leg which gradually improved. CT scan revealed mild focal atrophic changes. EEG showed mild focal slowing with sharp waves in the right mid and posterior temporal region. He was placed on carbamazepine 10mg/kg/day and sodium valproate 30 mg/kg/day, no seizures occurred till this admission.

On examination the patient was drowsy with a Glasgow Coma scale of 8/15 and was having right sided focal seizures. On neurological examination, right sided focal signs were seen with power grade 2/5, tone increased, reflexes grade 3+ and plantars upgoing. Rest of the examination was normal.

CSF examination showed a cell count of $2/\text{mm}^3$, proteins of 43 mg/dl and sugar 69 mg/dl. Culture was negative. Hemoglobin, hematocrit, electrolytes, calcium, alanine transferase were normal. CT scan head showed multiple circumscribed areas of low density in both cerebral hemispheres. On post-contrast scan, there was some irregularity of arteries in the middle cerebral cistern and anterior interhemispheric fissure. Subsequent to the CT findings, a hemoglobin electrophoresis, immune profile, ECG and echocardiogram were done which were all normal. Immune profile showed ANA to be +++ve (peripheral) anti DNA was 0.6 IU/ml (0.6-6.0), anticardiolipin 1gm, Anticardiolipin IgG and cystine screen were normal.

He was managed with I/V fluids, carbamazepine and sodium valproate. Neurological improvement followed with a better sensorium and decreased weakness of right side. MRI showed evidence of multiple flow void areas in the deep grey matter suggestive of dilated collateral channels (Figure I).

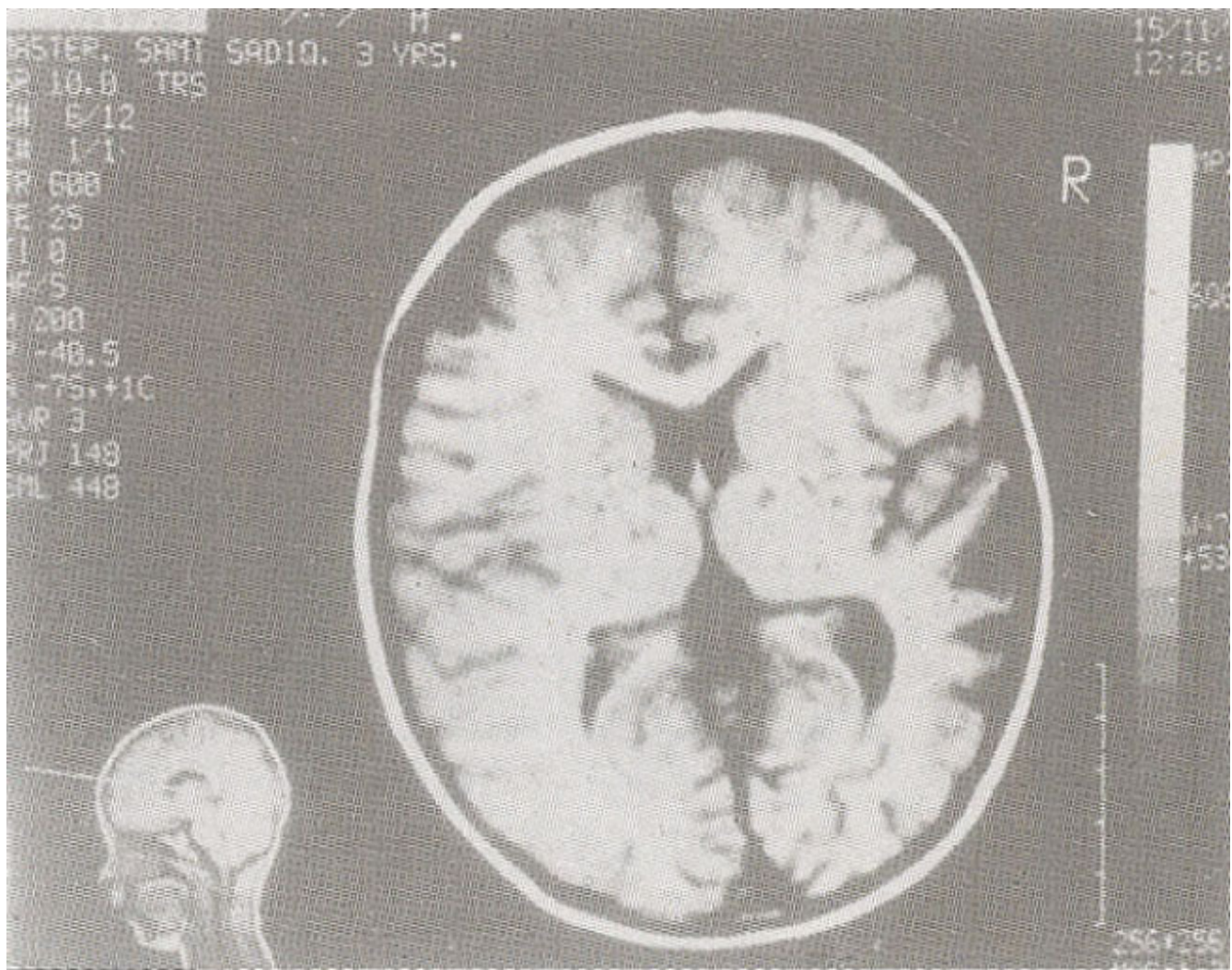


Figure 1. MRI showing dilated basal collateral channels in the deep grey matter.

There was also evidence of high signal areas in both cerebral hemispheres on T₂ weighted images consistent with ischemic infarct. Four vessel cerebral angiogram showed occlusion in the supraclinoid portion of internal carotid artery bilaterally with multiple telangiectatic collaterals seen in the basal ganglia region on both sides (Figure 2).

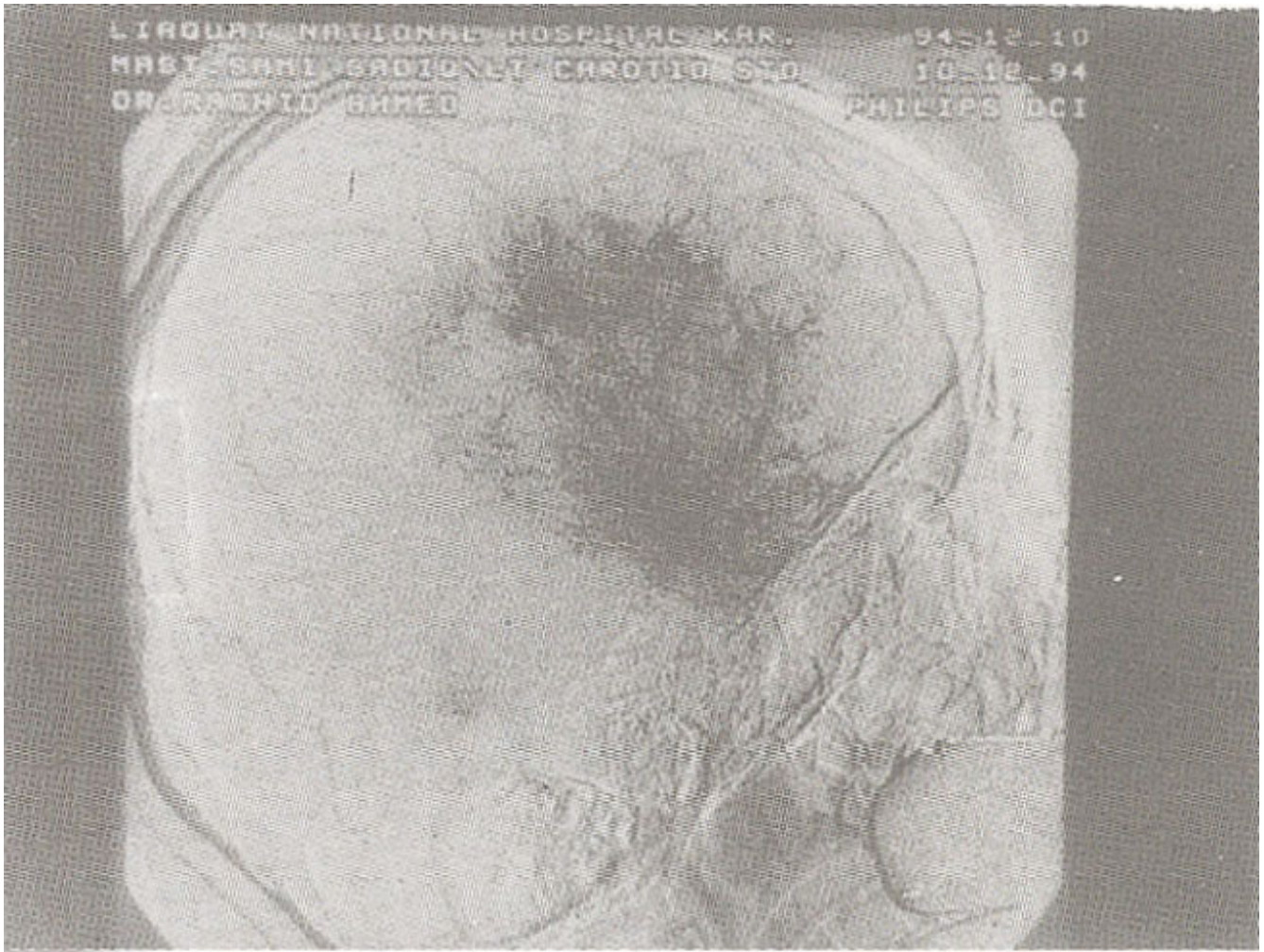


Figure 2. Cerebral angiogram showing occlusion at the supraclinoid portion of the internal carotid artery with multiple telangiectatic collaterals in basal ganglia of both sides. These gave a typical "puff of smoke" appearance (Figure 3).

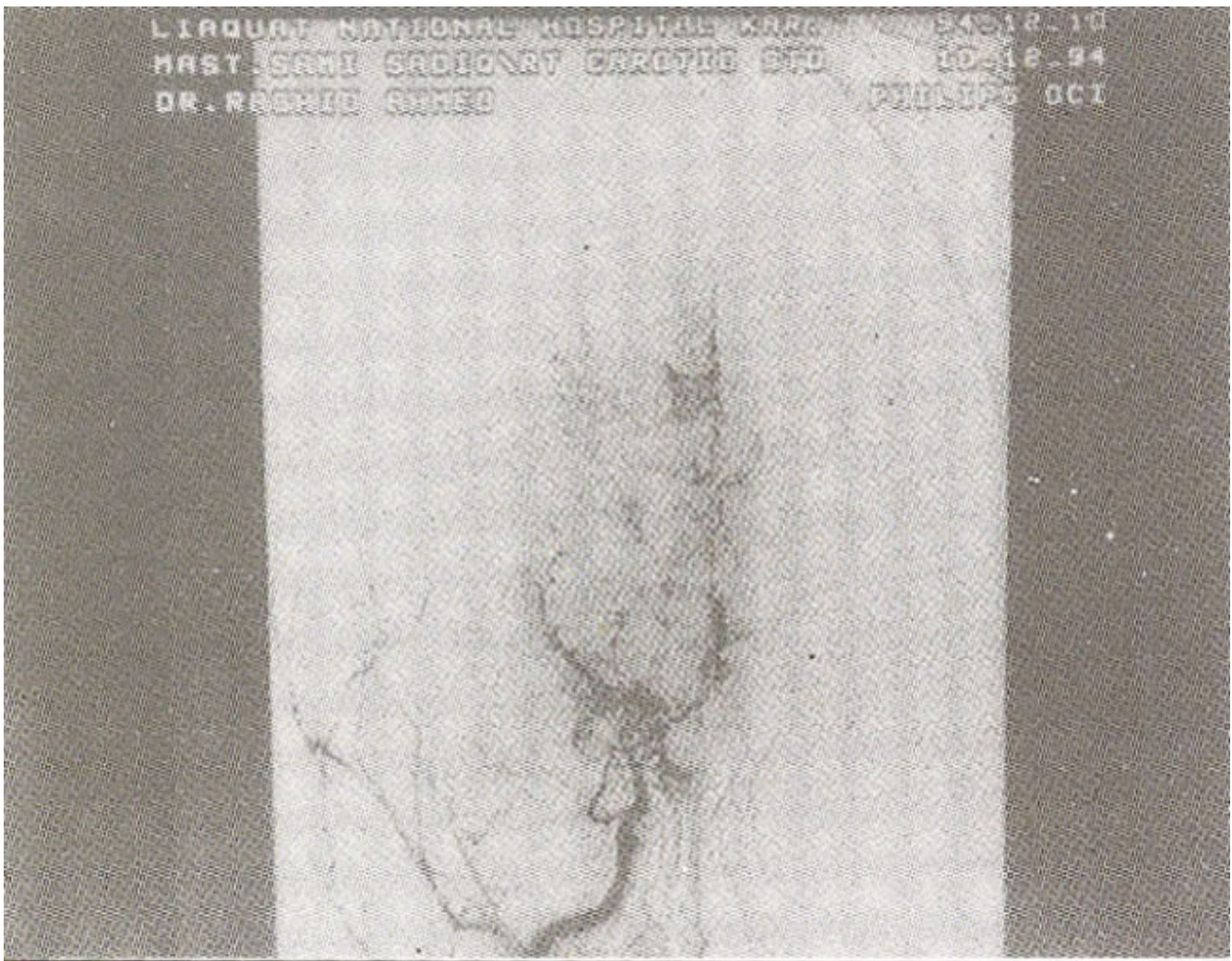


Figure 3. Four vessel cerebral angiogram frontal view. Typical "puff of smoke appearance"

Filling of the pericallosal arteries through collateral vessels from prominent middle meningeal vessels was also observed. Filling of the vertebral and the basilar artery and its branches was seen on contrast studies. All these findings conformed with progressive idiopathic arteriopathy of childhood (Moyainoya).

Although clinically, the patient has shown considerable improvement, he still has moderate motor aphasia with mild weakness in right arm and leg and a hemiparetic gait. He is being managed conservatively with physiotherapy and speech training. Vascular surgery is being considered as an option for prevention of further ischemic events.

Discussion

Moyamoya disease is a chronic and progressive occlusive cerebral vascular disorder, first described by Suzuki and Takaku¹.

The term Moyamoya in Japanese denotes "something hazy, like a puff of smoke" and refers to the angiographic appearance of the wispy network of collateral vessels at the base of the brain that represents this vascular anomaly^{2,3}.

Moyamoya disease occurs much more frequently in Japan but has been reported sporadically from all over the world. There seem to be two definite peaks of age incidence, one in children less than 10 years

and the other in the 3rd decade. The majority of cases are hospitalized within 2 years of onset. The exact etiology of Moyamoya disease is obscure. Majority of cases have no predisposing factors⁴. The moyamoya syndrome is associated with certain HLA phenotypes, Fanconi's anemia, Down Syndrome, Von Recklinghausen's disease⁵⁻⁸, peripheral vascular occlusive disease, trauma, therapeutic irradiation of the head (especially for sellar and suprasellar lesions) and a variety of infections including tonsillitis, leptospirosis and tuberculosis⁹⁻¹⁰. The finding of autoantibodies in patients with Moyamoya supports and immunological pathogenesis¹¹.

In children, the presentation is more in the form of transient ischemic attacks (TIA), seizures or rarely strokes, with permanent deficits in recurrent TIAs or seizures.

Seizures focal or generalised occur commonly in children. They are easily controlled by anticonvulsant therapy.

Headaches are frequent in the older pediatric patients and mental deterioration is seen in cases with recurrent ischemic attacks. Considerable improvement in the IQ scores after revascularization procedure has been observed¹². The clinical course may appear to stabilize despite angiographic evidence of progression. But the formation of anastomotic channels is insufficient to provide alternate flow and prevent clinical deterioration. The rate of clinical decline varies considerably in each patient. Various diagnostic tools are available for evaluation, as EEGs, CT scan and MRI¹³ but cerebral angiography confirms the diagnosis.

The angiographic findings are characteristic, classically revealing symmetrical stenosis or occlusion of both carotid forks, associated with abnormal vascular network called Moyamoya (puff of smoke) in the basal ganglia.

Although no specific treatment has been reported¹⁴, steroids are considered effective in certain cases, especially those with involuntary movements and (ii) in the actual phase of recurrent ischemic attack. The mechanism of action is not clear¹. A number of surgical angioplastic procedures have been attempted¹³ but all are in the pioneering stages. If the revascularization procedures could prevent or minimize the progression of cerebral ischemia remain a controversial issue.

References

1. Suzuki, J. and Takaku, A. Cerebrovascular Moyamoya disease. Disease showing abnormal network like vessels in base of brain. *Arch Neurol.*, 1969;20:288-299.
2. Hoffman, J.H. and Griebel, W.R. Moyamoya syndrome in children. In 'Edwards, BSM, Hoffman, J.H eds. *Cerebral vascular disease in children and adolescents. Current neurosurgical practice.* London, Williams and Wilkins, 1989, pp. 229-237.
3. Suzuki, J. and Kodama, N. Moyamoya disease- A review. *Stroke*, 1983;14:1041-1089
4. Adrie, J.M. and Picard, L. Moyamoya syndrome or disease Etiopathogenetic study. Therapeutic indications. *J Neuroradiol.*, 1974; 1:33-39
5. Yasuhiro, Y., Hajime, H. and Takehiko, O. Moyamoya disease: Diagnosis, treatment and recent achievement. In Barnett, J.H., Stein, M.B., Mohr, P.J., Yatsu, M.F. eds *Stroke pathophysiology, diagnosis and management* New York, Churchill Livingstone, 1986, pp. 805-829.
6. Cohen, N., Berant, M. and Simon, J. Moyamoya and Fanconi's anemia *Pediatrics*, 1980;65:804-805.
7. Pearson, E., Lenn, N.J. and Caie, W.S. Moyamoya and other causes of stroke in patients with Down Syndrome. *Pediatr. Neurol.*, 1985;1:174-179.
8. Salyer, W.R. and Salyer, D.C. The vascular lesions of neurofibromatosis. *Angiology*, 1974;25:510-519.
9. Mathew, N.T., Abraham, J and Chandy, J. Cerebral angiographic features in tuberculous meningitis. *Neurology*, 1970;20: 1015-1023.

10. Goldberg, H i. Moyamoya associated with peripheral vascular occlusive disease Arch. Dis. Child., 1974;9:964-966.
11. Gold, A.P. and Carter, S. Acute hemiplegia of infancy ,uid childhood. Pediatr. Clin NorthAm., 1976;23:413-433
12. Ishii, R Tekwchi, S., Ibayashi, K. et al. Intelligence in childien with Movamova a disease. Evaluation after surgical treatment with special reference to changes in cerebral slurred flow. Stroke, 1984;15:873-877.
13. Demaerel, P., Wilms, G., Gasteels-Van-Daele, M et al Moyamoya diagnosis using MRI and NMR angiography, J. Radiol., 1990,71.119- 123
14. Suzuki, .1., Takaku, A., Kodama, N. et al. An attempt to treat cerebrovascular. Moyamoya disease in children. Childs Brain, 1975;1:193-210.