

# Allergic Bronchopulmonary Aspergillosis: An Unusual Complication of Bronchial Asthma

Pages with reference to book, From 329 To 331

S. Fayyaz Hussain, Javaid A. Khan ( Department of Medicine, The Aga Khan University Hospital, Karachi. )

M. Ata Khan ( Department of Medicine, The Aga Khan University Hospital. Karachi. )

## Introduction

Asthma is a common medical problem in Pakistan. Allergic Bronchopulmonary Aspergillosis (ABPA), an immune mediated disease, is an unusual complication of bronchial asthma which can result in bronchiectasis, pulmonary fibrosis, respiratory failure and death. Early diagnosis is important so that with proper therapy permanent lung damage can be prevented. First described in 1952<sup>1</sup>, ABPA was thought to be a rare disorder, but with increased awareness amongst the physicians and better diagnostic techniques, cases are being recognized more frequently. The clinical features of ABPA (cough, fever, hemoptysis and lung infiltrates) are usually mistaken for pulmonary tuberculosis (TB). We present three cases in which failure to consider the diagnosis of ABPA resulted in repeated courses of anti-TB therapy and/or progressive lung damage and continued morbidity.

## Case reports

### Case 1: Recurrent hemoptysis and pulmonary infiltrates

A 19 year old male, asthmatic from childhood. developed fever, cough, hemoptysis and pulmonary infiltrate in 1987. He was treated for TB for nine months. In 1992, he again presented with fever, anorexia, cough, hemoptysis and patchy infiltration in left upper lobe (Figure 1a).

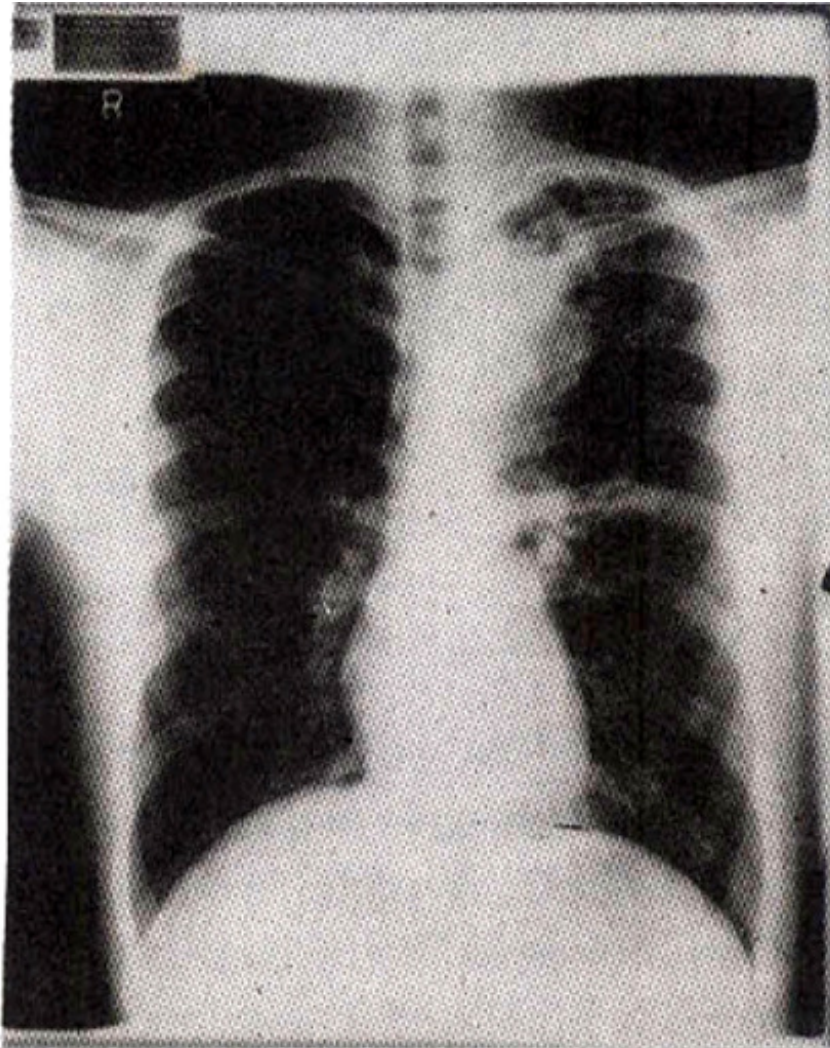


Figure 1(a). Chest radiograph showing left upper lobe infiltrate mimicking the diagnosis of TB

Sputum was negative for AFB but on clinical suspicion, he was restarted on quadruple anti-TB therapy in adequate doses. In addition, he continued to receive bronchodilators, inhaled steroids and intermittent courses of oral prednisolone. Six months later, while still on anti-TB drugs, he developed recurrence of symptoms with right pleuritic chest pain, fever, cough, wheeze and hemoptysis. Repeat chest x-ray showed infiltrates in right lung (Figure 1b).

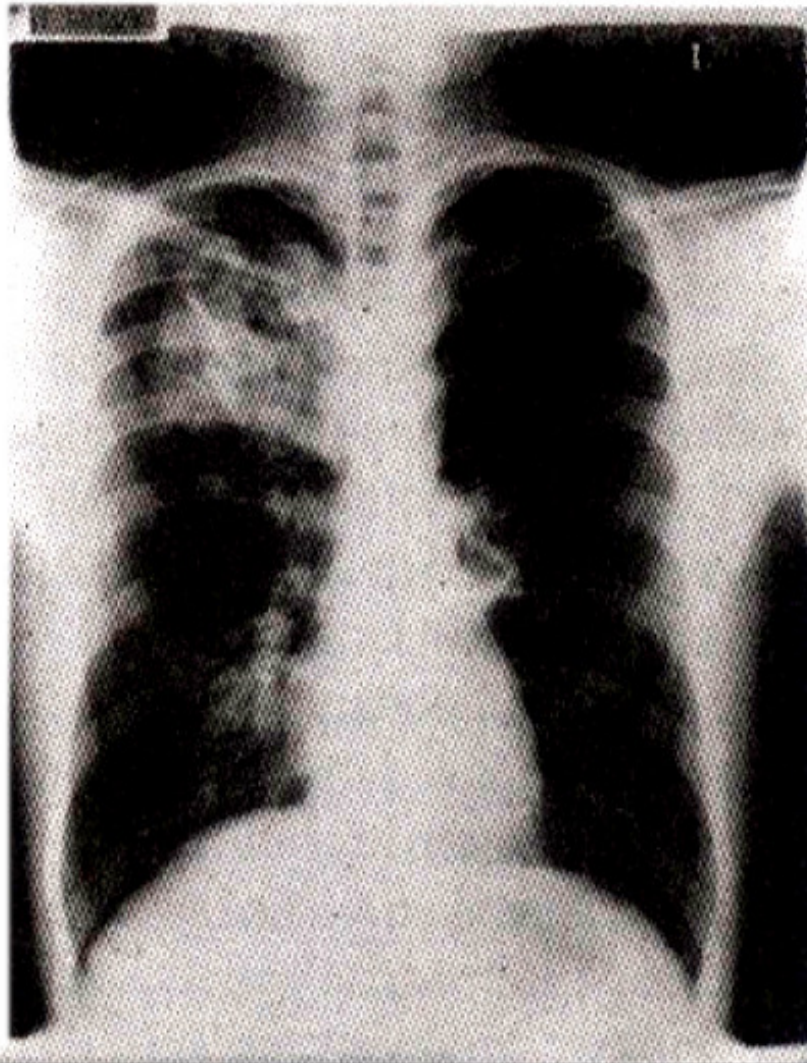


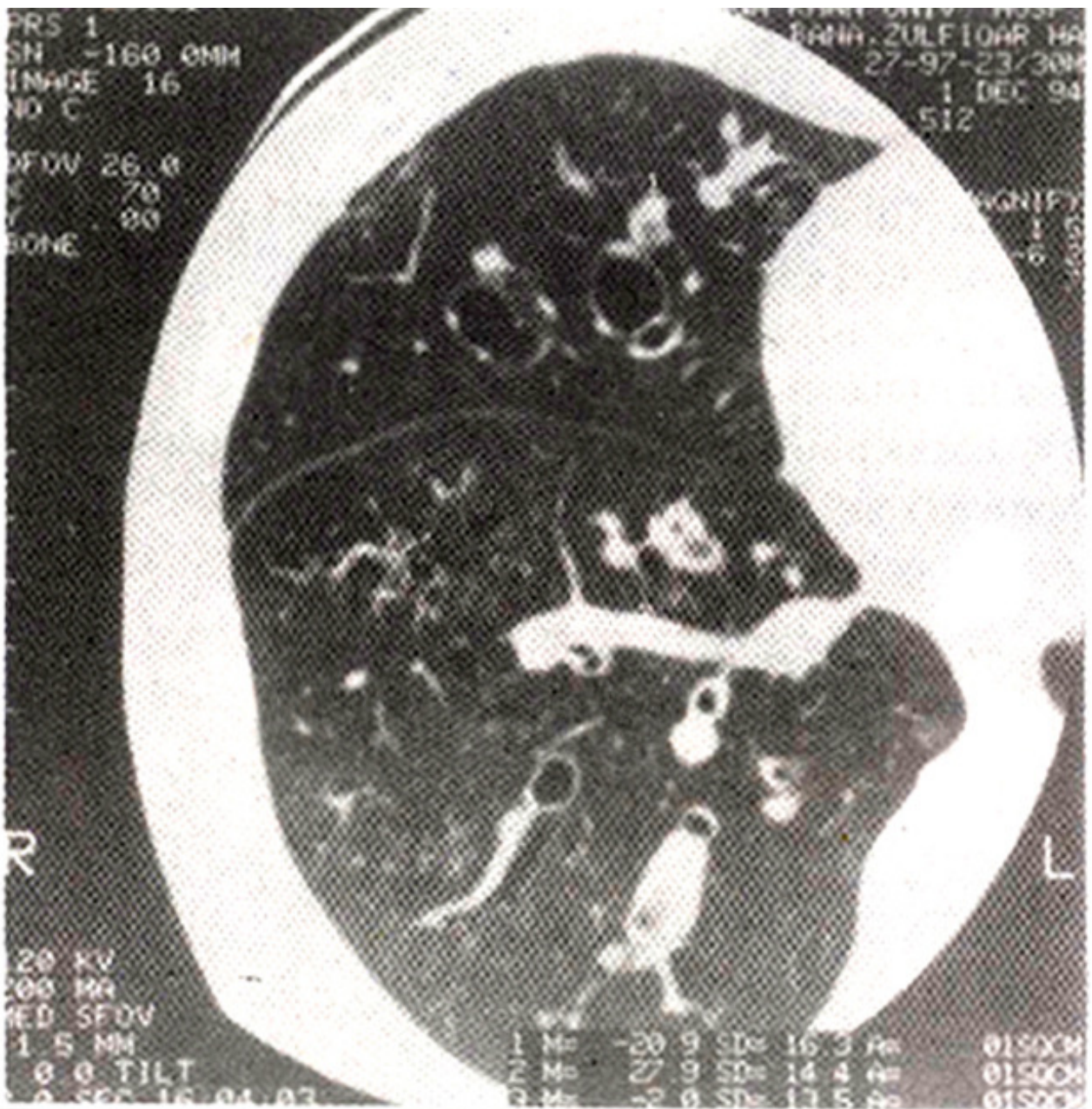
Figure 1 (b). Chest radiograph showing right upper zone infiltrate while the patient was on anti-TB medications.

Sputum for AFB was negative. He had eosinophilia of 12% (WBC count 12600/dl) and 2 grossly elevated serum IgE (>1000 iu/ml). Aspergillus antibodies were negative. A diagnosis of ABPA was made and prednisolone 30 mg daily was started. This resulted in rapid resolution of clinical and radiological features. Patient remains well on maintenance prednisolone at a dose of 7.5 mg daily.

**Case 2: Bilateral interstitial infiltrates and bronchiectasis**

A 24 year old male, asthmatic for four years, presented with high grade fever, cough with purulent sputum and right sided chest pain. He had two similar episodes during the last one year. Bilateral widespread rhonchi and crepitation were found on chest examination. Chest x-ray showed bilateral interstitial infiltrates and bronchiectatic changes. White cell count was 12700/dl with 33% eosinophils. Sputa for AFB were negative. Patient improved partially with a course of Amoxicillin-Clavulanic Acid, bronchodilators and physiotherapy but continued to be wheezy and dyspnoeic. Serum IgE was elevated above 1000 IU/ml.





**Figure 2. Computerized Tomographic (CT) scan of the lung showing mucus impaction in dilated bronchi and central bronchiectasis in a patient with ABPA**

CT scan of the chest (Figure 2) revealed mucous impaction in the bronchi and central bronchiectasis. He made a good response to oral steroid therapy.

**Case 3: Migratory infiltrates and marked eosinophilia**

This 28 year old lady gave two years history of recurrent cough, fever and wheeze. Symptoms improved temporarily with the use of antibiotics and bronchodilators but recurred on stopping therapy. She presented with relapse of her symptoms and was found to have bilateral wheeze. White cell count was 24,800/di with marked eosinophilia of 60%. Chest x-ray showed infiltrates in left upper and right middle zones. Her previous eosinophil counts varied from 40-60% and x-rays showed fleeting pulmonary infiltrates. Serum IgE was elevated at 970 IU/ml. She made a rapid clinical and radiological response to oral steroid therapy and remained well one year after discharge.

## Discussion

Aspergillus fungus is widely distributed throughout the world and can involve the lung through a number of diverse mechanisms. *A. fumigatus* is the most common pathogenic species, but other species such as *A. niger*, *A. flavus* and *A. terreus* are also pathogenic in humans. Allergic broncho pulmonary aspergillus (ABPA) is primarily an immune mediated disorder. It develops when aspergillus colonizes the airways of a susceptible host and produces antigens. There is no tissue invasion by the fungus. Type I (IgE mediated immediate hypersensitivity), Type III (IgG mediated immune complex) and Type IV (cell mediated delayed hypersensitivity) responses have all been implicated in the disease process<sup>2,3</sup>. These immune responses result in bronchospasm, increased permeability of bronchial mucosa, pulmonary and blood eosinophilia, chronic inflammation and bronchial destruction, bronchiectasis and pulmonary fibrosis. Most patients with ABPA are very atopic and have asthma. The peak incidence of ABPA is in the third and fourth decade of life<sup>4</sup>. Other allergic symptoms, such as rhinitis, conjunctivitis, urticaria, eczema, food or drug allergy may also be present. In corticosteroid dependent asthmatics prevalence of ABPA was found to be 7-14% in North America<sup>5</sup> and 15-22% in Great Britain<sup>6</sup>. In India, the prevalence of antibodies to Aspergillus among asthmatics was found to be 20% by ELISA method<sup>7</sup>. The other conditions where ABPA occurs in up to 10% of patients is cystic fibrosis<sup>8</sup>. The clinical features include cough, hemoptysis, expectoration of mucus plugs, dyspnoea, fever, malaise, anorexia and pleuritic chest pain in an asthmatic patient<sup>9</sup>. Most of these features are easily confused as TB and result in repeated courses of prolonged anti-TB therapy. Physician's awareness for ABPA is very low which results in delayed diagnosis and permanent lung damage. There is no single pathognomonic test for ABPA but the diagnosis can be made by following Rosenberg and Patterson's criteria (Table). However, the serological markers may be absent during remission or when the patient is on corticosteroids<sup>10</sup>. The patient may be followed for several years before all the diagnostic criteria can be fulfilled<sup>11</sup>. Species of aspergillus other than *A. fumigatus* and fungi other than aspergillus have also been reported to cause similar disease<sup>12</sup> and in these cases the serological markers for *A. fumigatus* would be negative. Serial chest radiographs reveal fleeting pulmonary infiltrates usually in the upper lobes<sup>13</sup>. Tramline, parallel line and ring shadows represent thickened bronchial walls. The typical branching toothpaste and gloved finger shadows are due to mucous impaction. Massive consolidation may be seen. Atelectasis and pulmonary fibrosis is less common. Bronchography has been the gold standard for the diagnosis of bronchiectasis but high resolution CT scan is equally sensitive for detection of bronchial wall changes<sup>14</sup>. The course of ABPA is marked by recurrent episodes of reversible bronchial obstruction. Without early diagnosis and treatment, central bronchiectasis, pulmonary fibrosis, respiratory failure and death may occur. Some of the other conditions, characterised by pulmonary infiltrates, peripheral eosinophilia and elevated serum IgE level, which need to be differentiated from ABPA are Loeffler's syndrome, tropical pulmonary eosinophilia, eosinophilic pneumonia, hypereosinophilic syndrome and Churg Strauss syndrome. Systemic corticosteroids control acute exacerbation, prevent permanent lung damage and is the treatment of choice<sup>15</sup>. Usual starting dose of 0.5 mg/kg/day is given for 2-3 weeks and then tapered gradually over the next 6 months. High dose inhaled steroids can be beneficial and may help to diminish the dose or duration of oral steroids<sup>16</sup>. Anti-fungal therapy had been ineffective in the therapy of ABPA but recent studies with newer agents such as Itraconazole appear promising<sup>17</sup>. Diagnosis of ABPA requires a high index of suspicion. It should be considered in asthmatics who develop systemic symptoms, fleeting pulmonary shadows, eosinophilia and grossly elevated serum IgE levels. Pulmonary TB should be ruled out by sputum examination and other diseases with pulmonary

infiltrates and eosinophilia need to be excluded. Early diagnosis and steroid therapy are crucial to prevent irreversible lung damage and respiratory failure.

## References

1. Hinson, K.F.W., Moon, A.J. and Plummer, N.S. Broncho-pulmonary aspergillosis. A review and a report of eight new cases. *Thorax*, 1952;7:317-333.
2. Pepys, J. Hypersensitivity diseases of the lungs due to fungi and organic dusts. Basel. S. (Switzerland), Karger, 1969.
3. Chan, Yeung, M., Chase, W.H., Trapp, .W. et al. Allergic broncho- pulmonary aspergillosis. Clinical and pathological study of three cases. *Chest*, 1971 ;59: 33-39.
4. Rosenberg, M., Patterson, R., Mintzer, R. et al. Clinical and immunological criteria for the diagnosis of allergic broncho- pulmonary aspergillosis *Ann. Intern. Med.*, 1977,86:405-14.
5. Basich, i.E., Graves, T.S., Baz, MN: et al. Allergic broncho- pulmonary aspergillosis in corticosteroids dependant asthmatics. *J. Allergy Clin. Immunol.*, 1981 ;68:98-102.
6. Henderson, A.H., English, M.P. and Vecht, Ri. Pulmonary aspergillosis: A survey of its occurrence in patients with chronic lung disease and a discussion of the significance of diagnostic tests. *Thorax*, 1968;23 :513-18.
7. Kumar, A., Sahu, R.C., Subbannayyar, K. et al. Prevalence of antibodies to aspergilli in bronchial asthmatics. *J. Postgrad. Med.*, 1989;35:20-23.
8. Laufer, P., Fink, J.N., Bruns, W.T et al. Allergic broncho- pulmonary aspergillosis in cystic fibrosis. *J Allergy Clin. Immunol.*, 1984;73(Pt 1 ):44-8.
9. McCarthy D.S. and Pepys, J. Allergic broncho.pulmonary aspergillosis *Clinical immunology*. 1. Clinical features. *Clin. Allergy*, 1971:1:261-86.
10. Patterson, R., Greenberger. PA., Haiwig, J.M. et al. Allergic broncho-pulmonary' asperg l losis natural history and clas.stfication of early disease by serologic and roentgenographic studies. *Arch. Intern. Med.*, 1986; 14:916-8
11. Ricketti. A.J. Greenberger, P. and Patterson, R. Varying presentations of allergic bronchopulmonary aspergillosis *Int. Arch. Allergy Appl. Immunol.*, 1984;73:283-5.
12. Akiyama, K., Mathison, D.A., Riker, 3.8. et al. Allergic Bronchopulmonary candidiasis. *Chest*, 1984;85 :699-701.
13. McCarthy, D. S., Simon, G. and Hargreave, FE. The radiological appearances in allergic bronchopulmonary aspergillosis. *Clin. Radiol.*, 1970;21:366-75.
14. Neeld, D.A., Goodman, L.R., Gurney, J.W. et al. Computerized tomography in the evaluation of allergic bronchopulmonary aspergillosis. *Am Rev. Respir. Dis.*, 1990;142:1200-5.
15. Wang, J.L., Patterson, R., Robert, M. et al. The management of allergic bronchopulmonary aspergillosis *Am. Rev. Respir. Dis.*, 1979;120:87-92.
16. Imbeault, B. and Cormier, Y. Usefulness of inhaled high-dose corticosteroids in allergic bronchopulmonary aspergillosis. *Chest*, 1993;103:1614-17.
17. Hostetler. J.S., Denning, l).W and Stevens, D.A. US experience with itraconazole in *Aspergillus*. *Cryptococcus* and *Histoplasma* infections in the immunocompromised host. *Chemotherapy*. 1992;38:12-22.