

KASABACH MERRITT SYNDROME

Pages with reference to book, From 159 To 161

Shahina Qureshi, Zaheer Abbasi, Naheed Qadeer, Naila Yaqoob (Children's Hospital, Pakistan Institute of Medical Sciences, Islamabad.)

Hemangiomas of infancy are usually congenital lesions. Occasionally they are associated with microangiopathic hemolytic anaemia, thrombocytopenia, and a consumptive coagulopathy. This is most often associated with cavernous hemangiomas. Thrombocytopenia associated with giant cavernous hemangiomas was first noted by Kasabach and Merritt in 1940¹. As the primary mechanism of platelet destruction is intravascular coagulation within the tumour, therapy should be aimed at controlling the coagulopathy, by reducing the size of the tumour. Different modalities are tried to accomplish reduction of the lesion. We report a case managed successfully by localized superficial irradiation.

CASE HISTORY

A 7 months old baby girl was first admitted to our hospital for epistaxis, and gingival bleeding. She had a history of swelling in the left suprascapular region, left thorax and left shoulder, since birth, which increased gradually in size (Figure 1).

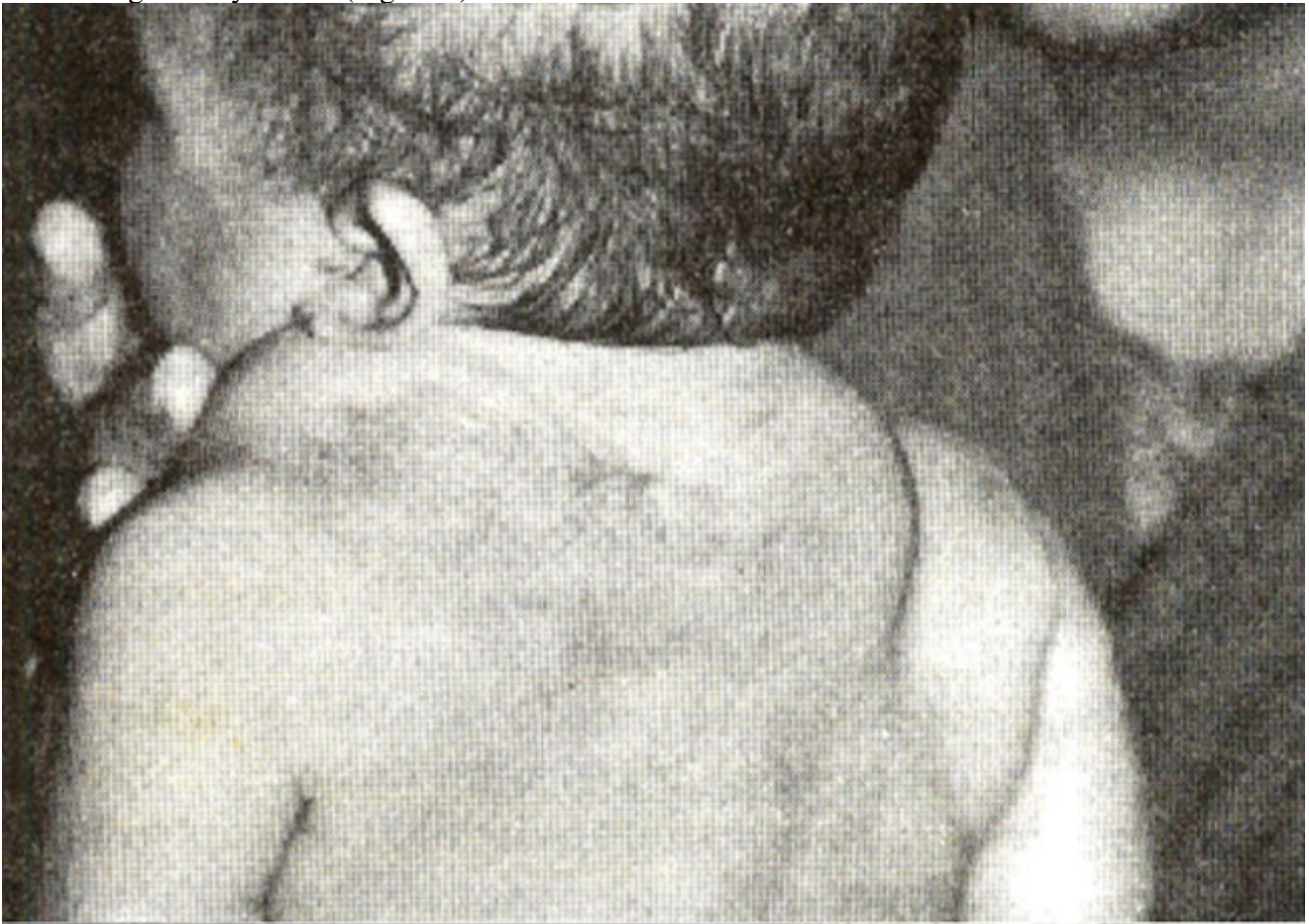

Figure 1. Kasabach-Merritt Syndrome. Pre operative.

At 2 1/2 months of age bleeding from the gums was noticed by the mother, which subsided without treatment. She continued to have excessive bruising and mild epistaxis off and on. Examination

revealed a well nourished, pale child, with red, raised and boggy swelling over left shoulder. Scapula seemed elevated by the subscapular swelling. There was no other abnormal finding on examination. Laboratory data included a complete blood picture which showed, WBC 8500, 30% neutrophils, 60% lymphocytes, haemoglobin 7.8 gms/dl and platelet count 46,000/cm. Bleeding time was prolonged (8 mins) but clotting time was normal. Bone marrow examination showed normal cellularity and normal megakaryocytes. Diagnosis of Kasabach-Merritt Syndrome was made. As the patient continued to have thrombocytopenia, a partial excision of the tumour was done 2 days after admission i.e. at 7 months of age after repeated platelet transfusions (Figure 2).

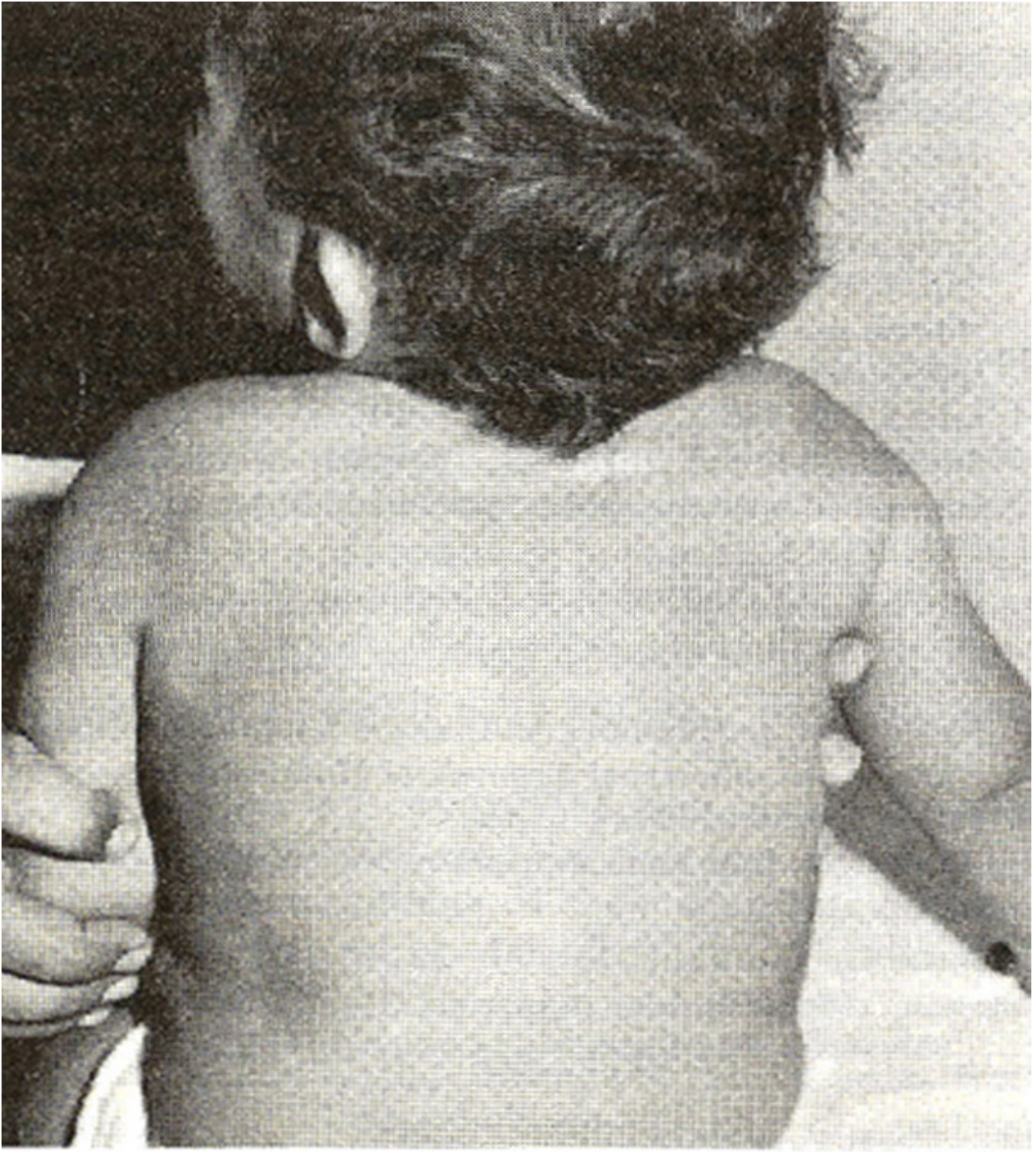


Figure 2. Kasabach Merritt syndrome (b) Post operative.

Platelet count done 4 days after surgery was 43,000/cmm. She was discharged a month later, when platelet count was 210,000. She was followed regularly in the out-patient clinic where platelet counts remained low, despite therapy with prednisone 2mg/kg/d, given for one month. At 14 months of age she was readmitted for platelet transfusions due to excessive gingival bleeding. At 17 months of age she was admitted again when she developed a hematoma over the forehead with ecchymosis over the right eye following a trauma. Platelet count was less than 5000, haemoglobin

8.2gms/dl, WBC 11,200. Single donor platelets were transfused raising the level to 1,24,000 which dropped to 35,000 after one week. She was given superficial radiation therapy of 1000 rads upto depth of 1-2cms on the front and back. Seven days after radiation platelets were 80,000. Ten days after radiation, platelet count was 1,25,000 and kept increasing. One month after radiation it was 2,95,000, and Fjnce then has remained within normal limits.

DISCUSSION

In this rare condition of infancy, thrombocytopenia is persistent, despite platelet transfusion because the transfused platelets are rapidly cleared from the circulation. Thrombi consisting chiefly of platelets have been found in some biopsy specimens. External scintillation scanning following injection of radioactive labelled platelets shows concentration of labelled platelets within the tumour². Indiumoxide has also been used in labelling for platelets scan³. The primary mechanism appears to be intravascular coagulation within the tumour. These tumours are usually solitary and subcutaneous, involving the extremities, neck and trunk, with equal frequency⁴. Visceral tumours occurring in the liver, spleen and gastrointestinal tract may be malignant. These tumours can be localized by 99mTc RBC studies, CT or MR scans.⁵ Subcutaneous and visceral lesions rarely exist in the same patient. Tumours as small as 6 cms in diameter are capable of causing severe thrombocytopenia⁶. For unknown reasons the lesions become engorged with blood prior to a bleeding episode. Platelets usually range from 10,000 to 40,000/cmm. Coagulation abnormalities of DIC may be detected in blood taken directly from the tumour. Although giant hemangiomas sometimes involute spontaneously, treatment is necessary because of tumour growth or hemorrhage, being fatal in 20% of cases. Eradication of the hemangioma is the most definite form of therapy⁷. To accomplish this a variety of therapeutic strategies have been used including mechanical cytolytic agents and pharmacologic methods. Previous reports have demonstrated that when the hemangioma is removed surgically there is prompt correction of the coagulopathy. In our patient this did not happen. An alternative approach is embolization of the hemangioma. This is risky as impairment of vascular supply to vital organs and sepsis may occur.⁷ Cytolytic agents such as radiotherapy, causes regression in many cases but it has not been shown to be universally effective. Several doses upto 1800 rads may be needed. This form of therapy is also potentially hazardous⁸. Chemotherapy represents another form of cytolytic therapy. Cyclophosphamide has been administered with positive results in some cases⁸. The most effective group of pharmacologic agents used are glucocorticosteroids. A heterogeneous response ranging from no effect to complete regression is obtained¹⁰ Other drugs like heparin, tranexamic acid and E-aminocaproic acid dipyridamole which inhibit clot lysis have been used by some investigators with different results.¹¹ Some studies have shown that lesions eventually resolve but the mechanism is poorly understood.⁸

REFERENCES

1. Kasabach, N.H. and Merritt, K.K. Capillary hemangioma with extensive purpura. *Am. J. Dis. Child.*, 1940; 59: 1063.
2. Brizel, H.E. and Raccuglia, O. Giant hemangioma with thrombocytopenia. Radioisotopic demonstration of platelet sequestration. *Blood*, 1965; 26: 751.
3. Sondel, P.M., Bitter, M.W., Wilson, D.G. and Lieberman, L.M. Use of ¹¹¹In platelet scans in the detection and treatment of KasabachMerritt Syndrome. *J. Pediatr.*, 1984; 104:87.
4. Shim, W.&R. Hemanglomas 01 Intancy complicated by thrombocytopenia. *Am. J. Surg.*, 1968; 116: 8%.

5. Wellington Lob, W., Miller, J.H., Compert, E.D. Imaging with technetium 99m - labelled erythrocytes in evaluation of Kasabach -Merritt syndrome. *Pediatrics*, 1988; 113: 856.
6. Kontras, S.B., Green, O.C., King, L and Duran, R.J. Giant hemangioma with thrombocytopenia. *Am. J. Dis. Child.*, 1963: 105: 188.
7. David, T.J., Evans, D.I. and Stevens, R.F. Hemangioma with thrombocytopenia (Kasabach-Merritt syndrome). *Arch. Dis. Child.*, 1983; 58: 1033.
8. Larsen, E.C., Zinkham, W.H., Eqqlestone, J.C. and Zitelli, B.J. Kasabach-Merritt syndrome; therapeutic considerations. *Pediatrics*, 1987; 79: 971.
9. Fost, N.C. and Esterly, N.B. Successful treatment of juvenile hemangiomas with prednisone. *J. Pediatr.*, 1968; 72: 351.
10. Edgerton, M.T. The treatment of hemangiomas; with special reference to the role of steroid therapy. *Ann. Surg.*, 1976; 183 : 517.
11. Carnelli, V., Bellini, F., Ferrari, M., Rossi, B. and Masera, O. Giant hemangioma with consumption coagulopathy. Sustained response to heparin and radiotherapy. *J. Pediatr.*, 1977; 91 : 504.