

## Piriformis Syndrome — a rare cause of extraspinal sciatica

Shumaila Arooj, Muhammad Azeemuddin

### Abstract

Piriformis syndrome is a rare entity resulting in severe unilateral isolated buttock pain shooting in nature, non discogenic in origin. MR imaging of pelvis plays an important role in such patients to see the normal anatomy of piriformis muscle and its relationship with sciatic nerve. A 35-year-old woman presented with one year history of radiating leg pain with normal MR lumbosacral spine. MRI pelvis showed an abnormal orientation of left sciatic nerve through cleaved fibers of the piriformis muscle. The patient's symptoms were relieved by surgical decompression. The purpose of this case report is to show the role and importance of MR imaging for tracing sciatic nerve and its relationship to the Piriformis muscle. MR imaging of pelvis for sciatic nerve plays an important role in symptomatic patients with isolated buttock pain having normal MRI lumbosacral spine.

**Keywords:** Piriformis muscle syndrome, Sciatic nerve, MRI.

### Introduction

Piriformis syndrome is a rare syndrome which causes severe low back pain most likely due to trapped sciatic nerve in the greater sciatic notch. It is usually caused either by the hypertrophy or inflammation of piriformis muscle or anatomical variation and relationship of sciatic nerve to muscle fibres of piriformis.<sup>1</sup> Piriformis syndrome was first described by Yeoman in 1928.<sup>2</sup> The knowledge regarding this syndrome is important especially as a radiologist, as being unaware of this entity leads to delayed or misdiagnosis. The patient at times is referred for psychiatrist consult due to mismatch of symptoms and spinal MR findings.

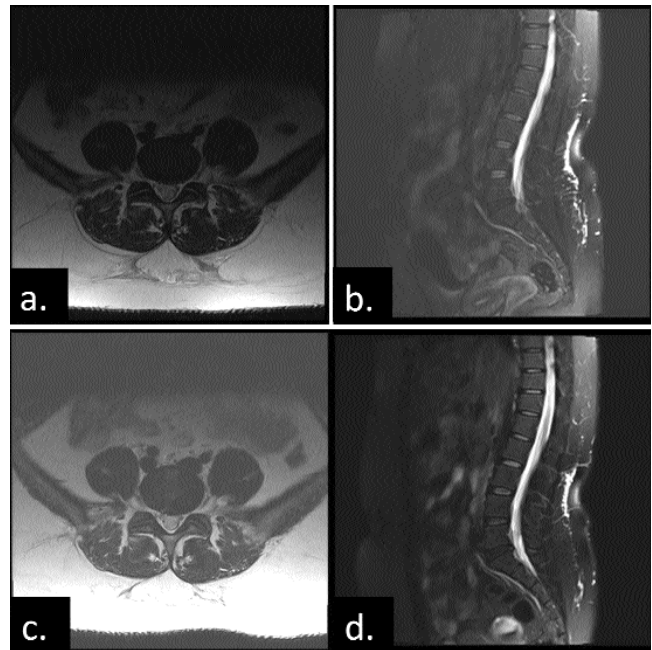
A case of Piriformis syndrome is presented in the neurology clinic with similar complaints secondary to abnormal course of sciatic nerve through cleaved fibres of piriformis muscle. It was revealed on MRI of pelvis and later confirmed at surgery.

### Case Report

A 35-year-old woman presented in the neurology clinic in April 2012 at Aga Khan University Hospital Karachi with

.....  
Department of Radiology, Aga Khan University Hospital, Karachi.

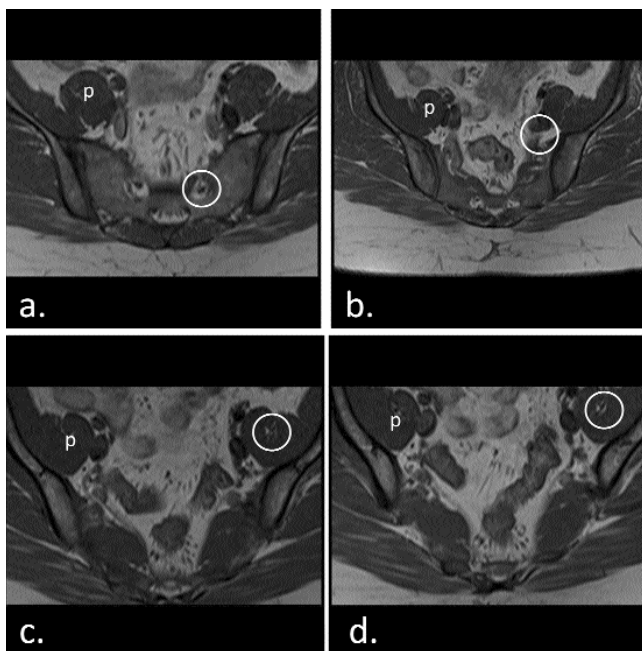
**Correspondence:** Shumaila Arooj. Email: shumaila\_aroj@hotmail.com



**Figure-1:** 35 year-old female with piriformis syndrome. Unenhanced T2-weighted (a) axial and (b) sagittal MR image of lumbosacral spine dated April 2013 show diffuse bulge with left preponderance resulting in minimal thecal sac indentation and mild bilateral lateral recess narrowing.

Repeat scan of same patient after one year dated March 2013. Unenhanced T2-weighted. (c) axial and (d) sagittal MR image of lumbosacral spine redemonstrates diffuse bulge with left preponderance resulting in minimal thecal sac indentation and mild bilateral lateral recess narrowing. No interval change.

severe disabling lower backache. According to the patient, the pain was severe and radiating to left lower limb. It was related to movement and increased by prolonged sitting and walking. There was no focal neurological deficit or urinary or faecal incontinence. MR lumbosacral spine examination was performed on 1.5 T Avanto 76x18 Siemens scanner with spine coil. Mild disc bulges were found at L4-L5 and L5-S1 levels without any neural foraminal encroachment. Representative MR images of the lumbar spine are shown in Figures-1a and 1b respectively. The patient was given analgesics and was advised to have physiotherapy. The patient again presented in March 2013 after an interval of almost one year. Her repeat MR lumbosacral spine did not show any significant interval change as shown in Figure-1(c) and (d).



**Figure-2:** 38-year-old man with piriformis syndrome. Unenhanced axial T2-weighted MR image of pelvis showing sciatic nerve from its exit from sacral foramina (a) and its variable course through the fibres of left piriformis muscle (b, c, d). Left Sciatic nerve course through piriformis muscle (encircled in yellow) and right normal piriformis muscle labeled as p.

Meanwhile she was also referred to psychiatrist as her symptoms did not match her MR picture. The patient was then referred again an MRI of pelvis in April 2013 with attention focused on the sacral plexus and piriformis muscle, to narrow the possibilities. Dedicated thin T2 weighted axial cuts through pelvis focused on the sciatic nerve were taken. This showed an abnormal orientation of sciatic nerve through cleaved/split fibers of the left piriformis muscle with normal signal intensity of sciatic nerve on T1- and T2-weighted sequences and normal surrounding structures (Figures-2a, b, c and d respectively).

The patient underwent left sciatic nerve decompression. The nerve was identified and path traced proximal to sciatic notch. Piriformis muscle was split to relieve sciatic compression. The postoperative course was uneventful. The patient reported complete relief of symptoms immediately and later five months after the operation.

## Discussion

The Piriformis Muscle originates from the pelvic surface of the sacral segments S2-S4, the adjacent sacro-iliac joint, the anterior sacro-spinous ligament and the sacro-tuberous ligament. It courses through the greater sciatic notch to insert onto the greater trochanter of the femur.

The sciatic nerve exits the pelvis below the belly of the muscle. Many congenital variations exist; the nerve may divide proximally, the nerve or a division of the nerve may pass through the belly of the muscle through its tendons or between the part of a congenitally bifid muscle.<sup>3</sup> The Piriformis Syndrome was first reported some 70 years back<sup>3</sup> in literature as a rare yet disputed cause of sciatic nerve entrapment.<sup>4</sup> It is due to an abnormality of Piriformis muscle such as its hypertrophy, inflammation or anatomical variation. This results in impingement of sciatic nerve.<sup>5</sup> It is an important cause of radiating leg pain found to be present in 6% sciatica cases seen in general practice.<sup>6</sup> The purpose of this case report is to show the importance of MR pelvis imaging for tracing normal anatomy of Sciatic nerve and its relationship to the Piriformis muscle especially in symptomatic patients. In patients with Piriformis Syndrome MR scanning of pelvis provides anatomical details in a sophisticated way revealing muscle abnormalities and the relationship of nerve course to muscle fibres as well as greater sciatic notch. Piriformis syndrome is characterized by shooting/radiating pain with numbness and tingling in unilateral hip, thigh and distribution of sciatic nerve.<sup>7</sup> These symptoms can be elicited on physical examination by digital pressure over this muscle on lateral pelvic wall. Initially the diagnosis was made only on the basis of clinical picture and imaging was ignored. Now it is an established fact that MRI is a valuable noninvasive mode of imaging not only revealing the piriformis muscle anatomy but also its relationship to sciatic nerve.<sup>4,8</sup> MRI can detect oedema of the nerve fibres and can rule out other possible etiologies like disc herniation, spinal canal stenosis, bony lesions or mass lesions.<sup>8</sup> According to a systemic review published in *Eur Spine J.* 2010,<sup>3</sup> 79 case studies with individual data reported congenital and acquired anomalies of the Piriformis Muscle with and without sciatic nerve impingement.<sup>3</sup> Jankiewicz et al reported 1 patient with an enlarged piriformis muscle with normal signal intensity. Unlike other patients described by Jankiewicz et al<sup>8</sup> and Rossi et al,<sup>4</sup> the reported patient had a piriformis muscle of normal size, but with split and cleaved fibres through which the nerve was coursing through and thus had movement associated buttock pain. The sciatic nerve had normal size and signal characteristics. The discogenic causes of radiating leg pain were confidently excluded on repeated MR LS spine over one year which confirmed no significant disease progression.

Different treatment options comprise of nonsteroidal anti-inflammatory agents and corticosteroids. Few patients benefit from injectable local anaesthetics. Physiotherapy does play a role. This patient could not be

managed conservatively. For patients with symptoms refractory to these conservative treatments, surgical release of the piriformis muscle is often recommended and has been reported to be effective in relieving the symptoms.<sup>9,10</sup> The patient underwent left sciatic nerve decompression. The nerve was identified and path traced proximally to sciatic notch. Piriformis muscle was split to relieve sciatic compression. The patient's symptoms dramatically improved. The surgical decompression outcome in our patient was excellent.

Piriformis syndrome is a clearly recognized unique disease exclusively different from the typical pattern of discogenic causes of sciatica. The sooner it is detected the better is the outcome and the more effective is the treatment.

### Conclusion

The diagnosis of Piriformis syndrome can be missed or delayed in the absence of typical clinical symptoms or absence of definite diagnostic tests. MRI can be used to make a correct diagnosis, to specify anatomic relationships for preoperative planning, and to differentiate piriformis syndrome from the more common causes of lower back pain and sciatica. Therefore, familiarity with the appearance of piriformis syndrome on MRI is important to facilitate appropriate

diagnosis and treatment.

### References

1. Ozaki S, Hamabe T, Muro T. Piriformis syndrome resulting from an anomalous relationship between the sciatic nerve and piriformis muscle. *Orthopedics* 1999; 22:771 -2.
2. Yeoman W. The relation of arthritis of the sacroiliac joint to sciatica: with an analysis of 100 cases. *Lancet* 1928; 2:1119 -22
3. Hopayian K, Song F, Riera R Sambandan S. The clinical features of the piriformis syndrome: a systematic review *Eur Spine J* 2010; 19: 2095-09.
4. Rossi P, Cardinali P, Serrao M, Parisi L, Bianco F, De Bac S. Magnetic resonance imaging findings in piriformis syndrome: A case report. *Arch Phys Med Rehabil* 2001; 82: 519-21.
5. Silver JK, Leadbetter WB. Piriformis syndrome: assessment of current practice and literature review. *Orthopedics* 1998;21:1133-5
6. Parziale JR, Hudgins TH, Fishman LM. The piriformis syndrome. *Am J Orthop* 1996; 25: 819-23
7. Rodrigue T, Hardy RW. Diagnosis and treatment of piriformis syndrome. *Neurosurg Clin N Am* 2001; 12: 311 -9.
8. Jankiewicz JJ, Hennrikus WL, Houkom JA. The appearance of the piriformis muscle syndrome in computed tomography and magnetic resonance imaging: a case report and review of the literature. *Clin Orthop* 1991; 262: 205 -9
9. Sayson SC, Ducey JP, Maybrey JB, Wesley RL, Vermilion D. Sciatic entrapment neuropathy associated with an anomalous piriformis muscle. *Pain* 1994; 59:149-52.
10. Beauchesne RP, Schutzer SF. Myositis ossificans of the piriformis muscle: an unusual cause of piriformis syndrome-a case report. *J Bone Joint Surg Am* 1997; 79:906 -10.