

The use of corticosteroids in management of Herpes associated Erythema Multiforme

Maan Yacoub AlFar,¹ Medyan AlRousan,² Zahi Almajali,³ Emil Batarseh,⁴ Rania Alsaddi⁵

Abstract

Erythema multiforme (EM) is an acute self-limiting condition considered to be hypersensitivity reaction associated commonly with infections or medications. It is characterized by skin lesions, with oral or other mucous membrane involvement. Occasionally EM may involve the mouth alone. We report a ten year-old healthy male child who developed skin lesions of both palms and soles associated with oral ulcerative lesions. The patient first noticed the lesions on the palms and soles followed by involvement of the oral cavity in form of multiple haemorrhagic crusting ulcerations involving lips and buccal mucosa. The diagnosis was established clinically based on the signs and symptoms as erythema multiforme minor associated with herpes simplex infection. Systemic corticosteroids as a treatment modality should always be considered for the treatment of erythema multiforme minor.

Keywords: Erythema multiforme, Corticosteroid, Treatment.

Introduction

Erythema multiforme (EM) is an acute hypersensitivity reaction involving mainly skin with or without oral mucosa or other mucus membrane lesions.¹ It is caused by drugs or infections mainly herpes simplex virus which is found in 70% of cases of EM.² Erythema multiforme is a disease of abrupt onset involving skin and mucous membranes where the lesions appear as red macules, papules and vesicles. Blistering and crusting may occur in the center of the lesion resulting in the characteristic target lesions.³ Recently EM has been classified as minor, major, Stevens - Johnson syndrome (SJS) and toxic epidermal necrolysis.⁴ The prevalence of oral erythema multiforme is ranging from 35% to 65% in patients with skin lesions.⁵ The prevalence of skin rashes ranged from

25% -33% in patients diagnosed as EM by oral lesions. Males are affected more frequently than females.⁶

The use of systemic corticosteroids in EM is controversial and not proved by clinical trials.^{7,8}

Most of paediatricians recommend the therapeutic and prophylactic use of acyclovir in the treatment of herpes induced EM.⁹

Case Report

A 10 year-old male child attended our Paediatric Department and Paediatric Dental Clinic at Queen Rania Al-Abdallah Hospital for Children, Amman, Jordan on the 2nd of December 2014 complaining of maculo-papular skin rash including palms and soles. The skin eruptions had central, dusky-red zone bordered by a blanched halo (white) with an erythematous zone at the periphery (target like lesion), associated with painful oral lesions in the form of multiple haemorrhagic crusting ulcerations involving lips and buccal mucosa. The lesions were circumscribed and involved less than 10% of the body surface area (Figure-1). He had a previous history of acute gingivo-stomatitis two weeks ago. The disease was diagnosed clinically as erythema multiforme minor associated with herpes simplex infection, proved by

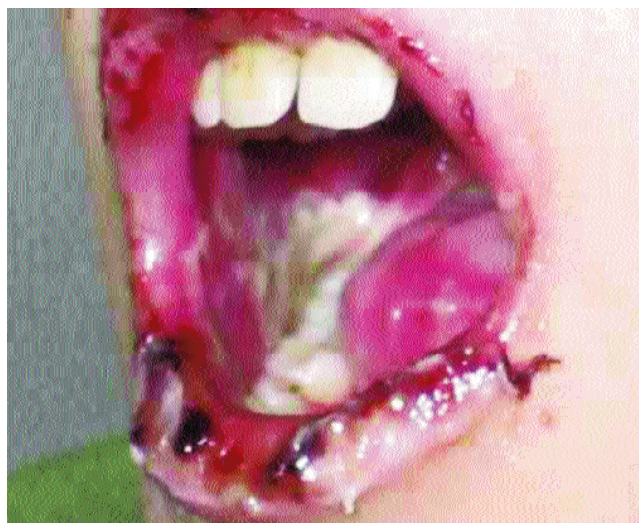


Figure-1: Intra oral hemorrhagic crusting ulcerations involving lips and buccal mucosa.

.....
 Royal Medical Services, Jordan Armed Forces, ¹Paediatric Dentistry Department, ^{3,4}Anaesthesia Department, Queen Rania Alabdallah Hospital for Children, ²Maxillofacial Department, ⁵Conservative Dentistry Department, King Hussein Medical Center, Jordan.

Correspondence: Maan Yacoub AlFar. Email: mal_far@hotmail.com

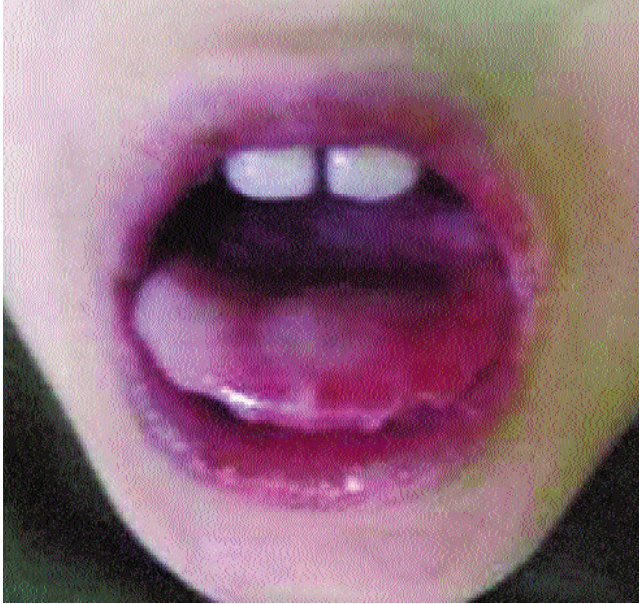


Figure-2: Five days after treatment.

detection of viral DNA by polymerase chain reaction (PCR). The patient was admitted to the hospital for five days because of decreased oral intake and was started on IV acyclovir in a dose of 10 mg/kg/ dose, Q 8 hours, oral acetaminophen 15 mg/kg, IV fluids and hydrocortisone IV injection 10 mg/kg for 5 days after which the patient showed dramatic improvement and was discharged home in a good condition with no complications (Figure-2).

Discussion

Erythema multiforme (EM) is a type of an inflammatory hypersensitivity reaction that may occur in response to drugs, infections, or medical illness. The clinical manifestations of the disease include blistering ulcers of the skin and mucous membranes.¹⁰ The age preference for these lesions is between 10-30 years.¹¹ In erythema multiforme minor, which is the least severe form of EM, the etiologic agent is most frequently an infection with herpes simplex virus. Other infectious agents which have been linked to EM include mycoplasma pneumonia, histoplasmosis, tuberculosis, Epstein-Barr virus, cytomegalovirus, varicella-zoster virus, hepatitis viruses, streptococci, parasites, and fungal agents.¹² Strong association between mycoplasma pneumonia infection with SJS had been suggested in many studies, but not with EM. Drugs have been shown ranging from 40-50% of all outbreaks of EM, and the relationship appears to be more frequent in the major forms of the disease.¹³ In the study conducted by Farthing P. et al, it was found that herpes-induced EM accounted for 20 %-50% of cases.¹⁴

The study done by Huft showed that 25% of patients presenting with skin lesions also had oral lesions.⁵

Farthing PM. et al, in a multidisciplinary study found that 70% of EM patients had oral lesions.¹⁵

Studies have shown that 40% of patients with EM present with lesions confined to the oral mucosa and lips, and have no skin involvement.^{8,16}

By review of literature, there is controversies in diagnosis and treatment of EM.

This is related in part to the difference in the terminology of some similar diseases like -EM, SJS, and Lyell's syndrome. The other part is the debate on use of corticosteroids in the treatment of EM.¹⁷

Marzano et al reported regarding the use of systemic corticosteroids to be effective only in severe cases, while the use of Acyclovir has been proven to decrease the signs and symptoms of HSV oral lesions.¹⁸

A retrospective study by Renfro et al which showed that childhood HSV-associated EM was not responsive to management with systemic corticosteroids and Acyclovir.¹⁹

In our case, steroid therapy proved to be successful.

Conclusion

The diagnosis of Erythema Multiforme should be based on the clinical signs, symptoms, and a thorough patient medical history and it is highly linked with herpes virus or mycoplasma pneumonia infections or can be drug induced erythema multiforme. Systemic corticosteroids should always be recommended as an efficient line of treatment of HSV associated EM.

References

1. Osterne R, Brito R, Pacheco I et al. Management of erythema multiforme associated with recurrent herpes infection: A case report. *J Can Dent Assoc* 2009; 75: 597-601.
2. Meechan JG. Oral Pathology and Oral Surgery. In: RR Welbury Ed. *Pediatric Dentistry*. 4th Edition. Oxford University Press, Oxford, New York. 2010; pp 339-42.
3. Aburto C, Torres R, Caro A, Salinas E. síndrome de Stevens-Johnson asociado a infección por *Mycoplasma pneumoniae* y virus herpes [Stevens-Johnson syndrome associated with *Mycoplasma pneumoniae* and herpes virus infection]. *Folia Dermatol Peru* 2005; 16: 81-4.
4. Al-Johani KA, Fedele S, Porter SR. Erythema multiforme and related disorders. *Oral Surg Oral Med Oral Pathol Oral Radiol Endod* 2007; 103: 642-54.
5. Huff JC, Weston WL. Recurrent erythema multiforme. *Medicine* 1989; 68: 133- 40.
6. Farthing p, Bagan J-V, Scully C. Mucosal Diseases Series, Erythema Multiforme. *Oral Dis* 2005; 11: 261-7.
7. Renfro K, Grant-Kels M, Feder HM, Daman LF. Controversy: are

- systemic steroids indicated in the treatment of erythema multiforme? *Pediatr Dermatol* 1989; 6: 43-7.
8. Scully C, Bagan J. Oral mucosal diseases: Erythema multiforme. *Br J Oral Maxillofacial Surg* 2008; 46: 90-5.
 9. Ayangco L, Rogers RS III. Oral manifestations of erythema multiforme. *Dermatol Clin*. 2003; 21: 195-205.
 10. Darby ML, Walsh MM, editors. *Dental hygiene theory and practice*. 3rd ed. St. Louis (MO): Saunders Elsevier; 2010.
 11. Mulvey JM, Padowitz A, Lindley-Jones M, Nickels R. *Mycoplasma pneumoniae* associated with Stevens Johnson syndrome. *Anaesth Intensive Care* 2007; 35: 414-7.
 12. DeLong L, Burkhart NW. *General and oral pathology for the dental hygienist*. 2nd ed. Baltimore (MD): Wolters Kluwer Health/Lippincott Williams & Wilkins; 2013.
 13. Sanchis JM, Bagan JV, Gavaldà C, Murillo J, Diaz JM. Erythema multiforme: diagnosis, clinical manifestations and treatment in a retrospective study of 22 patients. *J Oral Pathol Med* 2010; 39: 747-52.
 14. Regezi JA, Sciubba J. *Oral Pathology. Clinical-Pathologic Correlations*. 2nd Ed. Philadelphia: WB Saunders Co, 1993; pp 1-15.
 15. Farthing PM, Maragou P, Coats M, Tatnall F, Leigh IM, Williams DM. Characteristics of the oral lesions in patients with cutaneous recurrent erythema multiforme. *J Oral Pathol Med* 1995; 24: 9-13.
 16. Joseph TI, Vargheese G, George D, Sathyan P. Drug induced oral erythema multiforme: A rare and less recognized variant of erythema multiforme. *J Oral Maxillofac Pathol* 2012; 16: 145-8.
 17. Rasmussen JE. Erythema multiforme in children: response to treatment with systemic corticosteroids. *Br J Dermatol* 1976; 95: 181-6.
 18. Marzano AV, Frezzolini A, Caproni M, Parodi A, Fanoni D, Quaglino P, et al. Immunohistochemical expression of apoptotic markers in drug-induced Erythema Multiforme, Stevens-Johnson Syndrome and toxic epidermal necrolysis. *Int J Immunopathol Pharmacol* 2007; 20: 557-66 .
 19. Renfro K, Grant-Kels M, Feder HM, Daman LF. Controversy: are systemic steroids indicated in the treatment of erythema multiforme? *Pediatr Dermatol* 1989; 6:43-7.
-