

## Ponseti treatment for idiopathic clubfoot deformity — Role of secondary care hospitals

Shahid Muhammad Khan, Safdar Muhammad Khanzada

### Abstract

Ponsetti method has an excellent outcome in the management of club foot. The presented case series will spread awareness by showing the results of this technique used in secondary care centers, to share the burden of care from tertiary care hospitals. A descriptive case series was conducted at Shah Bhitai District Government Hospital, Hyderabad Sindh. Patients presenting with Idiopathic Clubfoot between birth and 12 months of age of either sex were included. The patients were followed for 5 months from the removal of their last cast. We were able to achieve correction in 80.6 % of the patients. Tendo Achilles tenotomy was performed in 90.3% of the patients. Ponseti method is a reliable and efficient way to manage club foot deformity. Spreading this message among primary and secondary health care systems will help to overcome this problem more effectively.

**Keywords:** Ponseti method, idiopathic club foot, Secondary care hospital.

### Introduction

Idiopathic club foot deformity is a disabling problem with an incidence of 0.9/1,000 live to 7/1,000 live births with approximately 50 % cases involving bilaterally.<sup>1,2</sup> Different techniques for management are in practice, most involving manipulation and casting. In many institutions, manipulation and serial casting require many months of treatment and frequently result in incomplete or defective corrections.<sup>3,4</sup> As a result, extensive corrective surgery is indicated in 50% to 90% of the cases, often with disturbing failures and complications.<sup>5-9</sup> In 1950s, Ignacio Ponseti (1914-2009), a Spanish physician developed the Ponseti Method for the non-operative treatment of clubfoot.<sup>10</sup> Currently this method is the gold standard of clubfoot treatment.<sup>11</sup> Ponseti method comprises of two phases, treatment and maintenance phase. In treatment phase serial manipulations and casting are done to gradually correct the deformity and a percutaneous tenotomy of the Achilles tendon to correct the residual

ankle equinus. In maintenance phase foot abduction brace is worn for 2-3 years to maintain the correction.<sup>12</sup> Using Ponseti method correctly including initial casting, compliance with brace and treatment of recurrence by recasting and/or Achille's tenotomy the success rate was reported to be 93%.<sup>13</sup> Severity of club foot deformity is most commonly assessed by Pirani scoring system.<sup>14</sup> A total score of six represents a severe clubfoot with a score of zero representing a normal foot.

In this study we are sharing short term results of our experience with the Ponseti method in correcting idiopathic clubfoot deformity in a secondary care center to attract other secondary care centers to offer the same, so that burden of care can shared from tertiary care hospitals. Objective of this study is basically spreading the awareness regarding the management of club foot by Ponseti method in secondary care centers where appropriate concerned faculty and staff is available.

### Cases

The study was conducted at Shah Bhitai District Government Hospital, Hyderabad Sindh, from December 2013 to November 2014. It was a descriptive case series study. This center is offering multidisciplinary services in the field of medicine, surgery and allied specialties. Patients presenting with Idiopathic Clubfoot between birth and 12 months of age of either sex were included in the study. Patients having other congenital problems like Arthrogryposis, Meningomyelocele, spina bifida and patients who had undergone previous surgical treatment for management of club foot were excluded from the study. Course of treatment, including possible need of Achille's tendon tenotomy, was explained to the parents and a written informed consent was taken. All the patients were managed by qualified orthopaedic specialists. Patients were classified according to the Pirani scoring system<sup>14</sup> and then manipulation followed by weekly above-knee castings were done. Two days in a week were fixed for cast application in OPD so that patient's families could also interact with each other and share their experience. On an average of 4th to 6th cast, application, equinus was assessed and if required percutaneous Achilles' tenotomy under local anaesthesia was done and

.....  
Shah Bhitai District Government Hospital, Hyderabad, Sindh.

**Correspondence:** Shahid Muhammad Khan. Email: khan.shahid1945@gmail.com

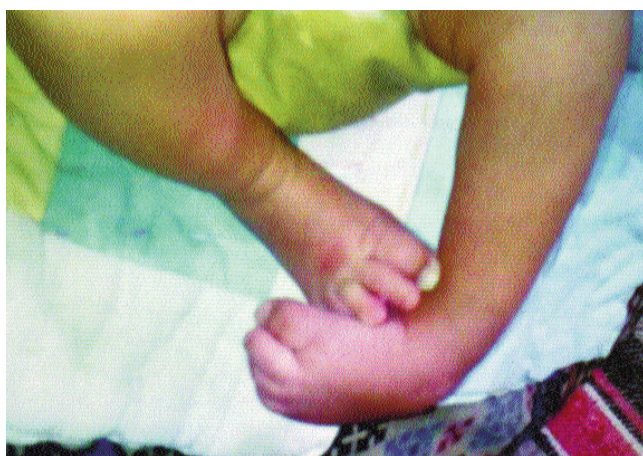cast was re-applied. Patient's progress was monitored regularly every week by Pirani scoring system. The final outcome (as indicated by Pirani score) was recorded at the time of removal of final cast. Feet were then placed in the foot abduction brace. Parents were advised to keep the feet of the child in the brace for 23 hours in a day for the first 3 months and then for 12 to 14 hours during the night and napes for the next 3 years. The patients were followed till 5 months from the removal of their last cast. After starting brace treatment, patients were called first at two weeks for the first month and then every 4 weeks for the following 4 months. Data was analyzed with the help of SPSS version 10.

## Results

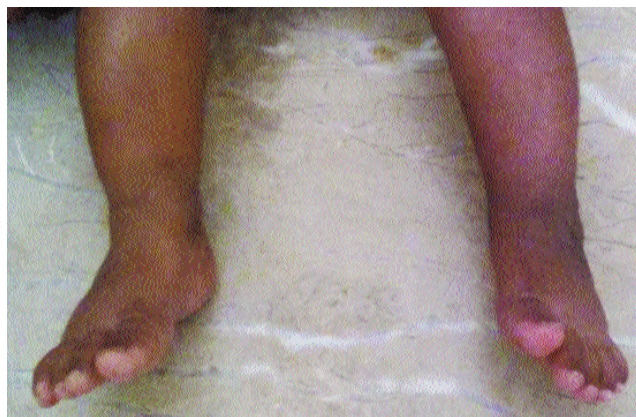
Out of 31 patients, there were 19 (61.3%) male and 12 (38.7%) female patients (Table-1). Right side was involved in 14 (45.2 %) patients, left side in 7 (22.6%) patients while 10 (32.3%) patients had bilateral deformity. Family history of club foot was positive in 16% patients (5 out of 31). Mean age of the patients at start of treatment was

**Table-1:** Results.

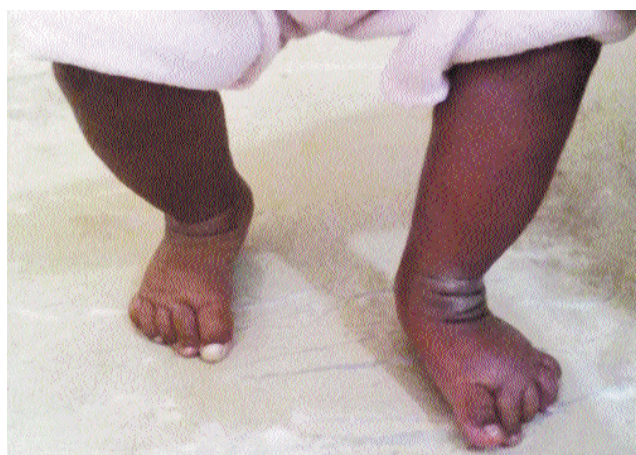Total number of patients	31
Male	19 (61.3%)
Female	12 (38.7%)
Family history of club foot	Positive in 5 (31%)
History of previous treatment	Present in 64.5%
Bilateral involvement	10 (32.3%)
Right foot involvement	14 (45.2%)
Left foot involvement	7 (22.6%)
Mean Pirani score at start of treatment	5.71±0.52 (Range 4-6).
Mean age at start of treatment	5.58±5.16 weeks (Range 1-28 weeks)
Total number of casts required (mean)	6.29±0.93 (Range 5-9)
Tendo Achilles Tenotomy required	90.3% patients



**Figure-1:** A child with typical club foot deformity involving left foot at presentation.

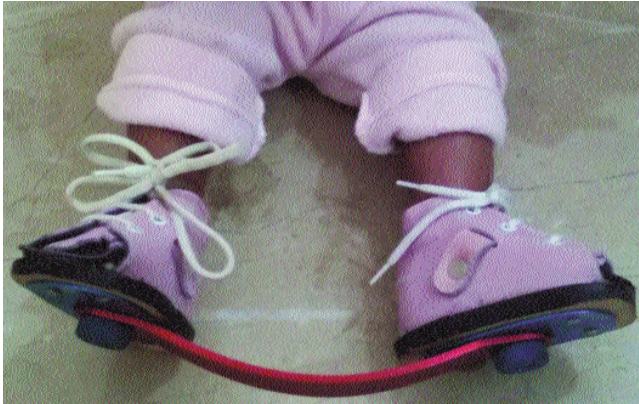

**Figure-2:** Child underwent Ponseti treatment and deformity gradually improved.



**Figure-3:** After 4 casts. Same child after completion of treatment with full correction of deformity.

5.58±5.16 weeks (Range 1-28 weeks). Patients had a history of different types of treatment before presentation to our institute. Seven (22.6%) patients had history of serial manipulations alone, 9 (29%) patients had manipulation and below knee casting, 4 (12.9%) patients had above knee casting while 11 (35.5%) patients had no treatment. Mean Pirani score at start of treatment in our institute was 5.71±0.52 (Range 4-6). Average number of casts applied (per patient) to achieve correction was 6.29±0.93 (Range 5-9). Tendo Achilles tenotomy was performed in 90.3% of the patients (28 out of 31 patients). Timing of Tendo Achilles tenotomy was after the 4th cast in 61.3% of the patients, after 3rd cast in 32.3% of the patients and after 5th cast in 6.5% of the patients. We were able to achieve correction (i.e. Pirani score < 1) in 25 (80.6 %) (Figure-1-4). In rest of the 6 cases who developed



**Figure-4:** The child in maintenance phase with shoe brace.

recurrent deformity (i.e. Pirani score > 2) 4 patients were lost to follow-up. Two patients who had recurrent deformity were managed successfully with repeat manipulation and casting.

## Discussion

The Ponseti method has shown excellent outcome for the management of club foot and its ability to radically decrease the need for extensive corrective surgery.<sup>15</sup> The technique is economical and easy to learn as well by allied health professionals.<sup>16</sup>

In this study we are sharing our experience with Ponseti method of treatment for club foot deformity correction. Mean number of casts required in our study was  $6.29 \pm 0.93$  (Range 5-9) which was similar to other studies.<sup>16,17</sup> We were able to achieve correction of the deformity in 25 out of 31 patients (80.6 %). Similar results have been shown by Kampa et al<sup>17</sup> and Morcuende et al.<sup>18</sup> Achilles tenotomy was done in 90.3% which is also comparable to other studies.<sup>16</sup> Six patients developed recurrence of the deformity. Main reason of recurrence was found to be non-compliance with the use of orthosis. This reason has been widely reported to be the main factor causing failure of the technique.<sup>19</sup> The limitations of our study were a small number of patients and short follow-up period.

The basic idea of this study is spreading the awareness regarding Ponseti technique among primary and secondary health centers that has number of implications. As the secondary health centers have some interaction with primary care physicians, educating the primary care physicians regarding Ponseti method may lead to early referral from these basic health units. For general public, excellent outcome of this technique reassures them the safety and efficacy of this method and thereby asking

other affected families to adopt this line of management despite wide variety of treatment being available. Another important aspect of this technique is that it can be learned easily so the results can be replicated in other institutions especially the secondary health care systems where required faculty and staff is available. The technique is especially suited for developing countries, where people mostly belong to low socioeconomic status, there are few skilled orthopaedic surgeons in remote areas and where tertiary care centers are facing enormous number of other serious health problems. By increasing awareness for this technique among primary and secondary health centers resources of tertiary care system can be utilized for more complicated and difficult health problems. Furthermore decrease travel time to a secondary health center in comparison to a tertiary care center results in decreased physical and financial burden to the families and leads to increased compliance to the treatment which demands several visits that need to be regular to achieve the desired results.<sup>20</sup>

## Conclusion

To conclude, Ponseti method for the treatment of club foot deformity is reliable and efficient which also radically decreases the need for traditional extensive corrective surgeries. Spreading this message among primary and secondary health care systems will help to overcome this problem more effectively and will also help to share the burden of care from tertiary hospitals so that their resources can be utilized to address more difficult health problems.

## Acknowledgements

There are no acknowledgements.

## References

1. Beals RK. Club foot in the Maori: a genetic study of 50 kindreds. *N Z Med J* 1978; 88: 144-6
2. Mittal RL, Sekhon AS, Singh G, Thakral H. The prevalence of congenital orthopaedic anomalies in a rural community. *Int Orthop* 1993; 17: 11-2.
3. Kite JH. Nonoperative treatment of congenital clubfoot. *Clin Orthop Relat Res* 1972; 84: 29-38.
4. Dimeglio A, Bonnet F, Mazeau P, De Rosa V. Orthopaedic treatment and passive motion machine: consequences for the surgical treatment of clubfoot. *J Pediatr Orthop B* 1996; 5:173-80.
5. Turco VJ. Resistant congenital club foot--one-stage posteromedial release with internal fixation. A follow-up report of a fifteen-year experience. *J Bone Joint Surg Am* 1979; 61: 805-14.
6. Crawford AH, Marxen JL, Osterfeld DL. The Cincinnati incision: a comprehensive approach for surgical procedures of the foot and ankle in childhood. *J Bone Joint Surg Am* 1982; 64: 1355-8.
7. Simons GW. Complete subtalar release in club feet. Part I--A preliminary report. *J Bone Joint Surg Am* 1985; 67: 1044-55.
8. Green AD, Lloyd-Roberts GC. The results of early posterior release in resistant club feet. A long-term review. *J Bone Joint Surg Br* 1985; 67: 588-93.

9. Aronson J, Puskarich CL. Deformity and disability from treated clubfoot. *J Pediatr Orthop* 1990; 10: 109-19.
  10. Ponseti IV. Treatment of congenital club foot. *J Bone Joint Surg Am* 1992; 74: 448-54.
  11. Ponseti IV, Smoley EN. The classic: congenital club foot: the results of treatment. *Clin Orthop Relat Res* 2009; 467: 1133-45.
  12. Gerlach DJ, Gurnett CA, Limpaphayom N, Alaei F, Zhang Z, Porter K, et al. Early results of the Ponseti method for the treatment of clubfoot associated with myelomeningocele. *J Bone Joint Surg Am* 2009; 91: 1350-9.
  13. Abdelgawad AA, Lehman WB, van Bosse HJ, Scher DM, Sala DA. Treatment of idiopathic clubfoot using the Ponseti method: minimum 2-year follow-up. *J Pediatr Orthop B* 2007; 16: 98-105.
  14. Dyer PJ, Davis N. The role of the Pirani scoring system in the management of club foot by the Ponseti method. *J Bone Joint Surg Br* 2006; 88: 1082-4.
  15. Lehman WB, Mohaideen A, Madan S, Scher DM, Van Bosse HJ, Iannaccone M, et al. A method for the early evaluation of the Ponseti (Iowa) technique for the treatment of idiopathic clubfoot. *J Pediatr Orthop B* 2003; 12: 133-40.
  16. Gupta A, Singh S, Patel P, Patel J, Varshney MK. Evaluation of the utility of the Ponseti method of correction of clubfoot deformity in a developing nation. *Int Orthop* 2008; 32: 75-9.
  17. Kampa R, Binks K, Dunkley M, Coates C. Multidisciplinary management of clubfeet using the Ponseti method in a district general hospital setting. *J Child Orthop* 2008; 2: 463-7.
  18. Morcuende JA, Dolan LA, Dietz FR, Ponseti IV. Radical reduction in the rate of extensive corrective surgery for clubfoot using the Ponseti method. *Pediatrics* 2004; 113: 376-80.
  19. Dobbs MB, Rudzki JR, Purcell DB, Walton T, Porter KR, Gurnett CA. Factors predictive of outcome after use of the Ponseti method for the treatment of idiopathic clubfeet. *J Bone Joint Surg Am* 2004; 86: 22-7.
  20. Docker, C. E, Lewthwaite, S, Kiely, N. T. Ponseti treatment in the management of clubfoot deformity - a continuing role for paediatric orthopaedic services in secondary care centres. *Ann R Coll Surg Engl* 2007; 89: 510-2.
-