

## A rare case: Congenital thoracic ectopic kidney with diaphragmatic eventration

Harun Arslan,<sup>1</sup> Cengiz Aydogan,<sup>2</sup> Cihan Örcen,<sup>3</sup> Edip Gönüllü<sup>4</sup>

### Abstract

Thoracic ectopic kidney is a rare developmental anomaly that is the least frequent one among all forms of ectopic kidneys. The condition is generally asymptomatic. If a kidney image is missing on one side in renal pelvic region in sonographic examination, the possibility of thoracic ectopic kidney should be taken into consideration. For final diagnosis, chest radiography and thorax computerised tomography should be obtained. We herein report a rare case of intra-thoracic kidney accompanied by diaphragm eventration.

**Keywords:** Diaphragm eventration, Congenital, Thoracic ectopic kidney, CT.

### Introduction

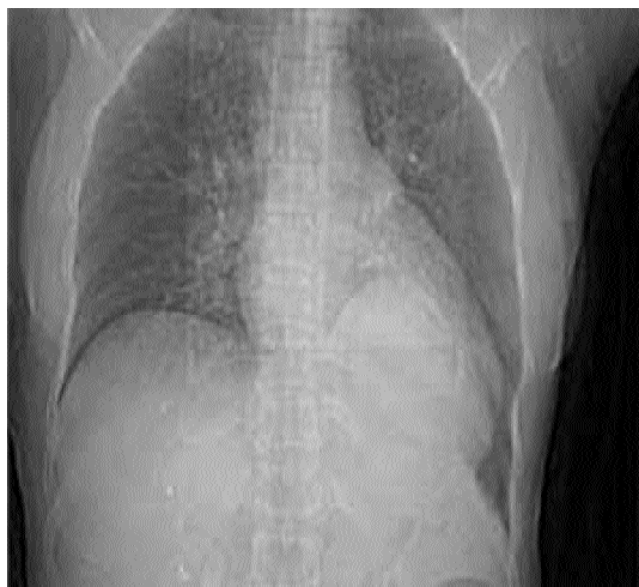Congenital intra-thoracic ectopic kidney is a rare developmental anomaly. It is the least reported one among all ectopic kidney forms. It is generally asymptomatic and diagnosed incidentally in chest radiograph.<sup>1</sup> Folic acid or vitamin A deficiency during intrauterine period as well as exposure to teratogenic medicines, chemical substances, ionised rays, infections or infestations such as *Schistosoma haematobium* or malaria during intrauterine period are thought to play a role in etiopathogenesis. Ectopic kidney may be a part of a syndrome involving complex multiple congenital anomalies.<sup>2</sup> We herein report a rare case of intra-thoracic kidney which was accompanied by diaphragm eventration.

### Case Report

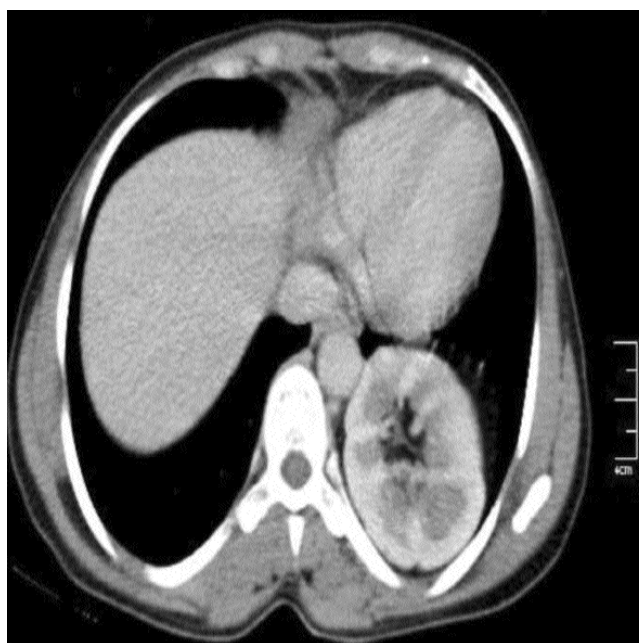
A 32-year-old woman presented to pulmonology outpatient clinic with occasional dry cough and non-specific chest pain. Physical examination revealed minimally decreased respiratory sounds at left acromioclavicular (AC) lower zone. This finding necessitated a posterior-anterior (PA) chest radiograph which showed diaphragm eventration on the left side,

<sup>1</sup>Department of Radiology, <sup>3</sup>Department of Pulmoner Diseases, <sup>4</sup>Department of Anesthesiology, Van Region Training and Research Hospital, <sup>2</sup>Department of Radiology, Van Ipekyolu State Hospital, Van, Turkey.

**Correspondence:** Edip Gönüllü. Email: edipgonullu@gmail.com



**Figure-1:** In posterior-anterior (PA) chest radiography, diaphragm eventration and opacity increase are observed at adjacent left paracardiac region.



**Figure-2:** In computed tomography (CT), an image that is compatible with malrotated ectopic left kidney was seen at adjacent paracardiac region at posterior half of diaphragm on left.

and a radiopaque mass in the adjacent paracardiac region (Figure-1). Computerised tomography (CT) scan with intravenous (IV) contrast was performed to evaluate the nature of the mass lesion. Abdominal ultrasound failed to show a kidney image on the left side in renal or pelvic region. A contrast enhanced CT scan showed a left kidney in an intra-thoracic location in the left paracardiac region (Figure-2). The size of kidney and the contrast opacification were normal.

## Discussion

Ectopic kidney can be in the pelvic, iliac or abdominal region, or can be contralateral, or cross-located. The most frequently reported subtype of ectopic kidney is the pelvic kidney. Thoracic kidney is a very rare condition.<sup>1,3</sup> Embryological basis of intra-thoracic kidney is not well known. Excessive ascent of kidney from sacral region to lumbar region is suggested. This process is normally completed by eighth gestational week. It is suggested that a more rapid ascent of a kidney during this process before closure of the diaphragm results in this anomaly.<sup>2,4</sup> Defective development or delayed closure of the pleuroperitoneal membrane was suggested as another factor.<sup>2,5</sup> However, the validity of the second assumption is disputable, because the co-existence of intra-thoracic kidney and congenital diaphragmatic hernia is a very rare condition.<sup>5,6</sup> Today, more widely accepted mechanism for this condition is that the developmental phases of adrenal gland and liver alter the posture of kidney, and the kidney develops secondary to the cord. Nevertheless, none of these mechanisms is completely ruled out, and it is reported that each can take part in the development of an ectopic kidney.<sup>5</sup>

Simple thoracic kidney is generally asymptomatic. It does not cause dysfunction of kidney. Rarely, it can lead to serious respiratory distress.<sup>2,4,5</sup> Generally, it is diagnosed incidentally later in life when various health issues occur following a trauma or invasive procedures involving the urinary system. Therefore, overall frequency is not known precisely.<sup>2,4</sup> In an earlier autopsy series, ectopic kidney was reported in 1/1200 to 1/500 of autopsies. However, autopsy studies do not indicate the real frequency of ectopic kidney.<sup>2</sup> Various studies demonstrated that the occurrence of ectopic kidney varies from population to population.<sup>2,7,8</sup> In a retrospective study, 25,551 prenatal cases were scanned by ultrasonography, and the frequency of pelvic ectopic kidney was reported to be 1/1965.<sup>7</sup> One study<sup>8</sup> based on screening of 132,686 healthy school children by ultrasonography explored frequency of kidney anomalies, and detected ectopic kidney in 30 cases.

Only one of these cases was thoracic ectopic kidney. In the radiological studies carried out in recent years, frequency of ectopic kidney is 0.023% to 0.35%.<sup>2</sup> As in our case, it is mostly observed on the left side (61%). It can also be located on the right side (36%) or bilaterally (2%).<sup>4,6</sup>

For the diagnosis of thoracic kidney, radiography can be used. As in our case, in PA chest radiography, it draws attention as a well-circumscribed mass close to midline in the thoracic cavity. In some cases, diaphragm elevation may be the only finding. Posterior mediastinal neuroblastoma, ganglioneuroma, neurogenic cyst, meningeal cyst and Bochdalek hernia may also form similar radiological findings. Therefore, IV pyelography, CT and other techniques are used complementarily for differential diagnoses.<sup>1,6,8,9</sup>

Relationship of intra-thoracic kidney with diaphragm may vary from case to case.<sup>4</sup> Our case was accompanied by eventration of diaphragm. It is caused by insufficiency of muscle fibres due to paralysis, aplasia or atrophy in the prenatal period and it is a very rare condition. As in our case, diaphragm eventration is usually asymptomatic. Mostly, it does not require a specific treatment.<sup>10</sup> In severe cases with symptoms, plication surgery generally relieves the condition. It is very hard to distinguish congenital diaphragm eventration from congenital diaphragm hernia. However, this differentiation is very critical for treatment. The natural course of eventration is better than of the diaphragm hernia.<sup>11</sup> In our patient, the possibility of diaphragm hernia was excluded by barium passage graphy of the colon.

It is reported that ectopic kidney may be seen together with multiple system anomalies.<sup>1</sup> In our case, ectopic kidney was accompanied by bilateral pes equinovarus and dysplasia of the hip. Skeletal anomalies found in our case were compatible with literature.<sup>1,9</sup>

## Conclusion

Although intra-thoracic kidney is a rare condition, but it should be kept in mind in differential diagnosis of patients with a mediastinal mass in chest radiography.

**Financial Disclosure:** No financial disclosures.

**Conflict of Interest:** None.

## References

1. Aydin HI, Sancı SU, Alpay F, Gökçay E. Thoracic ectopic kidney in a child: a case report. *Turk J Pediatr* 2000; 42: 253-5.
2. Magak P, King CH, Ireri E, Kadzo H, Ouma JH, Muchiri EM. High prevalence of ectopic kidney in Coast Province, Kenya. *Trop Med Int Health* 2004; 9: 595-600.

3. Yalcinba? K, ?a?maz H, Canbaz S. Thoracic left kidney: a differential diagnostic dilemma for thoracic surgeons. *Ann Thorac Surg* 2001; 72: 281-3.
  4. Liddell RM, Rosenbaum DM, Blumhagen JD. Delayed radiologic appearance of bilateral thoracic ectopic kidneys. *Am J Roentgenol* 1989; 152: 120-2.
  5. Sözübir S, Demir H, Ekingen G, Giiivenc BH. Ectopic thoracic kidney in a child with congenital diaphragmatic hernia. *Eur J Pediatr Surg* 2005; 15: 206-9.
  6. Eren S, Polat B. Congenital intrathoracic ectopic kidney. [Online] 2003 [Cited 20 Feb 2015]. Available from URL: <http://www.eurorad.org/eurorad/case.php?id=I 895>
  7. Hill LM, Grzybek P, Mills A, Hogge WA. Antenatal diagnosis of fetal pelvic kidneys. *Obstet Gynecol* 1994; 83: 333-6.
  8. Sheih CP, Liu MB, Hung CS, Yang KH, Chen WY, Lin CY. Renal abnormalities in schoolchildren. *Pediatrics* 1989; 84: 1086-90.
  9. Hithaishi C, Padmanabhan S , Kumar BS, Kalawat TC, Venkatarammappa M, Kumar VS. Ectopic thoracic kidney - a case report. *Indian J Nephrol* 2003; 13: 79-80
  10. Deslauriers J. Eventration of the diaphragm. *Chest Surg Clin N Am* 1998; 8: 315-30.
  11. Yang JI. Left diaphragmatic eventration diagnosed as congenital diaphragmatic hernia by prenatal sonography. *J Clin Ultrasound* 2003; 31: 214-7.
-