

Henoch-Schönlein purpura without typical lesions, presenting with gastrointestinal manifestations and kidney involvement following influenza - A case report

Chan Won Park,¹ In Seok Lim,² Sin Weon Yun,³ SooAhn Chae,⁴ Na Mi Lee,⁵ Dae Yong Yi⁶

Abstract

We report a case of Henoch-Schönlein purpura (HSP) presenting without typical skin lesion; atypical symptoms initially appeared following influenza infection. A 4-year-old girl with influenza presented with epigastric pain and vomiting. On physical examination, there was epigastric tenderness, but no other signs, such as skin rash. On the second day, she vomited blood 10 times. Ultrasonography indicated focal bowel wall thickening in the right upper quadrant. Esophagogastroduodenoscopy showed oedematous and purpuric mucosa in the gastric pylorus and duodenum. Steroid therapy was initiated, and symptoms improved, but microscopic haematuria persisted. Even in the absence of typical purpura, if any gastrointestinal symptoms are observed and HSP is suspected, aggressive diagnostic tools must be considered, including ultrasonography or endoscopy. With only a few reported cases of HSP associated with influenza infection, this is the first reported case with gastrointestinal involvement and renal impairment, but without typical skin lesions.

Keywords: Henoch-Schönlein Purpura, Influenza, Esophagogastroduodenoscopy, Hematemesis, Proteinuria.

Introduction

Henoch-Schönlein Purpura (HSP) is the most common systemic vasculitis in childhood. The annual incidence is 13-20 per 100,000 children.¹ It is characterized by non-thrombocytopenic palpable purpura, and it can be accompanied by arthritis, bowel angina and haematuria/proteinuria.² The course of HSP is usually benign and self-limiting. Joint involvement occurs in 60-84% of cases and appears with palpable purpura as the initial symptom. But progressive impairment of renal function, gastrointestinal (GI), and central nerve system involvement can occur.³ Gastrointestinal system is affected in up to 76% of patients varying from abdominal pain, nausea, and vomiting to intestinal haemorrhage or

perforation, intestinal obstruction, intussusception, pancreatitis, and hydrops of the gallbladder. The reported incidence of renal disease ranges from 20% to 100%.⁴

The etiology and pathogenesis remain unclear. It is known that HSP is associated with an immune system abnormality and infections precede HSP, especially upper respiratory infections caused by streptococcus, parainfluenza virus, and parvovirus B19, among others.^{2,5} Hope-Simpson and Higgins found that approximately 8% of influenza B infections and 2% of influenza A virus infections are associated with rash.⁶ However, even during the pandemic 2009 H1N1 virus infection, HSP following influenza infection was so rare that only one HSP case was reported.⁷

We encountered a rare and interesting case with atypical symptoms after influenza infection, which is being presented.

Case Report

A 4-year-old girl without significant past history, was presented with epigastric pain and vomiting in March 2014. She was seen at a local clinic after three days of fever, and was diagnosed with influenza infection by an antigen test. She consumed oseltamivir (Tamiflu®) and the fever subsided. On physical examination, there was epigastric tenderness, but no other signs, such as skin rash. The overall initial laboratory findings were normal: blood urea nitrogen, 9 mg/dL and creatinine, 0.19 mg/dL. However, high sensitivity C-reactive protein level increased to 6.31 mg/L. Urinalysis showed microscopic haematuria, pyuria, and proteinuria; red blood cells, 10-19/high power field (HPF); white blood cells, 10-19/HPF; and protein +1, 30 mg/dL.

Supportive management such as fasting, fluid therapy and proton pump inhibitor were instituted, but epigastric pain and vomiting continued. On the second day of hospitalization, she vomited blood 10 times. On the third day of hospitalization, the coagulation panel was normal: international normalized ratio, 1.08; activated partial thromboplastin time, 35.1 seconds. However, the D-dimer was elevated to 2.5µg/mL. Abdominal ultrasonography showed focal bowel wall thickening in the right upper

¹⁻⁶Department of Pediatrics, Chung-Ang University Hospital, ²⁻⁴College of Medicine, Chung-Ang University, Seoul, Korea.

Correspondence: Dae Yong Yi. Email: meltemp2@hanmail.net

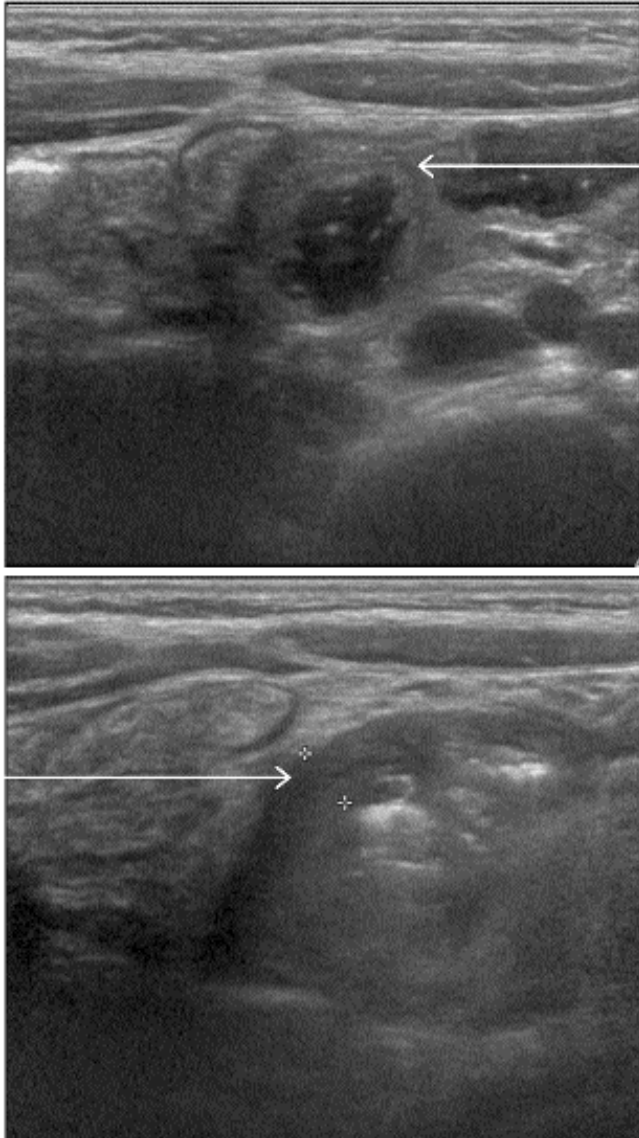


Figure-1: Abdominal ultrasonography. Focal bowel wall thickening is observed in the right upper quadrant.

quadrant, including the duodenum, suggesting bowel wall oedema or intramural haemorrhage (Figure-1).

HSP was then considered as a diagnosis, without typical palpable purpura, but with involvement of the GI tract and kidneys. Esophagogastroduodenoscopy (EGD) was performed, with no lesions causing GI bleeding in the esophagus or body of the stomach. However, the gastric pylorus and duodenum had oedematous and purpuric mucosa (Figure-2). Intravenous steroid therapy (methylprednisolone 2mg/kg/day) was initiated for 4 days, and bloody vomiting and epigastric pain improved. After that, Steroid was administered by tapering dose. D-

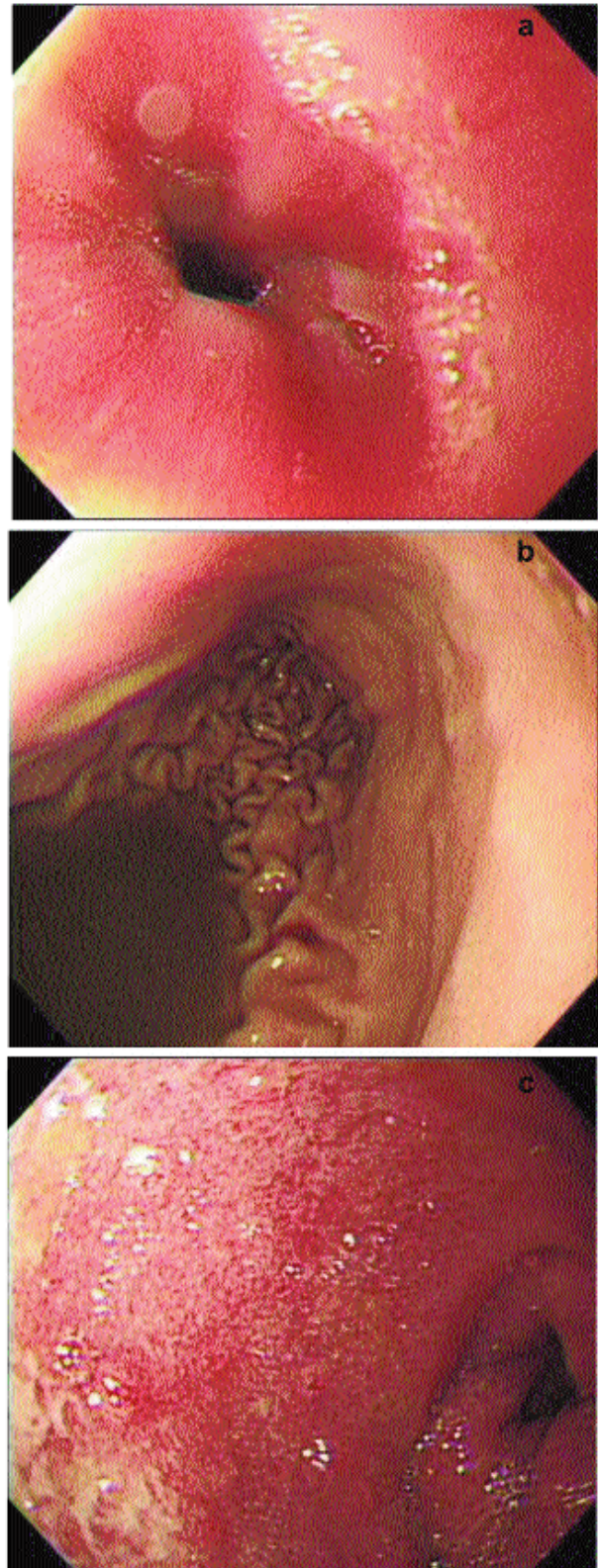


Figure-2: Esophageogastroduodenoscopy. There were no lesions causing GI bleeding in the esophagus (a) or body of the stomach (b). In the gastric pylorus (c) and duodenum, there was edematous purpuric mucosa.

dimer level decreased to 1.3µg/mL. The day after the treatment was started, post auricular single purpuric lesion appeared, but improved in two days. She started a diet on the fifth day of hospitalization, and had no progression of GI symptoms.

On the eighth day of hospitalization, she was discharged, but microscopic haematuria persisted. Since discharge, she has had out-patient monitoring for renal complications of HSP nephritis.

Written informed consent was taken from the parents for presenting this case report.

Discussion

HSP is the most common vasculitic disease of childhood. It is diagnosed according to the clinical course, and there is no test specific for HSP. However, abdominal ultrasonography can be useful as the initial study. Fibrin degradation products (FDPs) levels, including D-dimer, or EGD are also helpful in the diagnosis.⁸ IgA-dominant immune deposits in pathology finding are useful to diagnose HSP. They affect small vessels; typically involves skin, gut, and glomeruli.²

Though the pathogenesis of HSP is vasculitis, but coagulation test results, except FDPs are generally normal.⁹ FDPs, including D-dimer, are significantly increased in a very high proportion of HSP patients.⁸ These specific laboratory findings — normal coagulation assays with elevated FDPs and D-dimer — are helpful in diagnosing HSP such as our patient.

Renal involvement is the most serious long-term complication, and usually develops within the first four weeks of the illness. It can rarely appear over the next two months.¹⁰ Factors associated with HSP nephritis include persistent or recurrent purpura, older age at onset, severe abdominal symptoms, and central nervous system involvement.³

Herein, we describe a patient who was diagnosed with atypical HSP without palpable purpura, presenting with GI and renal involvement initially, following influenza infection. Severe GI symptoms of haematemesis and abdominal pain persisted, and renal involvement was detected in the initial urinalysis. This renal and GI involvement were earlier than usual HSP patients. The abdominal ultrasonography and laboratory study about coagulation battery including FDP and D-dimer were performed. HSP was suspected as a diagnosis after focal bowel wall thickening was found on abdominal ultrasonography, and when the D-dimer level was elevated. When we found erythematous purpuric

mucosal lesions on EGD, she was diagnosed with HSP. After we administered steroid infusions, her symptoms improved and she was discharged.

There is another HSP case similar to our case. Rocco Urso and his colleagues reported one case of HSP after influenza infection in 2009 in Rome, Italy, when H1N1 influenza infection was pandemic.⁷ Their patient, a 23-year-old Caucasian woman, presented with a two-day history of fever, abdominal pain and skin purpura. She also had GI bleeding symptom, bloody stools as our patient had bloody vomiting. Nasopharyngeal and rectal swabs revealed pandemic 2009 (H1N1) virus by reverse-transcriptase-polymerase-chain-reaction assay. She was diagnosed with HSP following H1N1 virus infection.

Rocco Urso and his colleagues added a steroid therapy to the antiviral drugs. On the other hand, we stopped oseltamivir because of severe vomiting. Their combined treatment contributed to improving a complicated case of vasculitis. The combined treatment may be used to treat a patient suffering from HSP following influenza infection, and in these two cases, the role of the influenza virus in the pathogenesis of haemorrhagic manifestations at GI tract should be considered. Further studies about this relationship must be performed.

In our case, GI symptoms (haematemesis and abdominal pain) and renal involvement (haematuria and proteinuria) initially presented without typical skin lesions. Therefore, even without typical palpable purpura, if there are GI symptoms, and HSP is suspected through laboratory results, such as elevated D-dimer levels, aggressive diagnostic tools should be considered, including abdominal ultrasonography or endoscopy with biopsy.

In our case, we could not identify IgA deposition in the mucosa of the stomach or duodenum because we did not perform a biopsy. This is a limitation in our case. However, HSP following influenza infection is rare, and GI and renal involvement initially presented without typical skin lesion in contrast with usual HSP patients.

Conclusions

Even in the absence of typical purpura, if any gastrointestinal symptoms are observed and HSP is suspected, aggressive diagnostic tools must be considered. Only a few cases of an association between HSP and influenza virus have been reported. However, in these cases, patients had typical symptoms and specific skin lesions from the onset, and they were easily diagnosed. We encountered a rare and interesting case with atypical HSP symptoms after influenza infection. Therefore, we report a rare HSP case involving the GI tract

and kidney, but without typical palpable purpura at first; diagnosis was through abdominal ultrasonography and EGD.

Acknowledgements

None.

Competing of Interest: The authors declare that they have no competing interests.

Financial Disclosure: There is no financial disclosure regarding this study.

References

1. Yang YH, Hung CF, Hsu CR, Wang LC, Chuang YH, Lin YT, et al. A nationwide survey on epidemiological characteristics of childhood Henoch-Schonlein purpura in Taiwan. *Rheumatology (Oxford)*. 2005; 44:618-22.
2. Yang YH, Yu HH, Chiang BL. The diagnosis and classification of Henoch-Schonlein purpura: an updated review. *Autoimmun Rev*. 2014; 13:355-8.
3. Chang WL, Yang YH, Wang LC, Lin YT, Chiang BL. Renal manifestations in Henoch-Schonlein purpura: a 10-year clinical study. *Pediatr Nephrol*. 2005; 20:1269-72.
4. Tizard EJ. Henoch-Schonlein purpura. *Archives of disease in childhood*. 1999; 80:380-3.
5. Kikuchi Y, Yoshizawa N, Oda T, Imakiire T, Suzuki S, Miura S. Streptococcal origin of a case of Henoch-Schoenlein purpura nephritis. *Clin Nephrol*. 2006; 65:124-8.
6. Hope-Simpson RE, Higgins PG. A respiratory virus study in Great Britain: review and evaluation. *Prog Med Virol*. 1969;11:354-407.
7. Urso R, Bevilacqua N, Gentile M, Biagioli D, Lauria FN. Pandemic 2009 H1N1 virus infection associated with purpuric skin lesions: a case report. *J Med Case Rep*. 2011;5:132.
8. Yilmaz D, Kavakli K, Ozkayin N. The elevated markers of hypercoagulability in children with Henoch-Schonlein purpura. *Pediatr Hematol Oncol*. 2005; 22:41-8.
9. Yang YH, Chuang YH, Wang LC, Huang HY, Gershwin ME, Chiang BL. The immunobiology of Henoch-Schonlein purpura. *Autoimmun Rev*. 2008; 7:179-84.
10. Rostoker G. Schonlein-henoch purpura in children and adults: diagnosis, pathophysiology and management. *Bio Drugs*. 2001; 15:99-138.