

Calvarial remodelling surgery: Neurosurgical experience of multidisciplinary craniofacial reconstruction

Abdul Ghaffar,¹ Zahid Hussain,² Shahzad Ahmed Qasmi,³ Shahid Hameed Chaudhry⁴

Abstract

Objective: To evaluate the safety, cosmetic and functional outcome of craniofacial reconstruction surgery for primary craniosynostosis and clefts.

Methods: This quasi-experimental study was conducted at the Combined Military Hospital, Rawalpindi, Pakistan, from June 2011 to December 2014, and comprised paediatric patients undergoing calvarial reconstructive procedures. Fronto-orbital advancement and reconstruction, total calvarial remodelling and box flap reconstruction techniques were used. Parameters recorded were anomaly, procedure, hospital and intensive care unit stay, theatre time, blood transfusion, dural tears, mortality, wound infection, haematoma/seroma, dehiscence, seizures and cosmetic acceptance. Data was analysed using SPSS 17.

Results: Of the 45 patients, 24(53.3%) were boys and 21(46.7%) were girls with an overall mean age of 14.1±21.95 months. Besides, 36(80%) patients were operated for craniosynostosis and 9(20%) for Tessier clefts. Surgical techniques of Fronto-orbital advancement and reconstruction, total calvarial remodelling and box flap were used on 18(40%), 18(40%) and 9(20%) patients, respectively. The mean theatre time was 315.33±74.67 minutes (range: 240-390minutes). The mean blood transfusion was 313.34±135.84ml (range: 200-600ml). Major wound infection was seen in 1(2.2%) patient and minor wound infection occurred in 6(13.3%) cases. Post-operative seizures were seen in 1(2.2%). Improved appearance and stable head growth were seen in 41(91.1%) patients. Only 1(2.2%) patient did not survive the procedure.

Conclusion: Early detection of craniosynostosis, neurological assessment, radiological evaluation, differentiating between primary and secondary craniosynostosis and multidisciplinary treatment of craniofacial reconstruction led to optimal treatment.

Keywords: Craniosynostosis, Craniofacial reconstruction, TCR, FOAR. (JPMA 66: 1611; 2016)

Introduction

Craniosynostosis remains one of the challenging yet potentially surgically correctable paediatric problems in our country. Despite expansion of the health sector and education, there are patients who are brought late for neurosurgical consultation on various accounts like religious/social taboos, poverty and ignorance.

Craniosynostosis is a condition with early suture closure resulting in small Fronto-occipital circumference (FOC) and rigid sutures not allowing brain to grow. This can be classified into primary and secondary, or syndromic and non-syndromic.¹

The bases of this condition are twofold, genetics and resultant structural deformities. Approximately 20% cases are caused by specific single-gene mutations or chromosome abnormalities. Genes most commonly mutated in craniosynostosis are related to fibroblast

growth factor receptors.¹

Craniofacial surgery entered into modern era since 1970's when Tessier introduced dynamic concepts and surgical approaches.² The deformities require correction of overlying soft tissue as well as reconstruction and harnessing the underlying skeleton which can provide a lead point for future normal growth and development of the craniofacial skeleton.³ Hence the outcome is not only cosmetic improvement but also improved brain development. Therefore, there was a need to address this multi-specialty problem with multi-disciplinary team (MDT) approach. A study on long-term results of surgery quoted low complication and re-operation rates in the treatment of isolated metopic craniosynostosis, but also quoted worsening aesthetic outcomes over time.⁴

Traditionally strip craniectomies with more stress on soft tissue work were done in the country.⁵ However, UIHaq et al. published their initial experience with extensive reconstructive surgery which showed encouraging results and few complications.⁶ Recently, trend has shifted towards endoscopic-assisted correction of

.....
¹Consultant and Advisor Neurosurgery Pak Army, ^{2,3}Department of Neurosurgery, ⁴Department of Plastic Surgery, CMH Rawalpindi Cantt.

Correspondence: Zahid Hussain. Email: zahidsurgeon@gmail.com

craniosynostosis, which relies on early diagnosis and surgery because the sutures of young infants are not calcified, thin and pliable, which makes it easier to cut via a minimally invasive approach in infants diagnosed and prepared for surgery earlier than 4 months of age, followed by remoulding helmet.⁷ Helmets are hard to find in local market and the children referred to us were diagnosed late with hard fusion of sutures, guiding us to the MDT decision of open corrective approaches.

The current study was planned to evaluate safety of the procedure, morbidity, complications and cosmetic outcome of the extensive reconstruction in our set-up.

Patients and Methods

This quasi-experimental study was conducted at the Neurosurgery Department of the Combined Military Hospital (CMH), Rawalpindi, Pakistan, from June 2011 to December 2014. Approval was obtained from the institutional ethics committee.

Most of the children were brought by their parents due to deformity of face and/or head to paediatrician or plastic surgeons which led to further consultations.

Case selection was based on individual consultations and thereafter the MDT meeting of neurosurgeon, plastic surgeon, paediatrician, maxillofacial surgeon, ophthalmologist and radiologist. Children presenting with craniosynostosis, smaller FOC and skull vault defects were included. Children with brain atrophy-related microcephaly were excluded.

Purposive sampling technique with intention to treat selected cases was used. Informed consent was obtained from patients' parents. Patients of both genders were included.

Reconstructive techniques used were Fronto-orbital advancement and reconstruction (FOAR), total calvarial remodelling (TCR) and Box flap, depending upon the anomaly and indications.

Pre-operative work-up included detailed history and clinical examination noting visible deformity of head, palpation of sutures and fontanelle tension, scars, inter-orbital distance, nasal deformities, standard head measurements and other associated anomalies. Radiology included antero-posterior and lateral X-rays of head and craniofacial computed tomography (CT) scan with three-dimensional (3-D) reconstruction. Cardiology consultation and echo-cardiography were arranged when indicated.

Pre-admission clinical visit was focused on counselling of

parents with pros and cons, risks and advantages and consent for long-term follow-up. Clinical photography was carried out after written permissions. Blood count, grouping, cross-match, coagulation profile and pre-anaesthetic assessment were completed before admitting patients for surgery.

Patients were operated under general anaesthesia (GA) with essential intra-operative monitoring and surgical prophylaxis as per the hospital's policy. Positioning and draping was considerate to head elevation, hypothermia prevention and protection of pressure points and eyes.

Incisions were planned and exposure was achieved with 'zigzagbicoronal' incision. Morcellationosteotomies were fashioned with high-speed drill to make room for brain expansion. The bones were fixed with low-profile titanium mini-plates and dental wire of 0.35mm. After surgery two sub-galeal gravity drains were used for all cases and removed once the collection was less than 30 ml/day. Post-operatively, patients were nursed in intensive care unit (ICU) for a couple of days and then shifted to ward.

After the operation, patients were followed up for 10 days, one month, and three months for outcomes of mortality, major wound infection, minor wound infection, seizures and late cosmetic deformities. Clinical visits focused on parent's response on improvement in symptoms, cosmesis and measurements to assess head growth velocity. A 3-D CT scan was repeated for all patients who made it to follow-up at the end of one year of surgery.

Long-term follow-up was intended with neurosurgeon, paediatrician, speech and language therapist (SALT), ophthalmologist and genetic counselling in syndromic cases.

Data was recorded on structured proforma sheets. The parameters recorded were age, gender, presentation and diagnosis, type of operation, total theatre time in minutes (mins), blood loss / transfusion in millilitres (ml), durotomy requiring suture repair, duration of hospital and ICU stay in days and complications.

Data was analysed in terms of descriptive statistics such as frequencies, percentages and mean \pm standard deviation (SD). SPSS 17 was used for data analysis. Descriptive variables were analysed using a univariate analysis.

Results

Of the 45 patients, 24(53.3%) were boys and 21(46.7%) were girls with a male-to-female ratio of 1:1.4. The overall mean age was 14.1 ± 21.95 months (range: 4 months-12 years). Besides, 36(80%) patients were operated for craniosynostosis and 9(20%) for Tessier clefts. Of the first,

Table: Demographics and analysis of objective variables.

Variable	N=45	Mean Value or Percentage
Mean Age	N=45	14.1±21.95 months
Gender		
Female	N=21	46.70%
Male	N=24	53.30%
Types of Anomalies		
Craniosynostosis	N=36	80%
Uni-coronal	N=5	11.10%
Bi-coronal	N=12	26.70%
Sagittal	N=16	35.60%
Metopic	N=1	2.20%
Pan	N=2	4.40%
Clefts 13/14	N=9	20%
Types of Operations		
FOAR	N=18	40%
TCR	N=18	40%
BOX Flap	N=9	20%
Mean Hospital stay in days*	N=45	5.467±1.375 days
Mean ICU stay in days	N=45	2.4±0.40 days
Mean Total Theatre time in mins**	N=45	315.33±68.177 mins
Mean Blood Transfusion in mls***	N=45	313.34±135.84 mls
Dural Tears	N=2	4.40%
Major wound infections (Revision surgery)	N=1	2.20%
Minor wound infections	N=6	13.30%
Post-op Seizures	N=1	2.20%
Mortality	N=1	2.20%
Improvement (Functional and Cosmetic)	N=41	91.10%

Values are expressed as mean (standard deviation) or number of patients (percentage); N number of patients

*, **, *** Total Theatre time and blood volume transfused had significant positive correlation to hospital stay in days (p < 0.001)

FOAR: Fronto-Orbital Advancement and Reconstruction

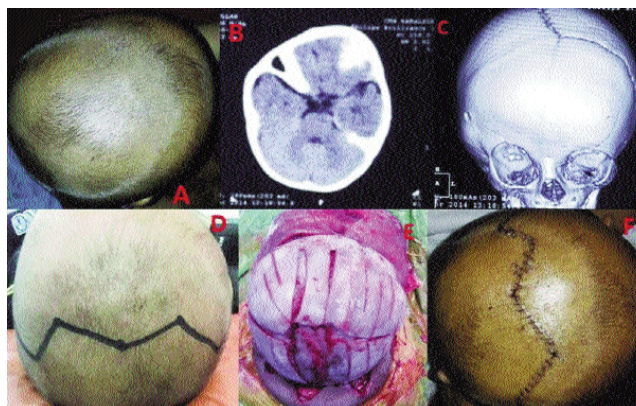
TCR: Total Calvarial Remodelling

ICU: Intensive care unit

SD: Standard deviation.

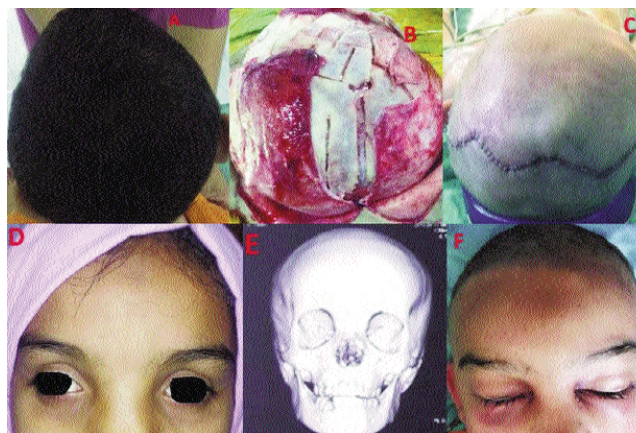5(11.1%) were operated for Unicoronal, 12(26.7%) for Bicoronal, 16(35.6%) for Sagittal, 1(2.2%) for Metopic and 2(4.4%) for Pan-synostosis. There were 2(4.4%) syndromic cases in craniosynostosis group, 1(2.2%) with apert's syndrome who had bi-coronal craniosynostosis, facial and hand anomalies, and 1(2.2%) with crouzon's syndrome who had pan-synostosis and difficulty in attention.

FOAR was used in 18(40%) patients as in (Figure-1), TCR in 18(40%) and Box flaps in 9(20%) shown in (Figure-2). in the mean hospital stay was 5.467±1.375 days (range: 4-7). The mean ICU stay was 2.4±0.40 days. The overall mean theatre time (anaesthesia + operating time) was 315.33 ± 68.177 minutes (range: 240-390). The mean blood transfusion was 313.34±135.84 ml (range: 200-600). We



(A) Pre-op Plagiocephaly. (B) CT scan showing Right uni-coronal craniosynostosis. (C) 3-D CT showing fused suture on Right. (D) Incision marked. (E) The advancement and expansion of calvarium (patient is supine). (F) Follow up visit- compare to pre-op. FOAR: Fronto-Orbital Advancement and Reconstruction CT: Computerised tomography 3-D: Three-dimensional

Figure-1: Illustrating FOAR for Right unicoronal craniosynostosis.



(A) Child with craniosynostosis. (B) TCR- view from right in prone position. (C) Post-operative appearance. (D) Left with hypertelorism. (E) 3-D CT of Cleft patient. (F) Box Flap post-operative appearance of forehead and root of the nose. TCR: Total Calvarial Remodelling CT: Computerised tomography 3-D: Three-dimensional.

Figure-2: Showing TCR and BOX Flap.

analysed total theatre time blood loss as dependent variables against hospital stay duration using Tests of Between-Subjects Effects and the correlation was significant (p<0.001).

Full thickness dural tears of >3mm with cerebrospinal fluid egress was encountered in 2(4.4%) patients and repaired primarily of no consequence. Complications of

major wound infection occurred in 1(2.2%) patient, who required revision surgery, removal of infected bone flap and reconstruction after 8 months with poor cosmetic outcome and scalp hair loss. Minor wound infections were recorded in 6(13.3%) patients, all of them healed well with local wound care and systemic antibiotics. Moreover, 1(2.2%) patient had post-operative seizures without any evidence of contusion or haematoma on CT scan and was managed with anti-epileptics. Besides, 1(2.2%) patient did not survive the procedure with fulminant ventricular tachycardia (VT), probably a hypothermia-related complication. Furthermore, there were 8(17.7%) cases of morbidity. Collectively parents' response and FOC measurements indicated improved appearance and stable head growth in 41(91.1%) cases (Table).

Discussion

Craniosynostosis and calvarial anomalies, if overt at birth, can be picked up easily by trained paediatricians from suture/ fontanelle characteristics, FOC at birth, and head growth velocity on serial measurements, and further referred to appropriate specialists for investigation and treatment.⁸ Indications of surgery are to alleviate the high intracranial pressure, allowing brain growth, optimisation of calvarial growth potential and cosmetic i.e. prevention of progression of craniofacial deformity, and contraindications are microcephaly with brain atrophy. Non-treatment will lead to raised intracranial pressure with resultant blindness, mental deterioration and even death, especially in multi-pleasuresynostosis.

This study described an experience of the multidisciplinary approach to calvarial remodelling in craniosynostosis and other calvarial defects by neurosurgical team in Pakistan. Over a period of three-and-a-half years, 45 patients were scrutinised and deemed fit by MDT for remodelling surgery by FOAR, TCR and Box flaps in 18, 18 and 9 patients, respectively. The exact incidence of craniofacial anomalies is not known in the country, however, for craniosynostosis, it has been found as 2 per 2,360 live births in the northern part of the country.⁸ Single-suture synostosis most commonly affects the sagittal suture, followed by the coronal, metopic and lambdoid sutures.¹

Despite the application of endoscopic synostectomy, the contemporary open surgery at an optimum age of 6 months remains standard for most patients.⁹ However, endoscopic procedure is less invasive and decreases the anaesthesia time, the need for transfusions, and the length of hospital stay in infants under 4 months of age.⁷

Traditionally, the humble procedures performed for these patients were strip craniectomy/synostectomy to

minimise surgery/anaesthesia time and blood loss in these precarious children. Though we have not seen but growing skull fractures can also occur after remodelling surgery due to undetected dural tears.¹⁰ Major blood loss and transfusions during surgery in these infants can potentially tip off a vicious circle of complications, which may lead to death. In this study, the average blood transfusion was approximately 335ml in surgery of 4-6 hours. Seruya M. et al. found over-transfusion was more frequent at lower levels of bleeding, and under-transfusion at higher level scan lead to delay in resuscitation and longer hospitalisation.¹¹ Strategies to minimise blood transfusions and its hazards may include Children's Hospital of Richmond (CHoR) protocol of pre-operative administration of recombinant erythropoietin, intra-operative autologous blood recycling, and acceptance of a lower level of haemoglobin as a trigger for transfusion (< 7 g/dl) and patient blood management systems.^{12,13}

Scans of 3-D CT are widely followed in assessing defects/effects (copper-beaten skull) in these patients and planning surgery.¹⁴ Long-term relapse and revision surgery have led to numerous modifications of techniques, like hypercorrection, unilateral versus bilateral correction, shell technique, split calvarial grafting, posterior cranial vault expansion and, recently, spring-assisted techniques, with improved structural and cosmetic results.¹⁵⁻¹⁷

Genetic mapping may be helpful in syndromic craniosynostosis as about 60 mutations in the fibroblast growth factor receptor (FGFR) 2 and 3 genes have been identified and these patients particularly require multidisciplinary management and treatment involving multiple-organ systems beyond craniosynostosis.^{18,19} Non-syndromic craniosynostosis is multifactorial, and the foetal constraints have been studied but found not causative. Instead, low birth weight and prematurity were associated with craniosynostosis.²⁰

Long-term results of our patients have yet to be seen as we lost 24.4% patients to follow beyond 3 months. Though the evidence is encouraging and re-operation rate is low with newer adjuncts to remodelling surgery, the surgical techniques need to be individualised based on target areas.^{4,9,21} Our study showed that parents' response on development was positive in 91.1% of our patients. However, prolonged surgery/anaesthesia had inverse relation with neurodevelopmental scores, particularly lower among children with non-sagittal synostosis.²²

Wound infections were the main source of morbidity in

our study amounting to 15.5 %, however consequential in only 1(2.2%) patient. This problem was tackled with universal sterile precautions and saline irrigation, with and without topical antibiotics to harvested bone flaps as per evidence.²³ Absorbable plates have been used to avoid hardware exposure through scalp and minimise the wound nuisances.²⁴ We did not have any case of post-op haematoma or contusions but one patient had generalised seizures in post-operative period and managed with anti-epileptics.

The limitations of our study included a lack of comparative treatment in age-matched patients, age mismatch for endoscopic treatment and non-compliant follow-up. A prospective randomised-controlled trial with extended follow-up may help in concluding the optimum treatment.

Conclusion

Reconstructive surgery not only prevented further brain damage due to chronic intracranial hypertension but also addressed the deformity, 3-Dskull growth, and harnessed growth potential at skull base for better structural and functional outcome of facial skeleton with improved speech and swallowing. Therefore, early detection, detailed neurological assessment, radiological evaluation, differentiating between primary and secondary craniosynostosis and multidisciplinary approach led to optimal treatment in these patients.

Disclaimer: None.

Conflict of Interest: None.

Source of Funding: None.

References

- Johnson D, Wilkie AOM. Craniosynostosis. *Eur J Human Genetics* 2011; 19:369-76.
- Kolk CAV, Menezes J. Craniofacial syndromes. In: Mathes SJ, Hentz VR, eds. *Plastic surgery: 2nd ed.* Philadelphia: Saunders Elsevier, 2006; pp 91-112.
- Fan K, Kawamoto HK, McCarthy JG, Bartletts SP, Matthews DC, Wolfe SA, et al. Top five craniofacial techniques for training in plastic surgery residency. *Plast Reconstr Surg.* 2012; 129:477-87.
- Wes AM, Paliga JT, Goldstein JA, Whitaker LA, Bartlett SP, Taylor JA. An evaluation of complications, revisions, and long-term aesthetic outcomes in nonsyndromic metopic craniosynostosis. *Plast Reconstr Surg.* 2014; 133:1453-64.
- Raja RA, Khemani VD, Sheikh S, Khan H. Craniosynostosis: early recognition prevents fatal complications. *J Ayub Med Coll Abbottabad.* 2011; 23:140-3.
- Ul-Haq E, Aslam A, Kazmi A, Tammimy MS, Aman S, Ahmad RS. Fronto-orbital advancement and total calvarial remodelling for craniosynostosis. *JCPSP.* 2014; 24: 118-22.
- Brown L, Proctor MR. Endoscopically assisted correction of sagittal craniosynostosis. *AORN J.* 2011; 93:566-79.
- Gillani S, Kazmi NHS, Najeeb S, Hussain S, Raza A. Frequencies of congenital anomalies among newborns admitted in nursery of ayub teaching hospital Abbottabad, Pakistan. *J Ayub Med Coll Abbottabad.* 2011; 23: 117-21.
- Seruya M, Oh AK, Boyajian MJ, Posnick JC, Myseros JS, Yaun AL, et al. Long-Term Outcomes of Primary Craniofacial Reconstruction for Craniosynostosis: a 12-Year Experience. *Plast Reconstr Surg.* 2011; 127:2397-406.
- Seruya M, Oh AK, Rogers GF, Han KD, Boyajian MJ, Myseros JS, et al. Blood loss estimation during fronto-orbital advancement: implications for blood transfusion practice and hospital length of stay. *J Craniofac Surg.* 2012; 23:1314-7.
- Vega RA, Lyon C, Kierce JF, Tye GW, Ritter AM, Rhodes JL. Minimizing transfusion requirements for children undergoing craniosynostosis repair: the CHoR protocol. *J Neurosurg Pediatr.* 2014; 14:190-5.
- Haas T, Goobie S, Spielmann N, Weiss M, Schmutz M. Improvements in patient blood management for pediatric craniosynostosis surgery using a ROTEM®-assisted strategy - feasibility and costs. *Paediatric Anaesthesia* 2014; 24:774-80.
- Zemann W, Metzler P, Jacobsen C, Kruse AL, Lübbers HT, Könu D, et al. Growing skull fractures after craniosynostosis repair: risk factors and treatment algorithm. *J Craniofac Surg.* 2012; 23:1292-5.
- MW Vannier, C F Hildebolt, J L Marsh, T K Pilgram, W H McAlister, G D Shackelford et al. Craniosynostosis: diagnostic value of three-dimensional CT reconstruction. *Radiology.* 1989; 173 :669-73.
- Nowinski D, Di Rocco F, Renier D, Sainte-Rose C, Leikola J, Arnaud E. Posterior cranial vault expansion in the treatment of craniosynostosis. Comparison of current techniques. *Childs Nerv Syst.* 2012; 28:1537-44.
- Vercler CJ, Sugg KB, Buchman SR. Split cranial bone grafting in children younger than 3 years old: debunking a surgical myth. *Plast Reconstr Surg.* 2014; 33:822-7.
- Di Rocco C, Frassanito P, Tamburrini G. The shell technique: bilateral fronto-orbital reshaping in trigonocephaly. *Childs Nerv Syst.* 2013; 29:2189-94.
- Agochukwu NB, Solomon BD, Muenke M. Impact of genetics on the diagnosis and clinical management of syndromic craniosynostoses. *Childs Nerv Syst.* 2012; 28:1447-63.
- Derderian C, Seaward J. Syndromic Craniosynostosis. *Semin Plast Surg* 2012; 26:64-75.
- Sanchez-Lara PA, Carmichael SL, Graham JM, Lammer EJ, Shaw GM, Ma C, et al. Fetal Constraint as a Potential Risk Factor for Craniosynostosis. *Am J Med Genet A.* 2010; 152: 394-400.
- Wan DC, Kwan MD, Kumar A, Bradley JP, Longaker MT. Craniofacial surgery, from past pioneers to future promise. *J Maxillofac Oral Surg.* 2009; 8:348-56.
- Naumann HL, Haberkern CM, Pietila KE, Birgfeld CB, Starr JR, Kapp-Simon KA, et al. Duration of Exposure to Cranial Vault Surgery: Associations with Neurodevelopment among Children with Single-Suture Craniosynostosis. *Paediatr Anaesth.* 2012; 22:1053-61.
- Hayashi T, Shirane R, Yokosawa M, Kimiwada T, Tominaga T. Efficacy of intraoperative irrigation with saline for preventing shunt infection. *J Neurosurg Pediatrics.* 2010; 6:273-6.
- Salvino MJ. Avoiding pitfalls in craniofacial reconstruction using absorbable plates. *J Craniofac Surg.* 2010; 21:213-4.