

The many guises of primary hyperparathyroidism... An unchanged scenario

Tasnim Ahsan,¹ Uzma Erum,² Khawaja Mohammad Inam Pal,³ Rukhshanda Jabeen,⁴ Saima Ghaus Qureeshi,⁵ Urooj Lal Rehman,⁶ Zeenat Banu⁷

Abstract

Objective: To study the causes, characteristics and outcome of treatment of patients with primary hyperparathyroidism.

Methods: This retrospective cohort analysis was conducted at the Jinnah Postgraduate Medical Centre, Karachi, and comprised data of patients with primary hyperparathyroidism between 2004 and 2014. SPSS 17 was used for data analysis.

Results: Of the 25 patients, 1(4%) was male and 24(96%) were female. The overall mean age was 41.72±15.9 years, with a mean duration of symptoms of 4.1±3.3 years. The mean pre-operative parathyroid hormone level was 879.48±793.51 pg/ml. Skeletal manifestations were reported in 17(68%) patients, whereas 4(16%) patients had renal stone disease. Besides, 2(8.0%) patients presented with severe abdominal pain, 1(4%) had asymptomatic hypercalcaemia and 1(4%) patient presented with headache and was diagnosed as parathyroid adenoma in the context of multiple endocrine neoplasia type 2A. All patients underwent parathyroidectomy. A solitary adenoma was reported in 23(92%) patients, carcinoma in 1(4%) and an adenoma with hyperplasia of other glands in 1(4%) patient.

Conclusion: A high index of suspicion is required for early diagnosis of primary hyperparathyroidism.

Keywords: Primary hyperparathyroidism, Parathyroidectomy, Hypercalcaemia. (JPMA 67: 580; 2017)

Introduction

Primary hyperparathyroidism (PHPT) occurs as a result of unregulated over-production of parathyroid hormone (PTH) secreted from the parathyroid glands, leading to an inappropriate calcium homeostasis. PHPT per se is considered a rare disease with a variable prevalence; but data from the Rochester Epidemiological Project reported the incidence of PHPT as 21.6 cases per 100,000 person-years.¹ Approximately 90% of patients with PHPT have significantly high serum PTH concentrations, while 10-20% may have only minimally elevated PTH levels.² The commonest underlying aetiology is a solitary adenoma, accounting for almost 80-85% of the cases, whereas multi-glandular disease has been reported in 5% of patients with PHPT.³ Hyperplasia of parathyroid gland and carcinoma are less frequently seen, with a reported prevalence of < 1% of parathyroid carcinoma among patients with PHPT.^{4,5}

The clinical features that accrue are largely related to circulating PTH levels and the ensuing degree of hypercalcaemia. Women are affected more often than men, with a peak incidence between 50 and 60 years of

age, and skeletal and renal manifestations being the commonest. However, the trend of symptomatology has changed in countries, with well-developed health care services, due to early diagnosis made possible by routine biochemical screening.⁶ A higher incidence of symptomatic disease is seen in patients with PHPT in countries with poor resources for health care. Surgical treatment is generally a well-tolerated approach to cure, and is the mainstay of long-term disease free survival. The current study was planned to report the diverse clinical presentations, causes and the outcome of treatment of PHPT.

Patients and Methods

This observational, retrospective study was conducted at the Endocrine Unit of Jinnah Postgraduate Medical Centre (JPMC), Karachi, and comprised records of patients with diagnosis of hyperparathyroidism from 2004 to 2014.

PHPT was diagnosed on the basis of high or normal ionised calcium levels with high or inappropriate serum PTH levels. Clinical presentation, laboratory parameters, imaging, histology and surgical outcome were studied.

Data was analysed using SPSS 17. For descriptive statistics like gender, co-morbidities, presenting clinical features, histology and tumour location, frequency and

^{1,2,4-7}Medical Unit-II, Jinnah Postgraduate Medical Centre, Karachi,

³Department of Surgery, Aga Khan University Hospital, Karachi, Pakistan.

Correspondence: Uzma Erum. Email: drkhan8583@gmail.com

percentages were calculated, while means were calculated for age, duration of disease, pre-operative and post-operative biochemical parameters, like serum PTH, calcium (Ca), phosphate (PO₄) and alkaline phosphatase (AlkPO₄).

Results

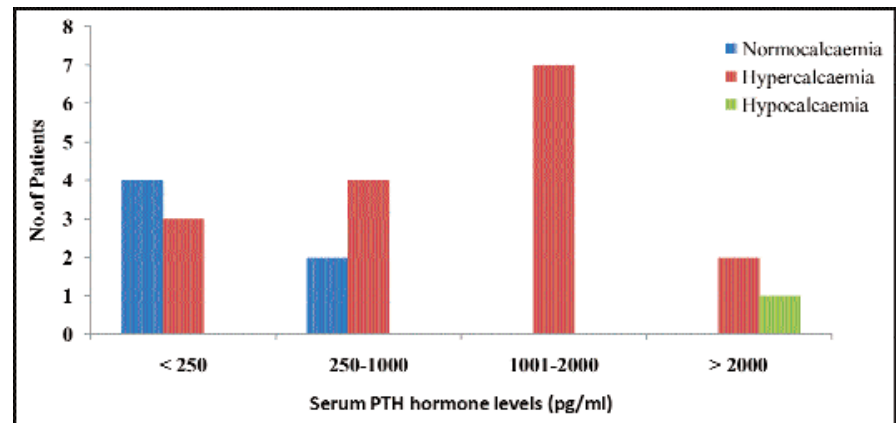
Of the 25 participants, 24(96%) were females and 1(4%) was male. The overall mean age was 41.72±15.9 years. The commonest affected age group lay between 21-40 years with 11(44%) patients compared to 8(32%) patients aged between 41-60 years, 4(16%) patients aged above 60 years and 2(8%) patients aged below 20 years. Mean values for serum Ca, PO₄ and AlkPO₄ were 11.23±1.6, 2.4±0.83 and 673.5±729.6, respectively (Table).

Patients were divided into three groups based on the serum Ca level, i.e. 7 (28%) normocalcaemic patients (serum Ca = 8.5-10.5 mg/dl), 17(68%) hypercalcaemic patients (serum Ca > 10.5 mg/dl), and 1(4.0%) hypocalcaemic patient (serum Ca < 8.5 mg/dl). Comparison of calcium status to the PTH level revealed that patients with normocalcaemia had lower PTH levels than those with hypercalcaemia (Figure-1). However, the 1(4%) patient with hypocalcaemia had markedly elevated PTH level. Moreover, 23(92%) patients had vitamin D deficiency.

Patients had varied clinical manifestations, bone disease

being the primary presentation in 17(68%) patients, whereas 4(16%) had recurrent stone disease; 1(4%) patient presented with chronic headache and 2(8%) patients reported with acute abdomen, of which one had acute pancreatitis and the other had severe abdominal pain due to hypercalcaemia and cholelithiasis (Figure-2).

Patients with bone disease had variable clinical presentations, body aches and fatigue being the commonest manifestation in 11(44%), followed by inability to walk with fractures in 3(12%) patients, who also had a prior history suggestive of proximal myopathy. Jaw mass was seen in 3(12%) patients. Only 1(4%) patient had asymptomatic hypercalcaemia and was detected on routine biochemical screening. The patient with history of chronic headache and



PTH: Parathyroid hormone.

PHPT: Primary hyperparathyroidism

Figure-1: Relation between calcium status and PTH level of patients with PHPT.

Table: Baseline biochemistry and hormone levels.

	Normal Range	Means ± SD	Range (Min-Max)
Serum Ca	8.1-10.4 mg/dl	11.23±1.6	7.3-14.4
Serum PO ₄	2.5-4.8 mg/dl	2.4±0.83	1.03-4.2
Serum AlkPO ₄	65-360 U/L	673.5±729.6	55-2335
Serum intact PTH (Pre-operative)	16-81 pg/ml	879.47±793.5	79.1-2500
Serum Intact PTH (Post operative)	16-81 pg/ml	Median – 518.0 246.45±387.9	11.3-1398.0
Serum Cr	0.5-1.2 mg/dl	1.05±0.64	0.30-3.2
Vitamin D3	Sufficiency >30 ng/ml	16.27±14.3	4.00-59.6

Ca: Calcium

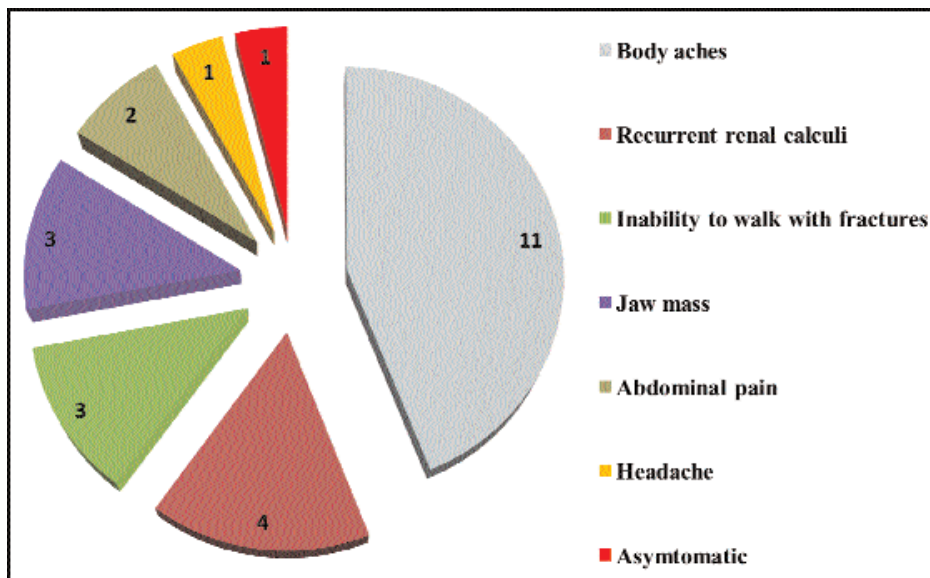
PO₄: Phosphate

AlkPO₄: Alkaline phosphatase

PTH: Parathyroid hormone

Cr: Creatinine

SD: Standard deviation.



PHPT: Primary hyperparathyroidism.

Figure-2: Clinical manifestations of patients with PHPT.

uncontrolled hypertension had parathyroid adenoma in the context of multiple endocrine neoplasia type 2A(MEN-2A), with histologically proven bilateral pheochromocytoma, medullary carcinoma of thyroid and parathyroid adenoma.

Histology of the jaw mass was consistent with brown tumour in 2(8%) patients, and giant cell granuloma of mandible in 1(4%) patient. X-rays were only done for patients with focal bone-related symptoms. Of the patients with jaw mass, an osteoclastic lesion was evident in mandibular rami in 2(66.7%) of them and 1(33.3%) had intra-oral soft tissue swelling. The patients with inability to walk had severe generalised osteopenia with pathological fractures in pubic rami, greater trochanter and neck of femur.

Comparison of serum calcium level with disease manifestations revealed that all patients with stone disease had hypercalcaemia while 10(58.8%) of the hypercalcaemic patients had hypercalcaemia in bone disease group. Hypertension was recorded in 6(24%) patients, 1(4%) patient had concomitant diabetes and 1(4%) had hypothyroidism. Median lag time from symptom onset to diagnosis of PHPT was 3 years, with a mean duration of clinical symptoms of 4.1±3.3 years. Ultrasonography of neck was normal in 12(48%) patients and was not done in 3(12%) patients. It showed hypoechoic lesion near the inferior pole of thyroid in 10(40%) patients. Sestamibi scan was positive for a

functioning parathyroid adenoma in 17(68%) patients. Of the 8(40%) patients who had negative myocardial perfusion (MIBI) scan, 1(12.5%) had ectopic parathyroid located in the mediastinum, which was detected on magnetic resonance imaging (MRI). A total of 21(84%) patients had parathyroid adenoma at usual anatomical site while 4(16%) had an ectopic location.

All patients underwent excision of involved gland where pre-operative localisation was available, while for un-localised cases bilateral neck exploration was performed. The 1(4%) patient with ectopic parathyroid had median sternotomy. The patient with MEN-2A had total thyroidectomy with parathyroidectomy and bilateral adrenalectomy. Histology revealed a single adenoma in 23(92%) patients, carcinoma in 1(4%), and 1(4%) patient had adenoma of one gland with hyperplasia in the remaining parathyroid glands.

Post-operative PTH levels were normalised in 15(60%) patients, within the first 2 weeks after surgery, while mild short-term or recurrent PTH elevation was observed in 6(24%) patients. No post-operative PTH level and bone biochemistry was available for 4(16.0%) patients due to irregular follow-up visits.

Discussion

A striking discrepancy exists with respect to incidence, clinical manifestations and complications of PHPT across the globe. The current study was a small but systematic study to collate the estimates of diverse clinical spectrum of PHPT in our patients, keeping in mind the delay in diagnosis. This may help clinicians in better understanding the variable presentations of PHPT and hence early diagnosis. It may also help to delineate the underlying mechanisms for such varied clinical manifestations. As yet unknown, environmental and nutritional factors may also influence the incidence of disease. Sparse documentation is available regarding the exact prevalence of hyperparathyroidism in Pakistan. Very few studies pertaining to PHPT have been reported from Pakistan.^{7,8}

There are wide variations in the clinical spectrum of PHPT in our geographical region. Here, it involves considerably younger age group, with symptomatic hyperparathyroidism; hence recurrent calculi and overt bone disease are still the predominant forms of the disease. Crippling skeletal manifestations mainly account for the morbidity associated with the disease. Most of our patients had some form of skeletal disease, indicating a substantial delay in diagnosis. Other studies from our region have also reported a higher prevalence of bone disease (30-46%) and stone disease (20-30%) in patients with PHPT.⁸⁻¹⁰ A recent study from India has also reported a higher prevalence of bone disease and proximal myopathy (60%).¹¹ Similarly, a study from Iran reported bone disease in 60-100% patients, in the form of bone pain, fractures or osteitis fibrosa cystica.¹² Our findings are similar to those from other Eastern countries, in terms of the clinical and biochemical features of PHPT. However, this is in contrast to the developed nations where symptomatic disease has become an exception rather than the rule. Our contemporary data has similarities to the western historic presentation of PTH. It is important to note that renal disease is still considerably less compared to the past Western data. This may be due to less significant hypercalcaemia in our cohort. Only one patient was male in our study, reflecting the unexplained predominance of this disease in females, also reported in other studies.⁷⁻¹³

The routine evaluation of serum biochemistry in the developed countries has led to the origin of a new entity, 'asymptomatic normocalcaemic hyperparathyroidism', thus representing a change in the clinical spectrum of hyperparathyroidism.¹⁴⁻¹⁶ A population-based survey conducted in Sweden reported a 0.6% prevalence of normocalcaemic PHPT in postmenopausal women, while a study from Saudi Arabia reported asymptomatic PHPT in 23.9% of their study cohort.^{17,18} However, even in normocalcaemic PHPT, a higher prevalence of urolithiasis has also been reported.¹⁹ Although many of our patients had normocalcaemia, none of them were asymptomatic. Normocalcaemia can be attributed to concomitant vitamin D deficiency, as our population has a high prevalence of vitamin D deficiency/insufficiency. A study from Lahore, Pakistan, has also reported normocalcaemia in 21.88% of patients with hyperparathyroidism.⁸ Studies from other parts of the world have reported 11-13% of the patients with acute severe pancreatitis in the context of PHPT, whereas our cohort only had one patient presenting in this manner.^{20,21}

It is quite difficult to determine the vitamin D level below

which PTH hypersecretion starts. It is even more difficult to decide in normocalcaemic patients with hyperparathyroidism, as to whether the PTH hypersecretion is due to autonomous stimuli or a positive feedback due to long-standing low vitamin D3 levels. In addition, the high circulating plasma PTH levels decrease plasma 25-hydroxy vitamin D levels (25-OHD), due to an increased metabolic clearance of 25-OHD via increased faecal excretion of vitamin D-derived products. The association between hypersecretion of PTH in PHPT patients, with hypovitaminosis D causing normocalcaemic PHPT, has opened new possibilities for regional differences in the clinical manifestations of PHPT, which is linked to the prevalence of vitamin D3 deficiency in the general population of that region. Due to the significant prevalence of vitamin D deficiency/insufficiency in individuals with PHPT, it is desirable to measure vitamin D3 in all these patients and treating those with low levels, prior to making any management decisions regarding hyperparathyroidism. It has been reported that a 25-OHD threshold of ≥ 50 nmol/L (i.e. 20ng/ml) is sufficient for prevention of secondary hyperparathyroidism in persons with normal renal function.²²

Parathyroid glands are known to vary in anatomic location, and typical ectopic sites include intrathyroidal, lateral neck and mediastinum. An ectopic location of parathyroid adenoma is a very rare cause of hyperparathyroidism, reported in 1-2% of all cases. A study from Pakistan reported three cases with ectopic parathyroid location among 70 patients operated for PHPT over a 20-year period.²³ However, 4 cases of PHPT with ectopic adenoma were encountered in this small cohort of patients. The ectopic location of parathyroid adenoma is recognised as an important cause of persistent PTH elevation due to failed neck exploration surgery, especially in cases with equivocal/failure to localise through all pre-operative modalities. An Indian study has reported 7 ectopic parathyroid adenomas out of 51 cases operated for PHPT.²⁴ One patient with jaw mass had a giant cell granuloma, which is rarely seen as a sole manifestation of PHPT. Very few cases have been reported, where a prior diagnosis of peripheral giant cell granuloma has led to the identification of PHPT subsequently.²⁵⁻²⁷ Brown tumours can present as giant cell reparative lesions, therefore if any patient presents with a suspicious intraoral lesion, either soft tissue mass or involvement of jaw bone, it is mandatory to keenly investigate for PHPT by all possible means. A significant proportion of patients develop PHPT as a part of MEN syndrome.²⁸ MEN-related hypercalcaemia and parathyroid hormone

levels are comparatively lower than sporadic PHPT.^{29,30} Though the demographic and biochemical features of our patient with MEN-2A closely resemble those reported in literature, due to the paucity of data on MEN-2A as well as PHPT from our region, it is difficult to portray the clinical pattern of PHPT in context of MEN syndrome.

Various non-invasive imaging tools for localising PHPT are available, however, Technetium (TC-99m) sestamibi is the most authentic and widely used modality. Accurate localisation was achieved in 65.2% of our patients. However, it has been suggested that the uptake of MIBI in hyper-functioning parathyroid is dependent on gland size and the amount of cellular components. Studies have also reported the overall true-positive cases for sestamibiscans at 56% to 87%; the positivity being related in part to the adenoma size and pre-operative ionised calcium level.^{31,32} A negative MIBI scan has been reported in 50% of cystic and 27.7% of solid parathyroid adenomas with an overall Tc MIBI scan efficacy of 67%.³³ It has been postulated that MIBI uptake is reduced in the presence of uraemia, and one of our patients with negative sestamibi scan also had chronic kidney disease, which evolved over the course of uncontrolled hyperparathyroidism. This was the only patient with hypocalcaemia despite markedly elevated PTH levels, as a result of low bone reserve on account of severe complex bone disease.

Although patients with more severe disease, as manifested by severe hypercalcaemia, may have an increased risk of death, the overall survival is not adversely affected among patients with mild degree of PHPT.³⁴ The severe form of disease seen in this study may in part be related to the delay in seeking medical care due to lack of awareness and paucity of adequate health care facilities for low socio-economic group patients in this country.

Conclusion

A high index of suspicion is required for clinching the early diagnosis of primary hyperparathyroidism. Concomitant vitamin D deficiency masks the hypercalcaemia, related to elevated PTH levels, thus leading to a delay in diagnosis. Therefore, hypercalcaemia must not be used alone as a screening tool for PHPT. In addition, long-standing vitamin D deficiency may cause hyperplasia/and or adenoma of parathyroid glands due to PTH dysregulation.

Disclaimer: None.

Conflict of Interest: None.

Source of Funding: None.

References

1. Wermers RA, Khosla S, Atkinson EJ, Achenbach SJ, Oberg AL, Grant CS, et al. Incidence of primary hyperparathyroidism in Rochester, Minnesota, 1993-2001: an update on the changing epidemiology of the disease. *J Bone Miner Res* 2006; 21: 171-7.
2. Nussbaum S. Immunometric assays of parathyrin in the diagnosis of hypercalcemic individuals. *Clin Chem* 1991; 37: 142-3.
3. Molinari AS, Irvin GL, Deriso GT, Bott L. Incidence of multiglandular disease in primary hyperparathyroidism determined by parathyroid hormone secretion. *Surgery* 1996; 120: 934-7.
4. Givi B, Shah JP. Parathyroid Carcinoma. *Clin Oncol* 2010; 22: 498-507.
5. Rawat N, Khetan N, Williams DW, Baxte JN. Parathyroid carcinoma. *Br J Surg* 2005; 92: 1345-53.
6. Bilezikian JP, Silverberg SJ. Clinical practice. Asymptomatic primary hyperparathyroidism. *N Engl J Med* 2004; 350: 1746-51.
7. Biyabani SR, Talati J. Bone and renal stone disease in patients operated for primary hyperparathyroidism in Pakistan: Is the pattern of disease different from west? *J Pak Med Assoc* 1999; 49: 194-8.
8. Afzal A, Gauhar TM, Butt WT, Khawaja AA, Azim KM. Management of hyperparathyroidism: A five year surgical experience. *J Pak Med Assoc* 2011; 61: 1194-8.
9. Bhansali A, Masoodi SR, Reddy KS, Behera A, das Radotra B, Mittal BR, et al. Primary hyperparathyroidism in north India: a description of 52 cases. *Ann Saudi Med* 2005; 25: 29-35.
10. Gopal A, Acharya SV, Bandgar T, Menon PS, Dalvi AN, Shah NS. Clinical profile of primary hyperparathyroidism from western India: a single centre experience. *J Postgrad Med* 2010; 56: 79-84.
11. Jha S, Jayaraman M, Jha A, Jha R, Modi KD, Kelwadee JV. Primary Hyperparathyroidism: A changing scenario in India. *Indian J Endocrinol Metab* 2016; 20: 80-3.
12. Bahrami A. Primary hyperparathyroidism in Iran: a review. *Int J Endocrinol Metab* 2008; 1: 50-7.
13. Mazeh H, Sipple RS, Chen S. The role of gender in primary hyperparathyroidism: same disease, different presentation. *Ann Surg Oncol* 2012; 19: 2958-62.
14. Marques TF, Vasconcelos R, Diniz E, Rêgo D, Griz L, Bandeira F. Normocalcemic primary hyperparathyroidism in clinical practice: an indolent condition or a silent threat? *Arq Bras Endocrinol Metabol* 2011; 55: 314-7.
15. Lowe H, McMahon DJ, Rubin MR, Bilezikian JP, Silverberg SJ. Normocalcemic primary hyperparathyroidism: further characterization of a new clinical phenotype. *J Clin Endocrinol Metab* 2007; 92: 3001-5.
16. Bilezikian JP, Silverberg SJ. Normocalcemic primary hyperparathyroidism. *Arq Bras Endocrinol Metabol* 2010; 54: 106-9.
17. Lundgren E, Rastad J, Thurffjell E, Åkerström G, Ljunghall S. Population-based screening for primary hyperparathyroidism with serum calcium and parathyroid hormone values in menopausal women. *Surgery* 1997; 121: 287-94.
18. Malabu UH, Founda MA. Primary hyperparathyroidism in Saudi Arabia: A review of 46 cases. *Med J Malaysia* 2007; 65: 394-7.
19. Amaral LM, Queiroz DC, Marques TF, Mendes M, Bandeira F. Normocalcemic versus Hypercalcemic Primary Hyperparathyroidism: More Stone than Bone? *J Osteoporosis*; 2012.
20. Jacob JJ, John M, Thomas N, Chacko A, Cherian R, Selvan B, et al. Does hyperparathyroidism cause pancreatitis? A South Indian experience and a review of published work. *ANZ J Surg* 2006; 76: 740-4.
21. Carnaille B, Oudar C, Pattou F, Combemale F, Rocha J, Proye C. Pancreatitis and primary hyperparathyroidism: forty cases. *Aust N*

- Z J Surg 1998; 68: 117-9.
22. Saliba W, Barnett O, Rennert HS, Lavi I, Rennert G. The relationship between serum 25(OH)D and parathyroid hormone levels. *Am J Med* 2011; 124: 1165-70.
 23. Abbas F, Biyabani SR, Memon A, Talati J. Mediastinal parathyroid adenoma causing Primary hyperparathyroidism. *J Pak Med Assoc* 2007; 57: 93-5.
 24. Muthukrishnan J, Jha S, Modi KD, Jha R, Kumar J, Verma A, et al. Symptomatic primary hyperparathyroidism: a retrospective analysis of fifty one cases from a single centre. *J Assoc Physicians India* 2008; 56: 503-7.
 25. Smith BR, Fowler CB, Svane TJ. Primary hyperparathyroidism presenting as a "peripheral" giant cell granulomas. *J Oral Maxillofac Surg* 1988; 46: 65-9.
 26. Aswath N, Chidambaranathan P. Primary hyperparathyroidism as a central giant cell granuloma of the jaws: pre and post operative treatment pattern of clinical and radiographic presentations. *IJCRI* 2012; 3: 51-6.
 27. Gataa IS, Zardawi FM. Primary hyperparathyroidism presented as central giant cell granuloma of jaw bones. A report of three cases. *IOSR J Dent Med Sci* 2015; 14: 75-9.
 28. Moline J, Eng C. Multiple endocrine neoplasia: an overview. *Genet Med* 2011; 13: 755-64.
 29. Twigt BA, Scholten A, Valk DG, Rinkes-Borel IHM, Vriens MR. Difference between sporadic and MEN related primary hyperparathyroidism; clinical expression, preoperative work-up, operative strategy and follow-up. *Orphanet J Rare Dis* 2013; 8: 50.
 30. Raue F, Kraimps JL, Dralle H, Cougard P, Proye C, Frilling A, et al. Primary hyperparathyroidism in multiple endocrine neoplasia type 2A. *J Intern Med* 1995; 238: 369-73.
 31. Swanson TW, Chan SK, Jones SJ, Bugis S, Irvine R, Belzberg A, et al. Determinants of Tc-99m sestamibi SPECT scan sensitivity in primary hyperparathyroidism. *Am J Surg* 2010; 199: 614-20.
 32. Moka D, Voth E, Dietlein M, Larena-Avellaneda A, Schicha H. Technetium 99m-MIBI-SPECT: A highly sensitive diagnostic tool for localization of parathyroid adenomas. *Surgery* 2000; 128: 29-35.
 33. Ghasemi-Rad M, Lesha e, Abkhiz S, Mohammadi A. Primary Hyperparathyroidism: Comparing between solid and cystic adenomas and the efficacy of ultrasound and single-photon emission computed tomography in their diagnosis. *Endocr Prac* 2015; 21: 1277-81.
 34. Wermers RA, Khosla S, Atkinson EJ, Grant CS, Hodgson SF, O'Fallon WM, et al. Survival after the diagnosis of hyperparathyroidism: a population-based study. *Am J Med* 1998; 104: 115-22.
-