

Hepatic arterial system anomalies encountered during pancreaticoduodenectomy — our experience

Raza Sayyed,¹ Mariam Baig,² Asghar Khan,³ Imran Khalid Niazi,⁴ Aamir Ali Syed,⁵ Faisal Hanif⁶

Abstracts

We present our experience of incidence and management of aberrant hepatic arterial anatomy encountered during pancreaticoduodenectomy (PD).

Patients undergoing PD between December 2014 and November 2016 at the Shaukat Khanum Memorial Cancer Hospital, Lahore were included in this short report. Preoperative imaging and operative findings of these patients were reviewed to evaluate the hepatic arterial anatomy and classified according to Hiatt classification.

Sixty-four PD were performed with aberrant arterial anatomy identified in 24 (37.5%) of the cases. Most common anomaly was replaced right hepatic artery (rRHA) arising from the superior mesenteric artery seen in seven (11%) of the patients. Aberrant vessels were recognised and preserved in 23 cases. In one patient, the rRHA was coursing through the pancreatic parenchyma needing resection and reconstruction with uneventful postoperative recovery.

Hepatic arterial anomalies are common and it is possible to preserve these vessels with careful surgical dissection using artery first technique.

Keywords: Hepatic arterial system, Aberrant anatomy, Pancreaticoduodenectomy.

<https://doi.org/10.5455/JPMA.9783>

Introduction

Hepatic arterial distribution is frequently associated with variations from the prevailing pattern.¹ Variant hepatic arterial anatomy can be encountered in almost a quarter of patients.² The aberrant vessels are potentially at risk of being damaged during pancreaticoduodenectomy (PD), adding to the morbidity of this complex procedure that represents

.....
¹Patel Hospital, Karachi, ²Department of Surgical Oncology, ³Department of Radiology, Shaukat Khanum Memorial Cancer Hospital and Research Center, Lahore, ⁴⁻⁶Shaukat Khanum Memorial Cancer Hospital and Research Center, Lahore, Pakistan.

Correspondence: Faisal Hanif. Email: faisal.hanif@gmail.com

the only chance of a cure for resectable pancreatic or periampullary cancers.^{3,4} These anomalies are best identified during preoperative imaging in order to avoid inadvertent injury during dissection.⁵ Damage to the aberrant vasculature may result in haemorrhage or inadequate perfusion to the liver or bile duct with subsequent anastomotic failure.⁶

Aberrant Right Hepatic Artery is the most common anomaly found in the hepatic vasculature,^{2,7} with the replaced right hepatic artery arising from the Superior Mesenteric Artery (SMA) in almost 10% of the cases.² This aberrant vessel may course from posterior to the pancreatic head or portal vein and thus may lie in the area of dissection for PD. Injury to the vessel may result in haemorrhage, ischaemia to the liver or bile duct, or an inadvertent damage to the adventitia of the vessel predisposing the patient to subsequent haemorrhagic complications.⁵ The aberrant vessel can be preserved in most circumstances by meticulous dissection; however it may require ligation in up to 20% of the cases.⁸

In order to evaluate the incidence of variant hepatic arterial anatomy in our population, we conducted this study in patients undergoing PD in the Hepato Pancreatico Biliary service provided in our institution.

Methods and Results

Patients undergoing PD at Shaukat Khanum Memorial Cancer Hospital and Research Centre Lahore, Pakistan between December 2014 and November 2016 were included in the study retrospectively. Data was collected from electronic medical records in December, 2016. Arterial anomalies were identified on preoperative cross-sectional imaging which included biphasic Computerised Tomography (CT) Scan with pancreatic protocol in majority of the patients. Operative details were recorded regarding intraoperative identification and management of the aberrant vascular anatomy, and these findings were compared with preoperative imaging. Arterial anomalies were classified according the Hiatt et al.²

Artery first dissection technique was employed in all cases

Table-1: Hepatic artery aberrations according to Hiatt classification.

	Vascular Anatomy	Hiatt Classification	Frequency	Percentage
1.	Normal	Type 1	40	62.5%
2.	Aberrant LHA from LGA	Type 2	6	9.35%
3.	Aberrant RHA from SMA	Type 3	7	10.93%
4.	Aberrant RHA + Aberrant LHA	Type 4	2	3.12%
5.	CHA from SMA	Type 5	3	4.68%
6.	CHA from Aorta	Type 6	1	1.5%
7.	rRHA from Celiac trunk	Not described	2	3.12%
8.	rRHA from CHA	Not described	2	3.12%
9.	rRHA from Aorta	Not described	1	1.5%

Table-2: Comparative description of identification of Hepatic Arterial Anomalies in literature.

Study	Hiatt ² 1994 n = 1000	Current Study n = 64	Rammohan ⁸ 2014 n = 225	Eshuis ⁴ 2010 n = 758	Perwaiz ⁹ 2010 n = 200	Egorov ¹⁰ 2010 n = 58	Stauffer ⁶ 2009 n = 191
Vascular Anatomy							
Type 1	757 (75.7%)	62.5%		--	147 (73.5%)	36 (62.06%)	
Type 2	97 (9.7%)	9.35%		--	8 (4%)	3 (5.17%)	
Type 3	106 (10.6%)	10.93%	41 (18.2%)	127 (17%)	35 (17.5%)	10 (17.2%)	28 (14.6%)
Type 4	23 (2.3%)	3.12%		9 (1%)		6 (10.3%)	
Type 5	15 (1.5%)	4.68%	1 (0.44%)	7 (1%)	1 (0.5%)	3 (5.17%)	1 (0.5%)
Type 6	2 (0.2%)	1.5%					1 (0.5%)
Other variants		5 (10%)	1 (0.44%)		8 (4%)	1 (1.7%)	1 (0.5%)

of Aberrant Right Hepatic Artery or Aberrant Common Hepatic Artery, and was performed by Duodenal Kocherization and mobilisation of pancreatic head to identify the SMA and the aberrant vessel at its origin in the start of dissection. The identified aberrant vessel was slung in a vascular loop to ensure its preservation during the dissection. All dissection was kept away from the aberrant vessels.

In cases where the aberrant vessel was not coursing through the area of proposed dissection (Hiatt type 1, 2 or type 6 arterial pattern), standard dissection technique was used since the vessel was not at a significant risk of damage.

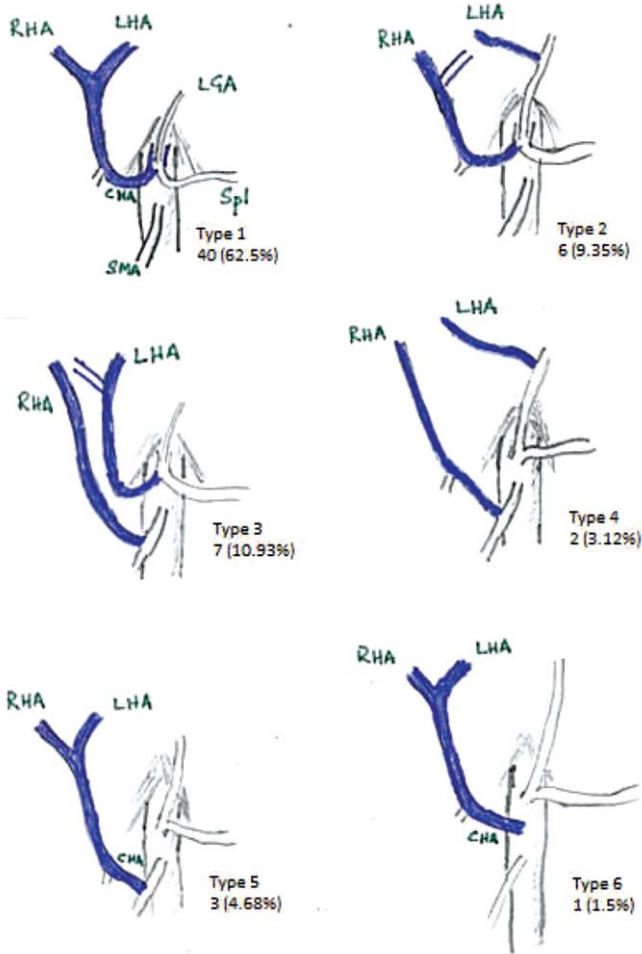
During the study period, 64 patients underwent PD. The indications for surgery were Periampullary or Pancreatic Adenocarcinoma in majority of the cases, while one patient each had Pancreatic Neuroendocrine Tumour, Duodenal Adenocarcinoma, Gastrointestinal Stromal Tumour, Solid Pseudopapillary Tumour of Pancreas and Solid Serous Adenoma of Pancreas.

Normal vascular anatomy was observed in 40 (62.5%) patients indicating the origin of Common Hepatic Artery (CHA) from coeliac axis, which would form Gastroduodenal Artery (GDA) and Proper Hepatic

Artery (HA) that divides into Right (RHA) and Left Hepatic Artery (LHA). We identified aberrant hepatic arterial anatomy in 24 (37.5%) patients, and all these findings were picked up on preoperative CT imaging. No discrepancies between preoperative imaging and operative findings were identified. Figure-1 explains the Hiatt Classification according to which the hepatic vascular anatomy has been categorised in our study.

The most common aberration was a Replaced Right Hepatic Artery (rRHA) arising from the SMA, seen in seven (10.93%) cases, followed by Aberrant (replaced or accessory) Left Hepatic Artery arising from the Left Gastric Artery (LGA) in six patients (9.35%). The CHA arising from the SMA was seen in three (4%) cases. Details of aberrant vascular anatomy are described in Table-1. Five patients (10%) had a replaced right hepatic arterial variant that has not been described in Hiatt Classification².

Artery first dissection was performed in situations where the aberrant vessels were coursing through the area of proposed dissection. This included Aberrant Right Hepatic as well as the Common Hepatic Artery where the aberrant vessel arose from SMA, CHA or aorta and traversed close to the pancreas, placing it at risk of injury during dissection. These aberrant vessels were



CHA: Common Hepatic Artery; Spl: Splenic artery; LGA: Left Gastric Artery; RHA: Right Hepatic Artery; LHA: Left Hepatic Artery; SMA: Superior Mesenteric Artery.

Figure-1: Hiatt Classification of Hepatic Arterial Anatomy with incidence of each variant in current study.

preserved in all but one case (Figure-2) where the rRHA was coursing through pancreatic parenchyma and had to be sacrificed for oncological reasons. This vessel was reconstructed by end-to-end anastomosis. Postoperative scans of this patient showed patency of the reconstructed vessel.

Discussion and Conclusion

We present our institutional experience in the management of aberrant hepatic arterial anatomy encountered during PD. To our knowledge, this is the first description from Pakistan of variant hepatic vascular anatomy encountered during surgery and represents data from our population. Aberrant hepatic arteries were encountered in 37.5% of the cases undergoing PD. This proportion is significantly higher compared to 24.3% in Hiatt's landmark paper on

hepatic arterial anatomy.²

More recent literature on the pattern of aberrant hepatic vasculature also shows an incidence of aberrant hepatic vasculature in 16-19%.^{4,6,8-10} In addition, we report three variations in arterial origin that were not described in Hiatt's study of 1,000 patients undergoing donor hepatic resections.

Table-2 provides a comparison of the incidence of Hepatic Arterial System anomalies in various studies in literature. The incidence of type-3 vascular anomaly is comparable among all studies however our study reports only 62.5% of the patients to have normal hepatic arterial anatomy. In addition, the proportion of undescribed variants in Hiatt's Classification is significantly higher compared to rest of the studies.

The current study represents a very high incidence of hepatic arterial anomalies in our population compared to recent literature. One possible explanation may be that the small sample size of 64 patients and therefore the true proportion of an anomaly in the population may be misinterpreted. However, this still calls for a more stringent and conscious effort on part of the operating team preoperatively identify any variations in hepatic arterial anatomy. This can easily be done with a high quality cross sectional imaging that is performed routinely for staging of the primary disease. Failure to identify such anomalies may result in iatrogenic injury resulting in morbidity following this complex procedure, which can be avoidable with the careful study of the preoperative imaging.

Once identified, every effort should be made to preserve these anomalous vessels during dissection to avoid operative morbidity.

Our experience suggests the presence of hepatic arterial anomalies in more than a third of cases undergoing PD. This suggests the need for a more conscious effort to identify such variations in preoperative imaging. Majority of the aberrant vessels can be preserved by meticulous dissection and in our experience artery first technique is a suitable option to achieve this goal.

Disclaimer: None to be declared.

Conflict of Interest: None to be declared.

Funding Sources: None to be declared.

References

1. Strasberg SM, Phillips C. Use and dissemination of the Brisbane 2000 nomenclature of liver anatomy and resections. *Ann Surg.*

- 2013;257:377-82.
 2. Hiatt JR, Gabbay J, Busuttil RW. Surgical anatomy of the hepatic arteries in 1000 cases. *Ann Surg.* 1994; 220: 50-2.
 3. Ducreux M, Cuhna ASa, Caramella C, Hollebecque A, Burin P, Goéré D, et al. Cancer of the pancreas: ESMO Clinical Practice Guidelines for diagnosis, treatment and follow-up. *Ann Oncol.* 2015;26 Suppl 5:56-68.
 4. Eshuis WJ, Olde Loohuis KM, Busch ORC, van Gulik TM, Gouma DJ. Influence of aberrant right hepatic artery on perioperative course and longterm survival after pancreatoduodenectomy. *HPB (Oxford).* 2011;13:161-7.
 5. Christians KK, Tsai S, Tolat PP, Evans DB. Critical Steps for Pancreaticoduodenectomy in the Setting of Pancreatic Adenocarcinoma. *J Surg Oncol.* 2013;107:33-8.
 6. Stauffer JA, Bridges MD, Turan N, Nguyen JH, Martin JK. Aberrant right hepatic arterial anatomy and pancreaticoduodenectomy: recognition, prevalence and Management. *HPB (Oxford).* 2009;11:161-5.
 7. Allendorf JD, Bellemare S. Reconstruction of the Replaced Right Hepatic Artery at the Time of Pancreaticoduodenectomy. *J Gastrointest Surg.* 2009;13:555-7.
 8. Rammohan A, Palaniappan R, Pitchaimuthu A, Rajendran K, Perumal SK, Balaraman K, et al. Implications of the presence of an aberrant right hepatic artery in patients undergoing pancreaticoduodenectomy. *World J Gastrointest Surg.* 2014; 6: 9-13.
 9. Perwaiz A, Singh A, Singh T, Chaudhary A. Incidence and Management of Arterial Anomalies in Patients Undergoing Pancreaticoduodenectomy *JOP.* 2010;11:25-30.
 10. Egorov VI, Yashina NI, Fedorov AV, Karmazanovsky GG, Vishnevsky VA, Shevchenko TV. Celiaco-Mesenterial Arterial Aberrations in Patients Undergoing Extended Pancreatic Resections: Correlation of CT Angiography with Findings at Surgery. *JOP.* 2010;11:348-57.
-