

## Conventional and contemporary approaches of splinting traumatized teeth: A review article

Shizrah Jamal, Momina Anis Motiwala, Robia Ghafoor

### Abstract

Trauma moves a tooth from its original position which needs to be repositioned for optimum healing and better outcomes. To stabilize the traumatically displaced teeth, splinting is specified as the gold standard. In this article we have discussed about various old and modern techniques based on the type of material to splint teeth with dentoalveolar trauma. As per recommendation of IADT, providing flexible splint is beneficial for good healing. A biologically favourable splint should not just be user friendly but also should be convenient in terms of removal. Every technique has its merits and demerits. Iatrogenic trauma to the teeth due to forceful removal of material should be avoided as it may result in post operative sensitivity but sometimes it is inevitable. Metallic or wire based splints either secured with ligature wire or resin based material may show directly or through the cemented material and compromise aesthetics.

This worsens the physiological impact which the patient is already facing after trauma. Recent advancement in splinting material with fiber reinforced material has brought a dramatic change in terms of strength and aesthetics, specifically after traumatic dental injuries. There are various other techniques discussed here which can be used for splinting teeth when the dentist has limited time in emergency or limited resources. The type and timing of the splinting span should be in accordance with the type of injury and as per IADT recommendation to follow standard of care.

**Keywords:** Dentoalveolar trauma, IADT, Fiber reinforced material.

### Introduction

Traumatic dental injuries have a severe functional and psychological impact on a patient. Trauma displaces a tooth from its original position which needs to be repositioned for optimal healing and good outcomes. In order to relocate and stabilize the traumatically displaced teeth, splinting is specified as the standard of care.<sup>1</sup> Splint

.....  
 Department of Surgery, Aga Khan University Hospital, Karachi, Pakistan.

**Correspondence:** Robia Ghafoor. Email: robia.ghafoor@aku.edu

is defined as: "An assembly to protect, stabilize and immobilize loosened, fractured, replanted and traumatized teeth."<sup>2</sup> It allows periodontal healing and regeneration of the attachment apparatus.

Hamnond *et al.*, introduced an arch bar splint concept, which consists of a metal bar placed on to the teeth and ligated. From then onwards, various methods were used for tooth immobilization, depending on variable principles of rigid or flexible splinting for varying duration.<sup>3</sup>

An ideal splint should be non-rigid, passive and allow for maintenance of oral hygiene. The original recommendations by Andreason<sup>4</sup> regarding the ideal requirements of a splint are mentioned in Table-1. Various studies<sup>5-7</sup> suggested that using flexible splint allows normal functional movements of teeth yielding fewer complications. Also, slight movement allows pulp to heal. Therefore, the International Association of Dental Traumatology (IADT) recommends flexible splints

**Table-1:** Requirements of an ideal splint.

1-	Easy to place without traumatizing the tooth
2-	Able to stabilize and immobilize the tooth in its original position
3-	Easily applied inside the mouth without laboratory step
4-	Less time consuming
5-	Provide adequate immobilization for the desired time
6-	Not impinging on the gingival tissues or increase the caries risk
7-	No occlusal interferences
8-	Allows access for endodontic treatment or pulp sensibility testing
9-	Comfortable to the patient
10-	Aesthetic
11-	Allow adequate oral hygiene maintenance

**Table-2:** Current recommendations by IADT for splinting (Flexible).

Time of Injury	Type of Injury
Subluxation	2 weeks
Extrusive luxation	2 weeks
Lateral luxation	4 weeks
Intrusive luxation	4 weeks
Root fracture (cervical 1/3)	4 months
Root fracture (Apical and mid third)	4 weeks
Avulsion	2 weeks
Avulsion. Dry time > 60 minutes	4 weeks
Alveolar fracture	4 weeks

instead of rigid ones and that too for limited duration.<sup>8</sup>

The ideal recommended splinting times do not take in to account the stage of root development, storage medium or time of re-implantation.<sup>9</sup> The ideal splinting time in correspondence to the type of injury is stated in Table-2.

The aim of this review is to report conventional and contemporary methods and recommendations for splinting. In addition, we have summarized the types of splints according to newer advancements, materials and duration necessary in various traumatic injuries.

**Biologic Process:** Functional forces have better outcomes on healing.<sup>10</sup> The amount of ankylosis was considerably higher in rigidly splinted teeth in comparison to those with no intervention.<sup>5</sup> Literature reports that functional stimulus helps to avoid considerable and rapid accumulation of dead zones in the periodontal ligament with blood vessels and fibroblast.<sup>6</sup> Rigid and extended fixation phase are reported to upsurge the incidence and extent dentoalveolar ankylosis.<sup>11</sup> It was evident in teeth that were splinted for one month than in teeth splinted for a week. A study reported beneficial effect when a functional splint was compared to rigid splinting.<sup>12</sup> The literature in the favour of functional

splints is based on hypothesis from animal studies where teeth were rigidly splinted.<sup>5,6,11</sup> Berude *et al.*, proved that opting the regime of either a rigid or functional splint did not alter the healing response of periodontal ligaments of replanted avulsed teeth in monkeys.<sup>13</sup> No significant difference was found in the healing pattern of periodontal ligaments. In a study reported by Andreasen *et al.*, rigid vs functional splinting was not positively associated with the advent of resorption in replanted human teeth.<sup>6</sup> However he supported the trend for shorter fixation periods.<sup>5</sup>

**Decision making for splints:** The most important question regarding splints is that: Is it even beneficial? A number of studies report that splinting has no additional benefits.<sup>14-16</sup> In root fractures, studies suggest that there is no difference whether splinting is done or not. But it is only true when there is no aesthetic concern due to change in colour of the coronal fragment.<sup>7,17</sup> But according to newer recommendations, functional splinting in such cases for few weeks is the best practice.<sup>7,18</sup> The need of splinting and its benefits depend upon the type and severity of injury. Decision regarding type and duration of splint should be made according to the respective type of injury. Splint given in an emergency unscheduled patient would

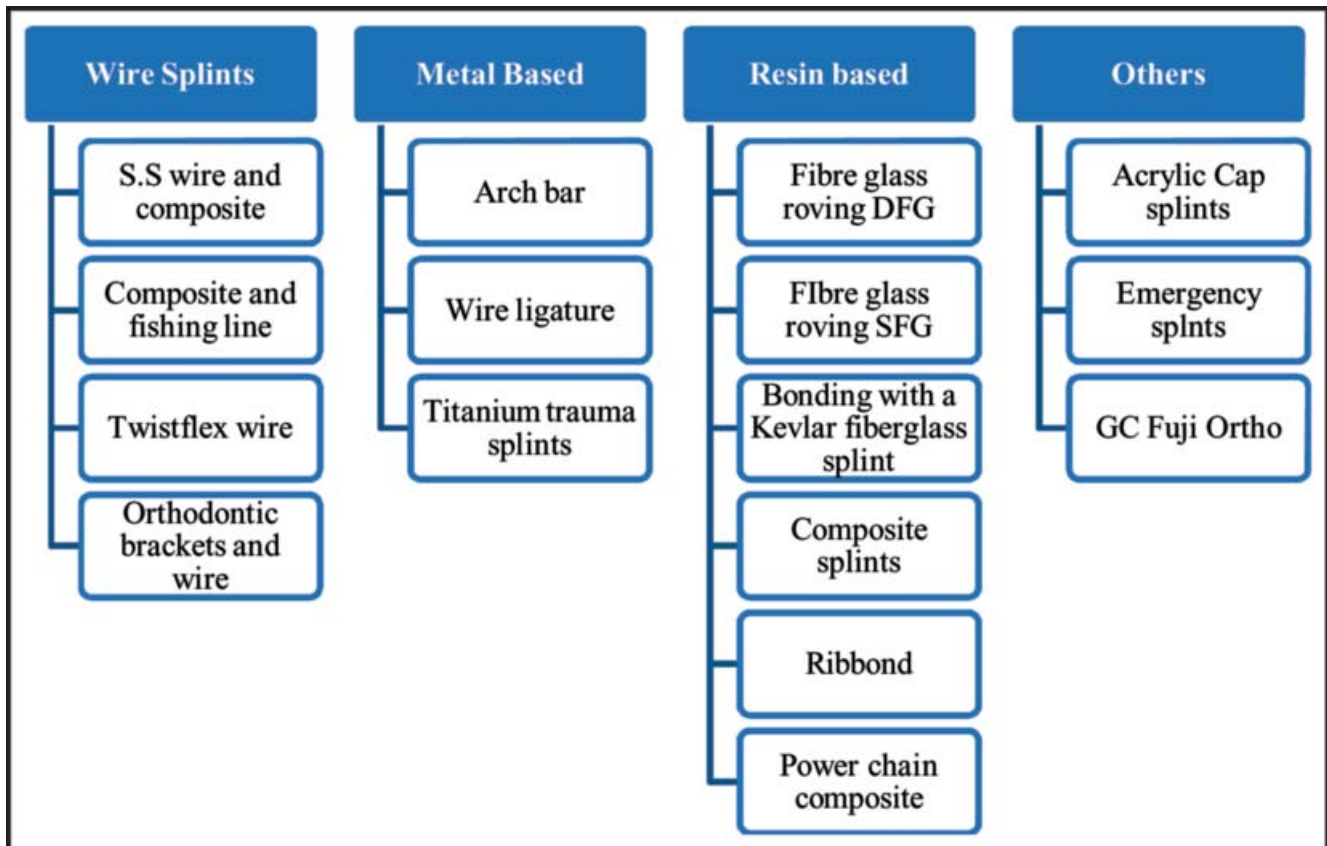


Table-3: Classification of splints.

be different as opposed to when given as a part of planned management of traumatized teeth.

**Types of splints:** Splints can be divided on the basis of materials, flexibility and newer advancements. Types of various splints are summarized in Table-3.

**Rigid vs flexible splinting:** Splinting is of two types. If it involves one tooth on both sides of the displaced tooth, it is a flexible splint. Whereas the one involving two teeth on both sides are rigid splints. Historically, rigid splinting with immobilization for a few months was the treatment of choice.<sup>19</sup> However, it demonstrated increased incidence of pulpal necrosis,<sup>20</sup> ankylosis and pulp canal obliteration specially when given for more than 2 weeks.<sup>2</sup> Ideally, flexible splints should be used for immobilization of traumatized teeth, to allow normal physiologic tooth movements.<sup>21</sup> It is an important factor associated with the healing of periodontal ligament. According to Andersson *et al.*, normal masticatory forces on the splinted teeth prevents formation of resorptive areas on the root surface.<sup>6</sup>

As discussed previously, splints are broadly classified as either rigid or flexible. Furthermore, flexible splinting is the standard protocol. Thus, the classification in our review is of flexible splints based on the types of materials which includes both the conventional and contemporary methods.

## Wire Splints

**S.S wire composite splints:** These are the conventional and most commonly used splints in clinical practice (Figure-1). These are classified as flexible splints if the diameter of stainless steel wire is less than 0.3- 0.4 mm.<sup>22</sup> The wire should be pre contoured to the surfaces of teeth, flexible as well as passive.<sup>23</sup> The tooth is etched, adhesive placed, and the wire positioned on it with the help of small increments of composite. Composite is finished using round or flame shaped diamond or carbide burs, such that it does not hinder in the occlusion. They are easy to place, economical, maintainable and require minimum time.<sup>24</sup> Apa and Gautam *et al.*, in their study concluded that with these splints 100% patients reported no issues

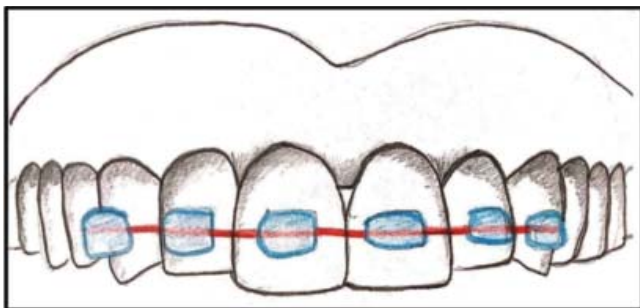


Figure-1: Normal wire and composite splint.

in maintenance of oral hygiene.<sup>24</sup>

**Composite and fishing line:** These are similar to the splints mentioned before, besides the fact that the wire is replaced with fishing line to give an aesthetic result. A Hospital in Sydney used nylon wire and attached it with colourful composites to ease the removal of the splint afterwards without damaging the enamel.<sup>23</sup> In a study based on human cadaver models, monofilament nylon wire splints were compared with six different wire composite splints and suggested that nylon and SS or NiTi wires up to a diameter of 0.016 inch are better suited for flexible splinting of traumatized teeth as opposed to direct composite splints.<sup>25</sup>

**Twistflex wire:** Twistflex are the commonly used wires in orthodontics which are flexible and constructed as a spring. They are also considered aesthetic but difficult to manipulate.<sup>26</sup> They can be used in a similar fashion as the splints mentioned before with composites.

**Orthodontic brackets and wire:** This splint is widely used in Australia which uses orthodontic brackets, bonded to the tooth surface with adhesive and a light flexible 0.14NiTi wire used with it (Figure-2).

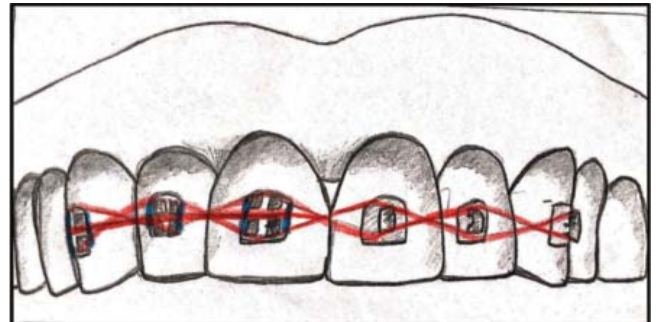


Figure-2: Orthodontic brackets and wire splints.

## Metal Based Splints

**Arch bar splints and Wire ligature splints:** Arch bar splints were primarily used for maxillofacial fractures followed by using these in dental trauma.<sup>3</sup> A metal bar is adapted to dental arch and secured with ligature wires (Figure-3). Whereas, wire ligature splints are utilized by oral surgeons only in the clinical settings where other splinting techniques may not be obtainable.<sup>3</sup> Shortcomings of these techniques is its rigidity and it may loosen with time. Loose and pointed edges irritates soft tissue and the integrity of the cemento-enamel junction.<sup>22</sup> Sekar *et al.*, stated in his study that arch bar is more traumatic, plaque retentive

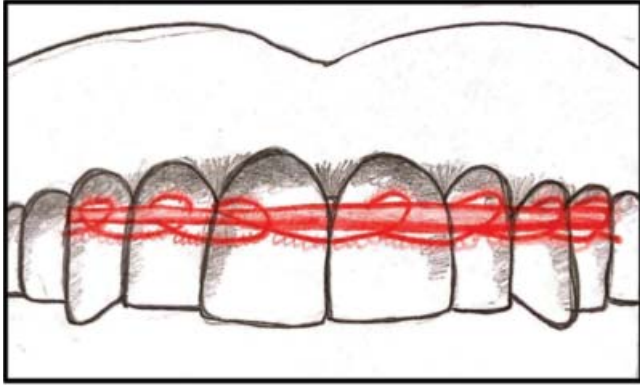


Figure-3: Wire ligature splint.

and needs more operating time when compared to screws for jaw fixation.<sup>27</sup>

**Titanium trauma splints:** This splint was introduced by Von Arx. It consists of a semi-rigid splint made of titanium. It comprises of a wire with 2.8 mm width and 0.2 mm thickness (Figure-4). Flowable composite resin is used to adapt the rhomboid mesh structure of this splint to the tooth surface. A disadvantage of this type of splint is its

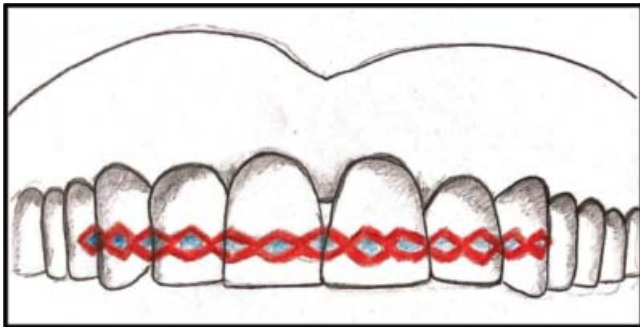


Figure-4: Titanium trauma splint.

relatively high price. It does not irritate gingival tissues when compared to the arch bar splint.<sup>23</sup>

### Resin Based Splints

**Fiber splints:** Unpleasant appearance of wires displaying through composites or fracture susceptibility in interproximal region when composites are used alone is one of the biggest drawbacks.<sup>27</sup> The advancement of fiber-reinforced composite (FRC) has introduced a new regime into in to the domain of adhesive aesthetic dentistry.<sup>28</sup> The blend of composite resin and FRC has been shown to serve as an attractive choice due to noteworthy paybacks in terms of physical properties,<sup>29</sup> the likelihood of direct application and the property to

bond to tooth structure.<sup>30</sup> Different fiber types such as glass fibers, Vectran fibers, Kevlar fibers, carbon fibers and polyethylene fibers have been added to composite materials.<sup>31</sup> Fiber made of Carbon offers greater fatigue and fracture resistance and reinforce composite material, but they are esthetically unattractive due to their dark color.<sup>31,32</sup> Kevlar fibers, have aromatic polyamide in it to increase the impact strength of resin based material, but they are also unattractive and thus their use is limited.<sup>33</sup> Vectran fibers are artificial fibers and have good strength, but their use is limited due to its high cost.<sup>31</sup> However, polyethylene fibers offers a good impact strength, elasticity and flexibility of composite materials. In comparison to other fibers, they are almost indiscernible in the resinous matrix hence proved to be aesthetically pleasing yet reinforcing composite material.<sup>30</sup>

**Ribbon:** This was introduced in 1992 consisting of

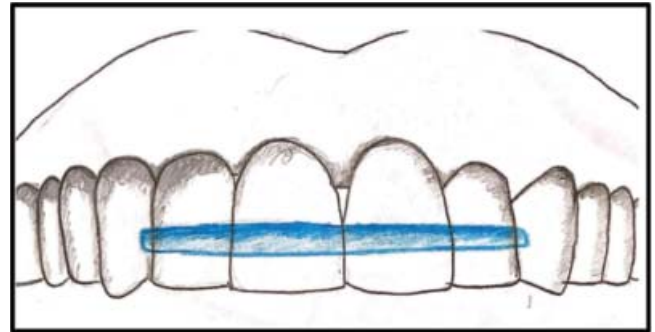


Figure-5: Ribbon.

ultrahigh strength polyethylene fibers<sup>34</sup> (Figure-5). It acts as a semi-rigid splints to stabilize traumatized teeth during healing phase with favourable outcomes.<sup>7,35</sup> The high molecular weight fiber produced by gas-plasma treatment helps it in achieving a bond with composite resin, rather than being simply surrounded with the resin.<sup>31</sup> Its high strength and fracture toughness is due to the highly cross linked structure of the fiber. These fibers surpass the breaking point of fiberglass and are so hard that special cutting tools are needed to amend them.<sup>34</sup> Its easy to place, can be shaped and adapted to the teeth until cured, and aesthetically pleasing. Splints are smooth, thin and non-irritating to the injured lip.<sup>36</sup> Also, the bonding ability between resin and reinforcing fiber is superior to that between resin and casting metal. It lacks shape memory and if placed inaccurately, resulting voids and excessive composites make it more susceptible to fracture.<sup>34</sup>

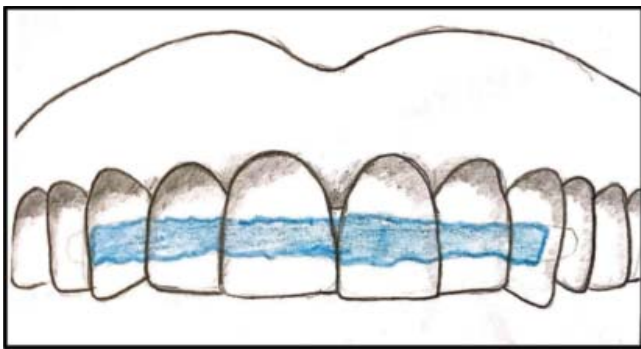
**Single layer fiber glass (SFG):** The technique named Single-layer fiberglass (SFG) was introduced for stabilizing

traumatized teeth. It is used worldwide.<sup>37</sup> Glass fibers, consisting of filamentous glass particles, to improve the impact strength of composite materials. They have aesthetically desirable properties, but they do not simply bind to the resinous matrix.<sup>38</sup> They are easy to apply but difficult to cut. According to a study by Hassan *et al.*, the single-layer fiberglass splints have rigidity comparable to that of the twistflex steel wire.<sup>26</sup> A clinical trial by Khidr *et al.* concluded that fiber glass splint was proved to be cheap, easy to use, non-invasive, and less time consuming in application or removal. They are well tolerated by the patients; more aesthetic and offers good quality hygiene maintenance.<sup>39</sup>

**Double layer fiber glass (DFG):** It works on the same principles as discussed in SFG however in comparison to SFG it takes more time for application and gives less pleasant aesthetics. The DFG is stiffer than SFG hence not recommended for flexible splinting.<sup>26</sup>

**Power chain composite splint:** The orthodontic chain made of elastic material is very commonly used for the purpose of traction. It is also used in trauma cases for reduction and stabilization of jaw fractures. It is low cost, flexible material, easily available in all orthodontic practices.<sup>40,41</sup> The holes in its structure help it retaining the composite material mechanically adhering the chain to the tooth surface. It is easy to apply and gives good aesthetic outcomes. Hassan *et al.* compared the stiffness of twistflex wire, titanium trauma splint, single & double fiberglass, nylon fishing line, and power chain for splinting of mobile teeth.<sup>26</sup> They concluded that, to fulfil the criteria of flexible splints as per IADT recommendations, preference should be given to fishing line followed by power chain and titanium trauma splints.<sup>26</sup> Of these, fishing line and power chain supersedes other techniques due to additional benefits of low cost and high aesthetics.<sup>26</sup>

**Composite splints:** In this splinting technique,



**Figure-6:** Composite resin splint.

composite resin is applied to the facial and interproximal surfaces of the affected teeth along with adjacent teeth (Figure-6). Literature reports that interproximal composites on the adjacent teeth are prone to fracture.<sup>3</sup> According to IADT guidelines, resin bonded to the teeth is a non-functional splint and is not endorsed.<sup>3</sup> It results in greater gingival irritation in comparison to orthodontic bracket splint, titanium trauma splint or composite splints with wires.<sup>42</sup> Composite utilized with various other splint types causes possible iatrogenic damage which cannot be underestimated. A major drawback of using composite for stabilization of traumatized teeth is the difficulty in removal of the resin due to its strong adherence to enamel. Iatrogenic loss of the enamel is also an unavoidable outcome.<sup>43</sup>

### Other Splints

**Acrylic Cap Splint:** It is a simple appliance comprising of acrylic flanges. It embraces the crown and interdental spaces in order to achieve retention. A diameter of 1.25mm is wrapped around distal end. It is first made in wax followed by replacement with wax in final process. It is preferable to make the splint with heat cure acrylic however in case of urgency, cold cure acrylic can also be used. This technique was further modified. The improved version lacks intermaxillary fixation and offers better patient compliance and masticatory function. It has a modified design which lacks occlusal coverage in anterior and posterior region bilaterally.<sup>44</sup> It is indicated when patient has displaced fractures but not enough teeth thus omitting the need of wiring around dentition or when there are chances of iatrogenic trauma to developing tooth buds and partially erupted teeth while screw fixation.<sup>45</sup>

**GC Fuji:** Due to unavoidable outcomes of composite, alternative method of splinting was introduced by Jun-Y Hu which should not just be easily applied, but also easy to remove without damaging the tooth structure. It should have sufficient bonding to withstand forces during the splinting.<sup>43</sup> Nylon fishing line is adapted to the facial surfaces of the injured tooth and the two adjacent teeth.

This technique with incorporation of 0.8 mm wire or more rather than nylon fishing line can be used as a rigid splint. Removal of splint is easy and can simply be done with the help of spoon excavator followed by polishing the enamel with rubber cup.<sup>23</sup>

**Emergency splints:** An alternative approach was introduced for medical emergency departments based on the concept of crudely stabilizing the teeth in the socket

with the help of a skin barrier material Stomahesive.<sup>23</sup> It also covers the tooth structure facially which helps in reducing post trauma sensitivity. However, further fine adjustments may be needed in dental office subsequently.<sup>23</sup>

In case of emergency, orthodontic retainers, patient's mouth guard or aluminum foil covered with thermoplastic acrylic can also be utilized for stabilizing avulsed or luxated teeth.<sup>46</sup> An in vitro study compared various splinting techniques for managing dentoalveolar trauma with respect to superiority and time to finish each splinting procedure. The results concluded that operators favoured the use of light-cured composite technique and bonded ribbon for management of avulsed or fractured tooth over the commonly stated procedures.<sup>47</sup>

### Evidence in support of the current recommendations

The tendency of functional splints to stabilize traumatized teeth is reinforced in lately published reviews.<sup>18,48,49</sup> The standard protocol for management of dental trauma by the AAE and IADT require a functional splint for avulsion and luxation injuries, but the treatment regime for alveolar fractures and root fractures is ambiguous. Other types of dental trauma do require stabilization with a splint but the amount of stiffness is not clarified.<sup>12</sup>

There is literature in favour of managing root fractures analogous to luxation injuries utilizing a functional splint for 3-4 weeks.<sup>50-52</sup> Despite multiple evidences, the type of splint and the time period of splinting do not significantly affect the healing.<sup>53,54</sup> Therefore, a functional splint is advised for avulsion injuries. It takes a week for periodontal apparatus to heal during which the teeth are stabilized using a splint to prevent further trauma or tooth loss.<sup>55</sup>

### Conclusion

Splints are used to achieve optimum fixation and stabilization of traumatized teeth in its bony housing for the time recommended by literature. It should be flexible and passive. It should neither irritate the oral mucosa nor should it be plaque retentive. New innovations i.e. composite and fiber based splints have adequate strength and are easy to apply. They are successful in replacing materials used in past. To conclude, the type and time of splinting depends on the type of injury and the amount of stabilization needed for the specific injury.

**Disclosure:** We have no financial interest, arrangement or affiliation that would constitute a conflict of interest.

**Funding Source:** None.

### References

1. von Arx T, Filippi A, Lussi A. Comparison of a new dental trauma splint device (TTS) with three commonly used splinting techniques. *Dent Traumatol* 2001;17:266-74.
2. Andreasen JO, Andreasen FM, Andersson L. Textbook and color atlas of traumatic injuries to the teeth, 5th ed. Hoboken, USA: John Wiley & Sons Inc, 2019, pp 1064.
3. Oikarinen K. Tooth splinting: a review of the literature and consideration of the versatility of a wire-composite splint. *Endod Dent Traumatol* 1990;6:237-50.
4. Andreasen JO. Traumatic injuries of the teeth. Philadelphia, USA: Saunders, 1981; pp 462.
5. Andreasen JO. The effect of splinting upon periodontal healing after replantation of permanent incisors in monkeys. *Acta Odontol Scand* 1975;33:313-23.
6. Andersson L, Lindskog S, Blomlof L, Hedstrom KG, Hammarstrom L. Effect of masticatory stimulation on dentoalveolar ankylosis after experimental tooth replantation. *Endod Dent Traumatol* 1985;1:13-6.
7. Andreasen JO, Andreasen FM, Mejäre I, Cvek M. Healing of 400 intra-alveolar root fractures. 2. Effect of treatment factors such as treatment delay, repositioning, splinting type and period and antibiotics. *Dent Traumatol* 2004;20:203-11.
8. International Association of Dental Traumatology. Dental Trauma Guidelines 2012. [Online] 2013 [Cited 2019 December 14]. Available from URL: <https://www.iadt-dentaltrauma.org/1-9%20%20iad%20guidelines%20combined%20-%201r%20-%2011-5-2013.pdf>
9. Hinckfuss SE, Messer LB. Splinting duration and periodontal outcomes for replanted avulsed teeth: a systematic review. *Dent Traumatol* 2009;25:150-7.
10. Andreasen JO. Periodontal healing after replantation of traumatically avulsed human teeth: Assessment by mobility testing and radiography. *Acta Odontol Scand* 1975;33:325-35.
11. Nasjleti CE, Castelli WA, Caffesse RG. The effects of different splinting times on replantation of teeth in monkeys. *Oral Surg Oral Med Oral Pathol* 1982;53:557-66.
12. Kahler B, Heithersay GS. An evidence-based appraisal of splinting luxated, avulsed and root-fractured teeth. *Dent Traumatol* 2008;24:2-10.
13. Berude JA, Hicks ML, Sauber JJ, Li SH. Resorption after physiological and rigid splinting of replanted permanent incisors in monkeys. *J Endod* 1988;14:592-600.
14. Andreasen FM, Andreasen JO, Bayer T. Prognosis of root-fractured permanent incisors--prediction of healing modalities. *Endod Dent Traumatol* 1989;5:11-22.
15. Pan CS, Walker RT. Root fractures: a case of dental non-intervention. *Endod Dent Traumatol* 1988;4:186-8.
16. Tziafas D, Margelos I. Repair of untreated root fracture: a case report. *Endod Dent Traumatol* 1993;9:40-3.
17. Cvek M, Andreasen JO, Borum MK. Healing of 208 intra-alveolar root fractures in patients aged 7-17 years. *Dent Traumatol* 2001;17:53-62.
18. Bakland LK, Andreasen JO. Dental traumatology: essential diagnosis and treatment planning. *Endod Topics* 2004;7:14-34.
19. Kehoe JC. Splinting and replantation after traumatic avulsion. *J Am Dent Assoc* 1986;112:224-30.
20. Kristerson L, Andreasen JO. The effect of splinting upon periodontal and pulpal healing after autotransplantation of mature and immature permanent incisors in monkeys. *Int J Oral Surg* 1983;12:239-49.
21. Leith R, O'Connell AC. Tips for splinting traumatised teeth. *J Ir Dent Assoc* 2017;63:260-62.

22. Oikarinen K. Comparison of the flexibility of various splinting methods for tooth fixation. *Int J Oral Maxillofac Surg* 1988;17:125-7.
23. Kahler B, Hu JY, Marriot-Smith CS, Heithersay GS. Splinting of teeth following trauma: a review and a new splinting recommendation. *Aust Dent J* 2016;61(Suppl 1):59-73. doi: 10.1111/adj.12398.
24. Gautam S, Thapa A. Composite Wire Splint, an Economical, Maintainable and Flexible Option, in Stabilizing Luxated, Avulsed and Intruded Teeth: A Prospective Study. *Nepal Med Coll J* 2016;18:124-27.
25. Kwan SC, Johnson JD, Cohenca N. The effect of splint material and thickness on tooth mobility after extraction and replantation using a human cadaveric model. *Dent Traumatol* 2012;28:277-81. doi: 10.1111/j.1600-9657.2011.01086.
26. Ben Hassan MW, Andersson L, Lucas PW. Stiffness characteristics of splints for fixation of traumatized teeth. *Dent Traumatol* 2016;32:140-5. doi: 10.1111/edt.12234.
27. Sekar K, Natarajan PM, Kapasi A. Comparison of Arch Bar, Eyelets and Transmucosal Screws for Maxillo Mandibular Fixation in Jaw Fracture. *Biomed Pharmacol J* 2017;10:497-508.
28. Scribante A, Vallittu PK, Özcan M. Fiber-Reinforced Composites for Dental Applications. *Biomed Res Int* 2018;2018:e4734986. doi: 10.1155/2018/4734986.
29. Vallittu PK. Flexural properties of acrylic resin polymers reinforced with unidirectional and woven glass fibers. *J Prosthet Dent* 1999;81:318-26.
30. Vallittu PK, Sevelius C. Resin-bonded, glass fiber-reinforced composite fixed partial dentures: a clinical study. *J Prosthet Dent* 2000;84:413-8.
31. Vitale MC, Caprioglio C, Martignone A, Marchesi U, Botticelli AR. Combined technique with polyethylene fibers and composite resins in restoration of traumatized anterior teeth. *Dent Traumatol* 2004;20:172-7.
32. Aizenbud D, Hazan-Molina H, Emodi O, Rachmiel A. The management of mandibular body fractures in young children. *Dent Traumatol* 2009;25:565-70. doi: 10.1111/j.1600-9657.2009.00815.
33. Zimmermann CE, Troulis MJ, Kaban LB. Pediatric facial fractures: recent advances in prevention, diagnosis and management. *Int J Oral Maxillofac Surg* 2006;35:2-13.
34. Ganesh M, Tandon S. Versatility of ribbon in contemporary dental practice. *Trends Biomater Artif Organs* 2006;20:53-8.
35. Yildirim Oz G, Atao?lu H, Kir N, Karaman AI. An alternative method for splinting of traumatized teeth: case reports. *Dent Traumatol* 2006;22:345-9.
36. Tuloglu N, Bayrak S, Tunc ES. Different clinical applications of bondable reinforcement ribbon in pediatric dentistry. *Eur J Dent* 2009;3:329-34.
37. Andersson L, Friskopp J, Blomlöf L. Fiber-glass splinting of traumatized teeth. *ASDC J Dent Child* 1983;50:21-4.
38. Vallittu PK, Vojtkova H, Lassila VP. Impact strength of denture polymethyl methacrylate reinforced with continuous glass fibers or metal wire. *Acta Odontol Scand* 1995;53:392-6.
39. Khidr HK, El Sheikh SA, Melek LN. Evaluation of the efficacy of fiber glass splinting for fixation of dento-alveolar fractures in children. *Alex Dent J* 2017;42:119-26.
40. Kanuru RK, Azaneen M, Narayana V, Kolasani B, Indukuri RR, Babu PF. Comparison of canine retraction by in vivo method using four brands of elastomeric power chain. *J Int Soc Prev Community Dent* 2014;4(Suppl 1):S32-7. doi: 10.4103/2231-0762.144586.
41. Cousin GC. Wire-free fixation of jaw fractures. *Br J Oral Maxillofac Surg* 2009;47:521-4. doi: 10.1016/j.bjoms.2009.06.010.
42. Filippi A, von Arx T, Lussi A. Comfort and discomfort of dental trauma splints - a comparison of a new device (TTS) with three commonly used splinting techniques. *Dent Traumatol* 2002;18:275-80.
43. Cehreli ZC, Lakshmiopathy M, Yazici R. Effect of different splint removal techniques on the surface roughness of human enamel: a three-dimensional optical profilometry analysis. *Dent Traumatol* 2008;24:177-82. doi: 10.1111/j.1600-9657.2007.00491.
44. Kumar N, Richa, Gauba K. Modified closed cap splint: Conservative method for minimally displaced pediatric mandibular fracture. *Saudi Dent J* 2018;30:85-8. doi: 10.1016/j.sdentj.2017.11.002.
45. Kale TP, Urologin SB, Kapoor A, Lingaraj JB, Kotrashetti SM. Open cap splint with circummandibular wiring for management of pediatric mandibular parasymphysis/symphysis fracture as a definitive treatment modality; a case series. *Dent Traumatol* 2013;29:410-5. doi: 10.1111/j.1600-9657.2011.01082.
46. DeAngelis AF, Barrowman RA, Harrod R, Nastri AL. Review article: Maxillofacial emergencies: dentoalveolar and temporomandibular joint trauma. *Emerg Med Australas* 2014;26:439-45. doi: 10.1111/1742-6723.12267.
47. McIntosh MS, Konzelmann J, Smith J, Kalynych CJ, Wears RL, Schneider H, et al. Stabilization and treatment of dental avulsions and fractures by emergency physicians using just-in-time training. *Ann Emerg Med* 2009;54:585-92. doi: 10.1016/j.annemergmed.2009.06.510.
48. Barrett EJ, Kenny DJ. Avulsed permanent teeth: a review of the literature and treatment guidelines. *Endod Dent Traumatol* 1997;13:153-63.
49. Trope M. Clinical management of the avulsed tooth: present strategies and future directions. *Dent Traumatol* 2002;18:1-11.
50. Cvek M, Andreasen JO, Borum MK. Healing of 208 intra-alveolar root fractures in patients aged 7-17 years. *Dent Traumatol* 2001;17:53-62.
51. Cvek M, Mejäre I, Andreasen JO. Healing and prognosis of teeth with intra-alveolar fractures involving the cervical part of the root. *Dent Traumatol* 2002;18:57-65.
52. Welbury R, Kinirons MJ, Day P, Humphreys K, Gregg TA. Outcomes for root-fractured permanent incisors: a retrospective study. *Pediatr Dent* 2002;24:98-102.
53. Andreasen JO, Borum MK, Jacobsen HL, Andreasen FM. Replantation of 400 avulsed permanent incisors. 2. Factors related to pulpal healing. *Endod Dent Traumatol* 1995;11:59-68.
54. Andreasen JO, Borum MK, Jacobsen HL, Andreasen FM. Replantation of 400 avulsed permanent incisors. 4. Factors related to periodontal ligament healing. *Endod Dent Traumatol* 1995;11:76-89.
55. Andreasen JO. A time-related study of periodontal healing and root resorption activity after replantation of mature permanent incisors in monkeys. *Swed Dent J* 1980;4:101-10.