

## Anatomical variations of sphenoid sinus in terms of volume and protrusions of optic nerve/internal carotid artery in a subgroup of Pakistani population

Asma Aijaz<sup>1</sup>, Talat Samreen<sup>2</sup>, Shazia Fehmi<sup>3</sup>, Afsheen Khan<sup>4</sup>, Hira Ahmed<sup>5</sup>, Nadeem Baig<sup>6</sup>

### Abstract

**Objective:** To compare the volume of sphenoid sinus with protrusions of optic nerve and internal carotid artery in both males and females.

**Method:** The cross-sectional study was conducted from October 2020 to February 2021 at the Radiology Department of Dow University of Health Sciences, Karachi, and comprised males and females aged 20-60 years having no sphenoid sinus bony abnormality. Sphenoid volume and optic nerve and internal carotid artery protrusions were examined in the computed tomography scans of the paranasal sinus. Based on the protrusions, the scan findings were split into four groups: Group 1 had no protrusion, Group 2 had optic nerve protrusion, Group 3 had internal carotid artery protrusion, and Group 4 had protrusions of both the optic nerve and the internal carotid artery. Data was analysed using GraphPad Prism 9.

**Results:** Of the 300 subjects, 171(57%) were males and 129(43%) were females. The overall mean age was 39.27±10.9 years. There were 147(49%) subjects in group 4, followed by 72(24%) in group 3, 42(14%) in group 2 and 39(13%) in group 1. Statistically significant difference was observed between sphenoid volume across the study groups for both male and female subjects ( $p<0.001$ ).

**Conclusion:** There was significant relationship between internal carotid artery and optic nerve protrusions and sphenoid volume.

**Keywords:** Sphenoid sinus, Optic nerve, Internal carotid artery, Computed tomography. (JPMA 74: 1287; 2024)

**DOI:** <https://doi.org/10.47391/JPMA.10644>

### Introduction

The sphenoid sinus (SS) is one of the highly variable pneumatized structure located between the anterior and middle cranial fossa of the skull.<sup>1</sup> It is deeply situated within the body of the sphenoid, and divided by an intersinus septum into right and left air-filled cavities that are variable in size and often asymmetrical.<sup>2</sup> In addition, it shows variations in terms of its degree of pneumatization and relationship with surrounding neurovascular structures, like the internal carotid artery (ICA) and the optic nerve (ON).<sup>3</sup> As the extent of pneumatization into the surrounding structure increases, the size of sinus cavity also increases. This makes the nearby critical neurovascular structures more vulnerable to harm during endoscopic sinus procedures.<sup>4</sup>

The significance of anatomical research on SS is evident by the close correlation of these air cavities with essential vital neurovascular structures, like ICA and ON.<sup>5,6</sup> In cases of extended pneumatization, these structures may protrude

<sup>1-5</sup>Department of Anatomy, Dow University of Health Sciences, Karachi, Pakistan; <sup>6</sup>Department of Anatomy, Karachi Medical and Dental College, Karachi, Pakistan.

**Current Affiliation** (Afsheen Khan): Department of Anatomy, Shaheed Mohtarma Benazir Bhutto Medical College, Karachi, Pakistan

**Correspondence:** Asma Aijaz. e-mail: [asmafkh83@gmail.com](mailto:asmafkh83@gmail.com)

ORCID ID: 0000-0003-3509-3115

**Submission complete:** 12-08-2023

**Review began:** 21-10-2023

**Acceptance:** 11-05-2024

**Review end:** 27-03-2024

into the sinus cavity, sometimes with the absence of bony separation. In such situations, these structures are at high risk of injury at some point of trans-sphenoidal surgical methods, resulting in catastrophic outcomes.<sup>7,8</sup>

With advancements in endoscopic trans-sphenoidal surgery (ETS), the SS has gained special importance. It is not only approached to treat the diseases within the SS, but is also a choice of treatment modality for intrasellar and tumours of the skull base, like pituitary adenomas, chordomas, meningiomas and craniopharyngiomas.<sup>9,10</sup> The ETS is increasingly used due to its minimal invasiveness, better visualisation and low rate of complications compared to the traditional transcranial route.<sup>11</sup> Therefore, a detailed knowledge of variable anatomy of SS has acquired a special importance in planning and managing surgical procedures.

The sphenoid volume (Sv) is significantly related to SS's pneumatization pattern,<sup>12</sup> septation pattern<sup>13,14</sup> and protrusions of ICA and ON.<sup>15</sup> While some studies have employed three-dimensional (3D) models,<sup>12,13</sup> several investigations have used two-dimensional (2D) computed tomography (CT) scans to estimate the sinus volume using various formulas.<sup>16,17</sup>

The frequency of ICA and ON protrusions have been reported in diverse global<sup>3,6,8,9,10,15</sup> and local studies.<sup>18,19</sup> The current study was planned to investigate the critical relationship of Sv with ICA and ON protrusion.

## Patients and Methods

The cross-sectional study was conducted from October 2020 to February 2021 at the Department of Radiology, Dow University of Health Sciences (DUHS), Karachi. After approval from the institutional ethics review board, The sample size was calculated using OpenEpi<sup>20</sup> calculator while keeping the prevalence of paranasal sinus (PNS) variants at 52%<sup>21</sup> with 80% power and 95% confidence level. To increase the study power, the sample size was magnified by >10%.

The sample was raised using convenience sampling technique. Those included were male and female subjects aged 20-60 years with no SS bony abnormality; and with the complaint of headache, mild sinusitis, retention cysts or abnormalities of sinuses other than SS. Patients with chronic rhinosinusitis, sinonasal tumours, nasal polyposis, facial fractures, prior sinus surgery, and congenital craniofacial abnormalities were excluded.

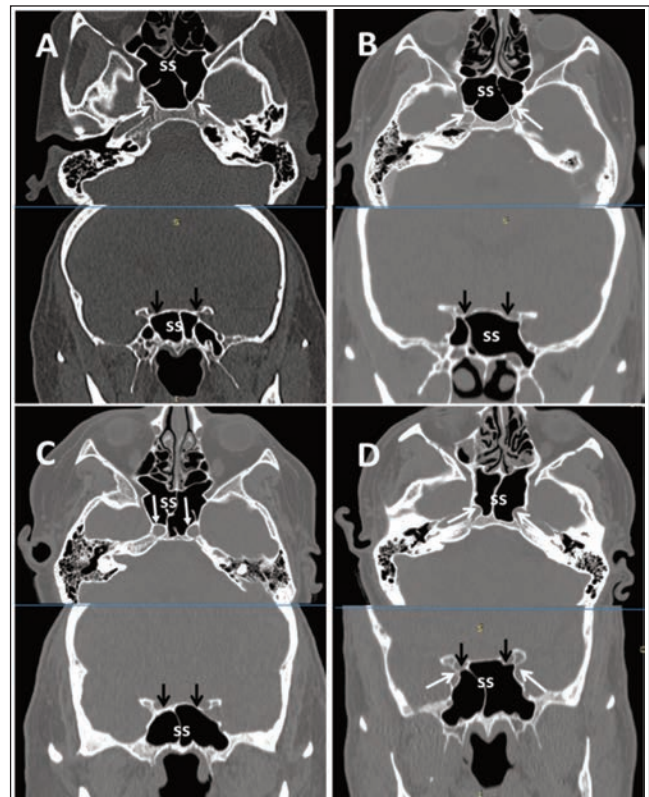
After taking informed consent, the patients were subjected to CT PNS scans (Optima 660, 64-slice CT scanner General Electric Healthcare Computed Tomography system – California, United States), utilising 3mm slice thickness with scan parameters of kV120, 0.5s rotation time and 60-220mA in both bone and soft tissue algorithms. A plane parallel to the hard palate from the upper dental arch to the roof of frontal sinus was taken to obtain axial sections. The coronal and sagittal images were obtained by multiplanar reconstructions performed with Digital Imaging and Communications in Medicine (DICOM) which is the international standard for the digital storage, processing, printing and presentation of medical imaging information and reporting was done through the Health Information and Management System (HIMS) which is a programme to organize and record medical data. A specialist radiologist performed a thorough examination of the scans.

In each scan, the morphology of SS was thoroughly assessed, with special emphasis paid to bony protrusions of ICA and ON into the sinus cavity. In axial and coronal sections, protrusion was defined as indentation to the presence of >50% circumference of structure in the sinus cavity.<sup>7,22</sup> Craniocaudal height, width and anteroposterior length were measured in the sagittal and axial planes for volumetric measures. All measurements were taken at the sinus's maximal dimensions. The volume was computed by multiplying height\*width\*length by 0.52.<sup>16</sup> To investigate the relationship between volume and ICA and ON protrusion, the sample was divided into four groups: Group 1 had no protrusion, Group 2 had ON protrusion, Group 3 had ICA protrusion, and Group 4 had protrusions of both ON and ICA.

Data was analysed using GraphPad Prism 9. Quantitative data was expressed as mean±standard deviation, while qualitative variables were expressed as frequencies and percentages. Shapiro-Wilk test was used to determine data normality. ON protrusion data was not normally distributed. Student's t-test was used to determine the difference between volume and gender, while one-way analysis of variance (ANOVA) was used to evaluate Sv in the four groups of protrusions. Tukey's Honest Significant Difference (HSD) was used for post-hoc analysis.  $P < 0.05$  was considered significant.

## Results

Of the 300 subjects, 171(57%) were males and 129(43%) were females. The overall mean age was  $39.27 \pm 10.9$  years. The male sinuses presented a larger Sv  $11.01 \pm 3.5 \text{cm}^3$  compared to females  $7.70 \pm 2.13 \text{cm}^3$  ( $p < 0.0001$ ). There were 147(49%) subjects in group 4, followed by 72(24%) in group 3, 42(14%) in group 2 and 39(13%) in group 1 (Figure 1). Statistically significant difference was observed between Sv across the study groups for both male and female subjects (Table).

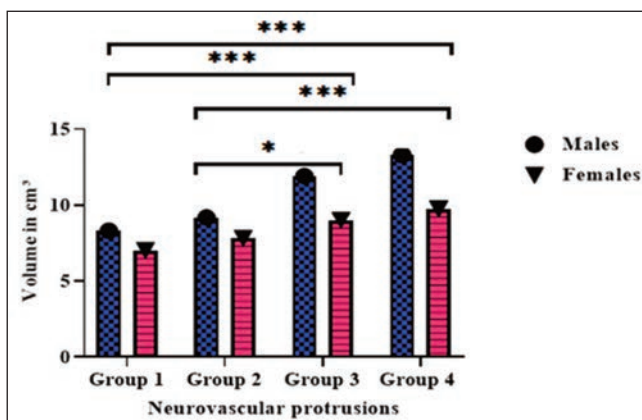


**Figure-1:** Axial and coronal views of examples from the four groups of subjects. (A) Group 1 without any protrusion; (B) Group 2 protrusion of optic nerve (ON); (C) Group 3 protrusion of internal carotid artery (ICA); and (D) Group 4 protrusions of both ICA and ON. White arrows show ICA and black arrows show ON. SS: Sphenoid sinus.

**Table:** Relationship of sphenoid volume with protrusion of optic nerve and internal carotid artery.

Variable	Group 1 (n=39) 13% Mean ±SD	Group 2 (n=42) 14% Mean ±SD	Group 3 (n=72) 24% Mean ±SD	Group 4 (n=147) 49% Mean ±SD	ANOVA p-value
Volume (cm <sup>3</sup> )					
Males	8.34±3.68	9.18±2.44	11.92±2.10	13.36±2.15	<0.001*
Females	7.06±2.0	7.8±1.74	9.0±1.74	9.75±1.67	<0.001*

SD: Standard deviation; ANOVA: Analysis of variance.

**Figure-2:** Post-hoc Tukey's Honest Significant Difference (HSD) analysis of relationship of sphenoid volume with optic nerve (ON) and internal carotid artery (ICA) protrusions. There were significant difference in cross-comparisons.

Sv was significantly higher in group 3 and group 4 patients than in the other groups ( $p < 0.05$ ). There was significant difference in volume ( $p < 0.001$ ) between groups 1 and 3, and between groups 2 and 4 ( $p = 0.001$ ). No significant difference in Sv was observed between groups 1 and 2 and between groups 3 and 4 ( $p > 0.05$ ) (Figure 2).

## Discussion

To the best of our knowledge, the current study was the first to explore the association between Sv and protrusion of ON and ICA in a subset of the Pakistani population.

Sv was traditionally considered challenging air cavities for the surgeon due to its deep placement in the skull. The high variability in the size and pneumatization type has the potential to endanger surrounding vital neurovascular structures, like ICA and ON.<sup>5,6</sup> These structures are at high risk of iatrogenic injury resulting in intracranial bleeding, fatal haemorrhage and visual deficit to complete blindness.<sup>8,9</sup>

With the progressive diffusion of ETS and modern imaging techniques, these air cavities have gained significant importance in surgery. SS represents the basilar route for approaching lesions of pituitary gland as well as tumours involving skull base, parasellar region, cavernous sinus, clivus, and petroclival region.<sup>9</sup> For these reasons, the

knowledge about anatomical variants of SS is essential for accurate surgical planning, and to minimise intrasurgical and postsurgical complications.

Sv is an important parameter for determining anatomical variants of SS and subsequent surgical planning. Significant difference ( $p < 0.001$ ) observed between mean values of males and females in the current study indicates that Sv might be used for evaluation of sexual dimorphism, which is consistent with earlier findings.<sup>12, 23,24</sup> However, Yonetsu et al. and Oliveria et al. reported no significant association between gender and Sv.<sup>17,25</sup> Apart from the association of Sv with protrusion of ON and ICA, it is also related to a number of intersinus septa and risky septal insertion on bony walls of ON and ICA.<sup>13,14</sup>

The presence of relationship between Sv and ON/ICA protrusion may be justified by the presence of protrusion of these vital structures in cases of extended pneumatization of SS.<sup>2,5,7</sup> It is also supported by the fact that during development, as the sinus cavity expands, it comes into intimate relationship with ON and ICA.<sup>26</sup> The finding of significant association between Sv and different groups of protrusion of ON and ICA ( $p < 0.001$ ) is consistent with earlier findings.<sup>15</sup>

The current results revealed that Sv was higher in subjects with combined protrusion of ON and ICA or in sinuses with ICA protrusion alone. However, there was no difference in Sv with ON protrusion and without any protrusion, which means that isolated ON protrusion was independent of Sv.

The results are of great importance from a surgical point of view as they highlight the fact that ICA protrusion can be encountered in sinuses with larger volume and extended pneumatization, whereas ON protrusion can be present in sinuses with smaller volume. Hence, the protrusion of ON is more fortuitous than ICA protrusion, and should be verified carefully in all cases on preoperative CT scans to avoid any complications.

The presence of protrusion of neurovascular structures into the SS is not only influenced by extended pneumatization alone but also by other variants such as the position of ON and their respective orientation. Therefore, it is recommended to perform future studies to verify if the same phenomenon may be shared by other neural structures often protruding into the sphenoid sinus like maxillary and vidian nerves.

The present study has several limitations as it was conducted at a single centre. A multi-centre study with a large sample size is recommended to obtain generalizable results. Also, there should have been a confirming endoscopic correlation with CT images because the prevalence of surgical complications is unknown.



## Conclusion

There was a significant relationship between Sv and protrusions of ICA and ON. Large sinuses increased the likelihood of ICA and ON protrusions, making these sensitive structures vulnerable to iatrogenic injury during trans-sphenoid surgical procedures. Hence, a detailed CT sinus examination is strongly recommended prior to trans-sphenoidal surgical procedure.

**Disclaimer:** None.

**Conflict of Interest:** None.

**Source of Funding:** None.

## References

1. Standring S. Gray's anatomy e-book: the anatomical basis of clinical practice 42nd ed. Churchill Livingstone: Elsevier Health Sciences, 2021.
2. Gldner C, Pistorius SM, Diogo I, Bien S, Sesterhenn A, Werner JA. Analysis of pneumatization and neurovascular structures of the sphenoid sinus using cone-beam tomography (CBT). *Acta Radiologica*. 2012; 53:214-9. doi:10.1258/ar.2011.110381
3. Anusha B, Baharudin A, Philip R, Harvinder S, Shaffie BM, Ramiza RR. Anatomical variants of surgically important landmarks in the sphenoid sinus: a radiologic study in Southeast Asian patients. *Surg Radiol Anat*. 2015; 37:1183-90. doi:10.1007/s00276-015-1494-8
4. Vaezi A, Cardenas E, Pinheiro-Neto C, Paluzzi A, Branstetter IV BF, Gardner PA, et al. Classification of sphenoid sinus pneumatization: relevance for endoscopic skull base surgery. *Laryngoscope*. 2015; 125:577-81. doi:10.1002/lary.24989.
5. Rahmati, A, Ghafari R, AnjomShoa M. Normal variations of sphenoid sinus and the adjacent structures detected in cone beam computed tomography. *J Dent*. 2016; 17:32-7.
6. Stokovic N, Trkujla V, Dumic-Cule, Cukovic-Bagic, Lauc T, Vukicevic S, et al. Sphenoid sinus types, dimensions and relationship with surrounding structures. *Ann Anat*. 2016; 203:69-76. doi:10.1016/j.aanat.2015.02.013.
7. Refaat R, Basha MA. The impact of sphenoid sinus pneumatization type on the protrusion and dehiscence of the adjacent neurovascular structures: A prospective MDCT imaging study. *Acad Radiol*. 2020; 27: 132-9. doi:10.1016/j.acra.2019.09.005
8. Raseman J, Guryildirim M, Beer-Furlan A, Jhaveri M, Tajudeen BA, Byrne RW, et al. Preoperative Computed Tomography Imaging of the Sphenoid Sinus: Striving Towards Safe Transsphenoidal Surgery. *J Neuro Surg B Skull Base*. 2020; 81: 251-62. doi:10.1055/s-0039-1691831
9. Anusha B, Baharudin A, Philip R, Harvinder S, Shaffie BM. Anatomical variations of the sphenoid sinus and its adjacent structures: a review of existing literature. *Surg Radiol Anat*. 2014; 36:419-27.
10. Cavallo LM, Somma T, Solari D, Iannuzzo G, Frio F, Baiano C, et al. Endoscopic Endonasal Transsphenoidal Surgery: History and Evolution. *World Neurosurg*. 2019; 127: 686-94. Doi:10.1016/j.wneu.2019.03.048
11. Agam MS, Zada G. Complications associated with transsphenoidal pituitary surgery: Review of the Literature. *J. Neurosurg*. 2018; 65:69-73. doi:10.1093/neuros/nyy160
12. Gibelli D, Cellina M, Gibelli S, Oliva AG, Codari M, Termine G, et al. Volumetric assessment of sphenoid sinuses through segmentation on CT scan. *Surg Radiol Anat*. 2018; 40: 193-8. doi:10.1007/s00276-017-1949-1
13. Gibelli D, Cellina M, Gibelli S, Cappella A, Oliva AG, Termine G, et al. Relationship between sphenoid sinus volume and accessory septations: a 3D assessment of risky anatomical variants for endoscopic surgery. *Anat Rec*. 2020; 303:1300-4. doi: 10.1002/ar.24245
14. Aijaz A, Khan N, Mubeen S, Rasheed B. Anatomical variations of human sphenoid sinus in terms of volume and septation pattern in a subset of Pakistani population using computed tomographic images. *J Pak Med Assoc*. 2022; 72:702-6. doi.org/10.47391/JPMA.3543
15. Gibelli D, Cellina M, Gibelli S, Cappella A, Oliva AG, Termine G, et al. Relationship between sphenoid sinus volume and protrusion of internal carotid artery and optic nerve: a 3D segmentation study on maxillofacial CT-scans. *Surg Radiol Anat*. 2019; 41: 507-12. doi: 10.1007/s00276-019-02207-w
16. Selcuk OT, Erol B, Renda L, Osma U, Eyigor H, Gunsoy B, et al. Do altitude and climate affect paranasal sinus volume? *J. Cranio-Maxillofac Surg*. 2015; 43:1059-64. doi:10.1016/j.jcms.2015.05.013
17. Yonetsu K, Watanabe M, Nakamura T. Age-related expansion and reduction in aeration of the sphenoid sinus: volume assessment by helical CT scanning. *Am J Neuroradiol*. 2000; 21:179-82.
18. Aijaz A, Ahmed H, Fahmi S, Samreen T, Rasheed B, Jabeen H. A Comprehensive Computed Tomographic Analysis of Pneumatization Pattern of Sphenoid Sinus and Their Association with Protrusion/Dehiscence of Vital Neurovascular Structure in a Pakistani Subgroup. *Turk Neurosurg*. 2023; 33:501-8. doi: 0.5137/1019-5149.JTN.40154-22.3
19. Farhan N, Naqvi SU, Rasheed B, Sattar A, Khan M, Rahim A, et al. Identification of Significant Anatomical Variations in the Nose and Anterior Skull Base Using Computed Tomography: A Cross-Sectional Study. *Cureus*. 2020; 12:49-5. DOI: 10.7759/cureus.8449
20. Dean Ag, Sullivan KM, Soe MM. Open Epi: Open Source Epidemiologic Statistics for Public Health Version. [Online] [Cited 2023 February 21]. Available from: URL: <http://www.OpenEpi.com>
21. Lakhani M, Ali M, Sadiq M, Hassan N. Analysis of optic nerve types in relation to posterior paranasal sinuses: a computed tomographic study. *Ann Abbasi Shaheed Hosp KMDC*. 2017; 22:249-54. doi.org/10.58397/ashkmdc.v22i4.140.
22. Unal B, Bademci G, Bilgili YK, Batay F, Avci E. Risky anatomic variations of sphenoid sinus for surgery. *Surg Radiol Anat*. 2006; 28:195-201. doi: 10.1007/s00276-005-0073-9.
23. Cohen O, Warman M, Fried M, Shoffel-Havakuk H, Adi M, Halperin D, et al. Volumetric analysis of the maxillary, sphenoid and frontal sinuses: a comparative computerized tomography based study. *Auris Nasus Larynx*. 2018; 45:96-102. Doi:10.1016/j.anl.2017.03.003.
24. Oliveira JX, Perrella A, Santos KC, Sales MA, Cavalcanti MG Accuracy assessment of human sphenoidal sinus volume and area measure and its relationship with sexual dimorphism using the 3D-CT. *Rev Inst CincSade*. 2009; 27:390-3.
25. Oliveira JM, Alonso MB, De Sousa MJ, Fuziy A, Scocate AC, Costa AL. Volumetric study of sphenoid sinuses: anatomical analysis in helical computed tomography. *Surg Radiol Anat*. 2017; 39:367-74. doi:10.1007/s00276-016-1743-5
26. Catala M. Embryology of the sphenoid bone. *J Neuroradiol*. 2003; 30: 196-200.

### Author Contribution:

AA: Concept, data acquisition, drafting, revision and final approval.  
TS: Concept, data acquisition, drafting and revision.

SF, AK, HA: Data analysis, interpretation,  
NB: Final approval.