

## Super Mario sign at somatostatin receptor PET/CT

Sharjeel Usmani, Khulood Al Riyami, Anjali Jain, Muneera Al Maraghy

Sultan Qaboos Comprehensive Cancer Care and Research Center (SQCCCRC), Muscat Oman

**Correspondence:** Aamna Hassan. e-mail: aamnah@skm.org.pk

ORCID ID. 0000-0003-0026-0729

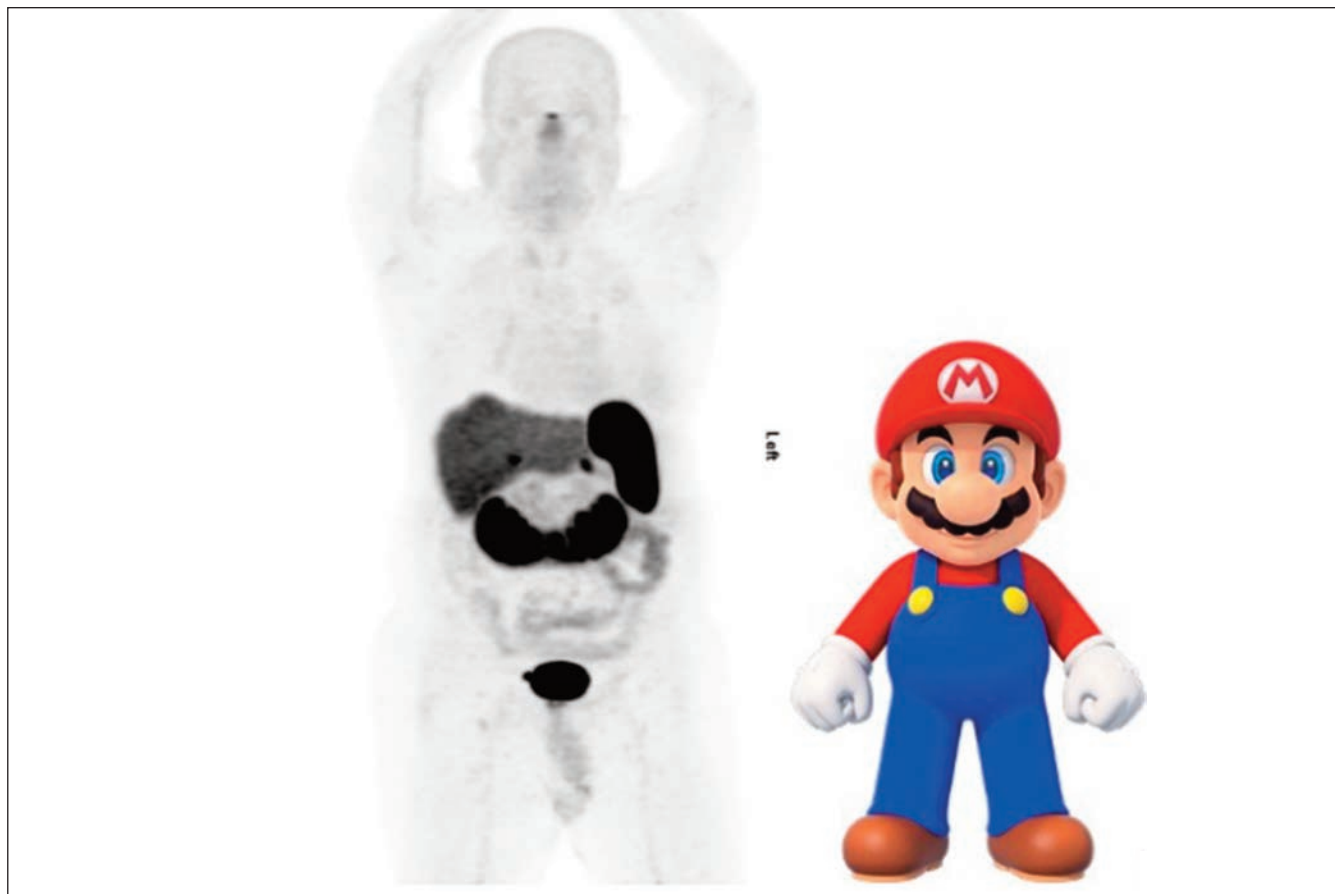
### Abstract

$^{68}\text{Ga}$ -DOTA NOC PET-CT imaging has been shown to have high accuracy for the evaluation of neuroendocrine tumours. We present the case of a 59-year-old male with well differentiated gastric neuroendocrine tumour (grade II) treated with surgery.  $^{68}\text{Ga}$ -DOTA NOC PET/CT was performed to rule out metastasis.  $^{68}\text{Ga}$ -DOTA NOC showed physiological uptake in the bilateral adrenal and horseshoe kidney appearing as the famous character Super Mario. There is no evidence of any abnormal somatostatin avid lesion.

**Keywords:**  $^{68}\text{Ga}$ -DOTA NOC PET-CT, horseshoe kidney, neuroendocrine tumors, PET/CT

**DOI:** <https://doi.org/10.47391/JPMA.24-56>

$^{68}\text{Ga}$ -DOTA-peptide PET/CT is a sensitive imaging tool for a wide range of neuroendocrine tumours (NET).  $^{68}\text{Ga}$ -DOTA-peptides bind to the somatostatin receptor (SSTR).<sup>1,2</sup> SSRs are expressed in several normal cells including the pituitary, thyroid, spleen, kidney, adrenals and excretory activity in the urinary tract. Variable uptake can often be seen owing to variable excretion and receptor expression in normal cells.<sup>3</sup> The small  $^{68}\text{Ga}$ -DOTA peptide is filtered through glomeruli but also partially reabsorbed in the proximal tubule, resulting in high activity in the collecting system and bladder as well as



**Figure:**  $^{68}\text{Ga}$ -DOTA NOC show physiological uptake in the bilateral adrenals and horseshoe kidney appearing as famous character Super Mario.

retained activity in the renal parenchyma.<sup>4</sup>

We present the case of 59-year-old male with well differentiated gastric neuroendocrine tumour (grade II) treated with surgery. <sup>68</sup>Ga-DOTA NOC PET/CT is performed to rule out metastasis. a) Anterior MIP <sup>68</sup>Ga-DOTA NOC shows physiological uptake in the bilateral adrenal and horseshoe kidney appearing as famous character Super Mario. There is no evidence of any abnormal somatostatin avid lesion.

## References

1. Kabasakal L, Demirci E, Ocak M, et al. Comparison of <sup>68</sup>Ga-DOTATATE and <sup>68</sup>Ga-DOTANOC PET/CT imaging in the same patient group with neuroendocrine tumours. *Eur J Nucl Med Mol Imaging*. 2012;39:1271–1277
  2. Virgolini I, Ambrosini V, Bomanji JB, et al. Procedure guidelines for PET/CT tumour imaging with <sup>68</sup>Ga-DOTA-conjugated peptides: <sup>68</sup>Ga-DOTA-TOC, <sup>68</sup>Ga-DOTA-NOC, <sup>68</sup>Ga-DOTA-TATE. *Eur J Nucl Med Mol Imaging*. 2010;37:2004–2010.
  3. Agrawal K, Esmail AA, Gnanasegaran G, et al. Pitfalls and Limitations of Radionuclide Imaging in Endocrinology. *Semin Nucl Med*. 2015;45:440-457
  4. Hofman MS, Lau WF, Hicks RJ. Somatostatin receptor imaging with <sup>68</sup>Ga DOTATATE PET/CT: clinical utility, normal patterns, pearls, and pitfalls in interpretation. *Radiographics*. 2015;35:500-516.
-