IMAGING CORNER

Intracranial Arteriovenous Malformation with Multiple Distal Anterior Cerebral Artery Aneurysms

Muhammad Naveed Majeed[1], Muhammad Qasim Qureshi[2], Qasim Bashir[3], Hafiz Talha Javed[4]
[1]Punjab Institute of Neurology; [2]King Edwards Medical University; [3]Punjab Institute of Neuroscience, Lahore Pakistan; [4]University of Arkansas doe Medical Center, Arkansas, USA.
Correspondence: Aamna Hassan. e-mail: aamnah@skm.org.pk
ORCID ID. 0000-0003-0026-0729

Abstract

Cerebral aneurysms are frequently seen, but the concomitant occurrence of multiple aneurysms along the anterior cerebral artery (ACA) leading to an arteriovenous malformation (AVM) is a rarity. Here we present a case of a woman who presented with subarachnoid haemorrhage due to a ruptured aneurysm. Angiographic imaging revealed multiple aneurysms along the ACA. She underwent successful neuroendovascular coiling, and the recovery was satisfactory.

Keywords: Arteriovenous malformation, distal anterior cerebral artery aneurysms, digital subtraction angiography

DOI: https://doi.org/10.47391/JPMA.26-15

A 43-year-old woman developed sudden onset severe headaches accompanied by vomiting. CT head (plain) revealed subarachnoid haemorrhage and CT angiography showed multiple saccular aneurysms along distal anterior cerebral artery (DACA) (Figure 1). Digital subtraction angiography (DSA) confirmed five aneurysms along right ACA, along with an arteriovenous malformation (AVM). Right A2 ACA aneurysm measured 5.62mm in depth and 5.40mm in width, while the A2-A3 ACA junction aneurysm was 7.43mm by 4.09mm, with multiple smaller aneurysms along the A3 ACA segment. Repeat DSA four months later showed persistent aneurysms with decreased flow through the AVM. The decreased flow was felt to be due to arterial steal to the contralateral side, secondary to AVM's high resistance shunt. She underwent successful coiling of the A2 ACA and A2-A3 ACA junction aneurysms. (Figure 2) It is a rare occurrence for multiple DACA aneurysms to coexist with an AVM.[1] Both neuroendovascular coiling and neurosurgical management options can be considered to treat DACA aneurysms.[2]

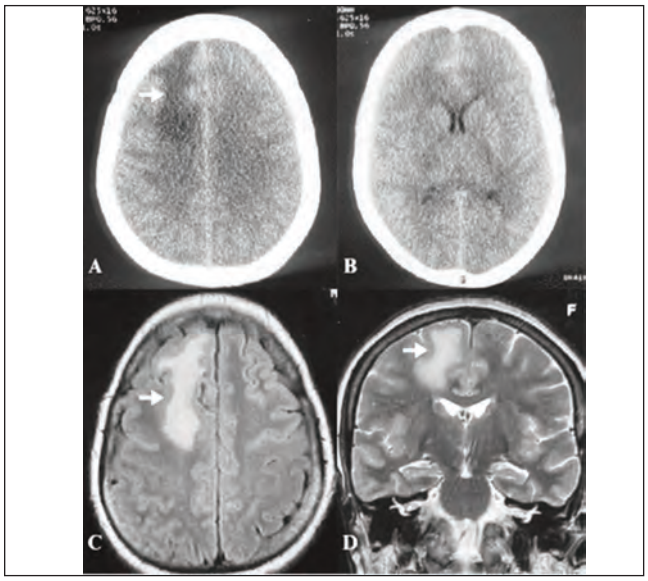

Figure-1: CT brain plain images (A and B) show subarachnoid haemorrhage from ruptured aneurysms and oedema in the right frontal lobe. MRI T2 Flair (C) and T2 (D) shows altered intensity lesion along right frontal parafalcine region with significant perilesional vasogenic oedema (white arrows).

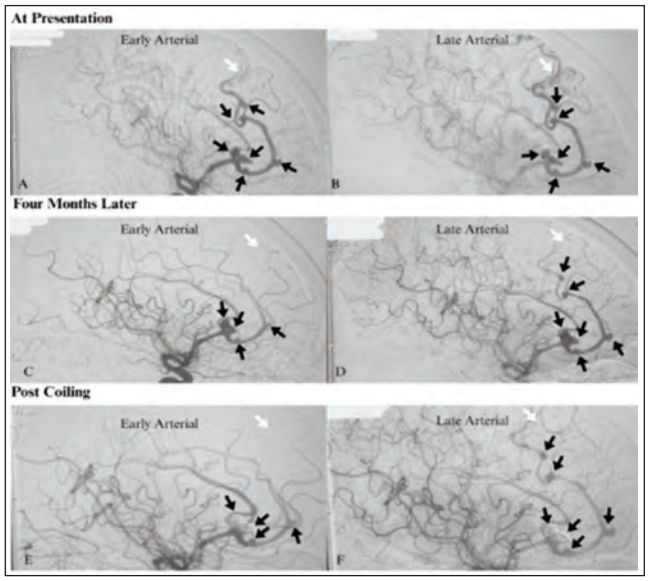

Figure-2: Lateral view Digital Subtraction Angiography images showing multiple aneurysms along right ACA at presentation (A and B), at four months (C and D), and after coiling (E and F) *Black arrow indicates aneurysms, white arrows indicate arteriovenous malformation.*

References

1. Hani U, Bari ME, Bukhari SS. Arteriovenous malformation with associated multiple flow-related distal anterior cerebral artery aneurysms: A case report with poor outcomes. Surg Neurol Int. 2020;11:232.
2. Furtado SV, Jayakumar D, Perikal PJ, Mohan D. Contemporary Management of Distal Anterior Cerebral Artery Aneurysms: A Dual-Trained Neurosurgeon's Perspective. J Neurosci Rural Pract. 2021;12:711-717.