

Management of chronic exogenous rhinolith with gingivonasal fistula: A case report

Foppi Puspitasari, Fadjar Perkasa

Abstract

Recurrent rhinorrhoea that occurs chronically, needs to consider the possibility of a fistula in the nasal cavity, which has the potential to form a rhinolith. We report the case of a 39-year-old man with complaints of recurrent rhinorrhoea since four years ago, accompanied by thick secretions, symptoms of post-nasal drips, and olfactory disturbances. The patient had a history of removing the left upper molar (molar I), which causes a fistula in the tooth extraction site, making it more likely for food and drink to enter the left nasal cavity. Anterior rhinoscopy examination revealed a white mass in the left inferior meatus and a purulent odour discharge. In addition, there were gingival defects of the first molar teeth, multi-sinusitis, and nasal septum deviation. Rhinolith extraction was performed using functional endoscopic sinus surgery, submucosal resection, and repair of gingivo-nasal defects with rotational flaps. Follow-up for one week showed that the flap was in place and there were no complications.

Keywords: Exogenous, fistule, gingivonasal, rhinolith.

DOI: <https://doi.org/10.47391/JPMA.9784>

Introduction

Rhinolith is a type of foreign body (a hard object like a stone) that can be found in the nasal cavity. It usually has a core of foreign matter from outside the body, such as bacteria, pus, blood, mucous, or crust.^{1,2} Epidemiologically, based on various existing studies, cases of nasal foreign bodies range from 19–49% of all foreign body cases that occur in the ear, nose, and throat (ENT) outpatient clinic.³ It occurs more in women's nasal cavities than men's and can also occur in the nasopharynx, although rare. Rhinoliths found in the outpatient clinic can be either exogenous (blood clots, ectopic teeth, bone fragments) or endogenous (fruit seeds, plant materials, beads, cotton buds). According to a study, the most commonly found items were non-organic synthetic beads, followed by

Department of Otorhinolaryngology, Head and Neck Surgery, Hasanuddin University, Makassar, Indonesia.

Correspondence: Foppi Puspitasari. e-mail: foppipuspitasari@gmail.com

ORCID ID: 0009-0000-0543-3946

Submission complete: 15-06-2023

Review began: 28-07-2023

Acceptance: 06-03-2024

Review end: 28-07-2023

organic items such as vegetables. Some nasal foreign bodies are reported to have remained in the nasal cavity for months or even years without any symptoms.^{3,4}

The successful diagnosis and treatment of a nasal foreign body depends on a careful examination of the nasal cavity. Although nasal foreign bodies are rarely found in adults but remain a differential diagnosis until proven otherwise. Diagnosing nasal foreign bodies at the earliest stage is recommended so that immediate management can be carried out and complications can be prevented. A foreign body in the nasal cavity can be a big challenge and requires skill in its management.^{3,5} We report a foreign body in the nasal cavity of an adult male whose diagnosis was delayed by 4 years.

Case Report

A 39-year-old man presented at the ENT outpatient clinic of Wahidin Sudirohusodo Hospital Makassar Indonesia, complaining of recurrent rhinorrhea in the left nasal cavity, a condition he had been experiencing for the past four years. This was his initial examination for the complaint on November 25th 2020. The patient also reported thick nasal secretions and symptoms of post-nasal drips, along with olfactory disturbances. No nasal discharge mixed with blood, epistaxis, or obstruction was found. The patient had a history of tooth extraction of the left upper molar (molar I), leaving a cleft at the extraction site. To address this, the patient had been using gauze rolled up into the gap four years ago. The patient complained that food and drink would enter from the left nasal cavity.

On examination, the nose appeared symmetrical with no tenderness, mass, or crepitus in the nose or sinus area. On anterior rhinoscopy, normal mucosa was found, left nasal septum deviation, a white mass was seen in the left inferior meatus and a purulent odour discharge. No abnormalities were found during otoscopy and pharyngoscopy examination.

The results of routine blood tests were within normal limits. A head computer tomography (CT) scan showed chronic rhinitis, left medial concha bullous, sinusitis in the left frontal sinus, bilateral ethmoidal and maxillary sinuses, nasal septum deviation, and pedunculated bone density in the left nasal cavity (Figure 1). The patient was then

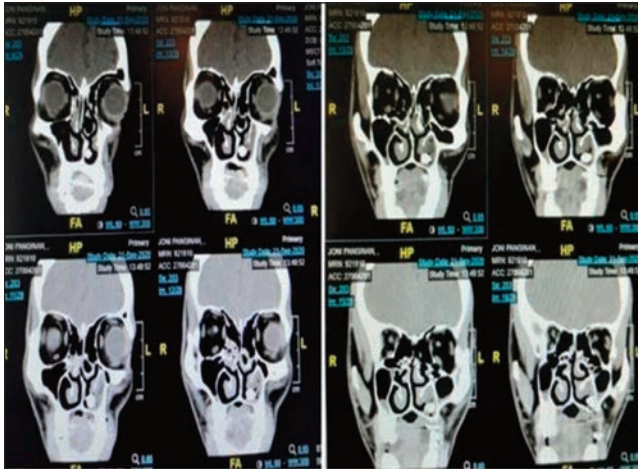


Figure-1: Head CT-Scan of Paranasal Sinuses in Coronal Section.

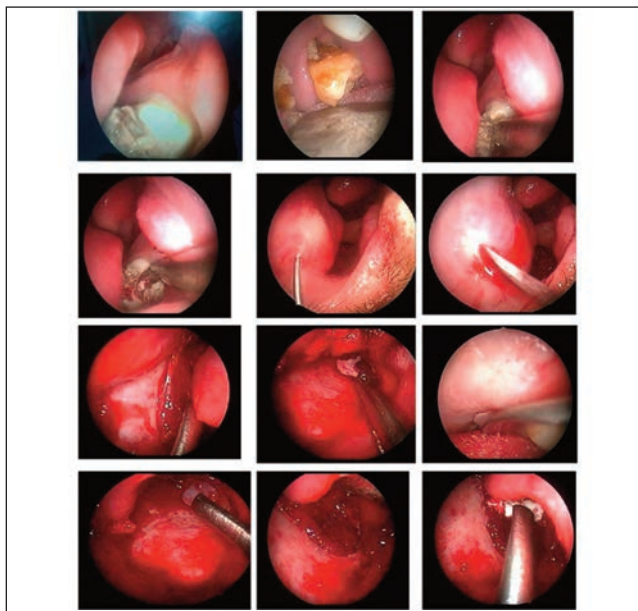


Figure-2: Procedure of Functional Endoscopic for Rhinolith Extraction, Submucosal Resection, and Gingivonasal Defect Repair with Flap Rotation.

diagnosed with rhinolith due to gauze and gingivonasal fistula.

Rhinolith extraction was performed through functional endoscopic sinus surgery, involving submucosal resection, and defect repair with rotation flaps. After placing the patient in a supine position and performing general anaesthesia, lidocaine: ephedrine 1:1 (1:100,000) tampons were placed into both nasal cavities. During functional endoscopy, a mass resembling a rhinolith was found in the left nasal cavity, so a rhinolith extraction was performed. It further clarified the presence of a gingivonasal defect. After the submucosal resection, the gingivonasal defect was closed by transposition and rotation of the left nasal septum mucosa flap, cartilage, and gel foam. Defect closure was performed on the gingiva of the first molars with bone

wax (Figure 2). The rhinolith was successfully extracted, and follow-up at six days post-surgery showed that the flap was in place. There was no bleeding or infection at the surgical wound.

Discussion

Nasal foreign bodies are usually benign and do not require urgent intervention; however, certain objects can cause severe damage and must be treated immediately. Rhinoliths can sometimes go unnoticed for weeks, months, or even years after insertion.⁶ As in this case, it was only diagnosed after four years of symptoms.

The pathogenesis of rhinoliths is unclear. Several factors are thought to be involved in the formation of rhinoliths, including entering foreign bodies into the nasal cavity and then compaction, acute or chronic inflammation, obstruction resulting from obstruction and stagnation of mucous, and deposition of mineral salts. Based on the material that causes rhinoliths, they are divided into exogenous and endogenous rhinoliths. In this case, a gauze rhinolith was obtained, which was an exogenous rhinolith.⁶ The development time for a foreign body to become a rhinolith still needs to be determined. In a case report by Maheshwari et al., the formation of rhinoliths could take up to 15 years.⁷

In a study by Seyhun et al., the most common symptom was nasal obstruction, followed by unilateral malodorous rhinorrhea. In rare cases, the patient may present with epistaxis, snoring, and sleep apnoea.⁸ Our patient complained of recurrent rhinorrhoea and food and drinks always coming out of the left nose. The foreign body tends to be located in one of two locations in the nasal fossa: the base of the inferior turbinate or anterior to the middle turbinate.⁶ A rhinolith was found in the left inferior meatus in our patient.

A diagnosis of rhinoliths can be made on clinical grounds. While anterior rhinoscopy may be sufficient, a fiberoptic nasopharyngoscope can also be employed.⁶ In our case, an anterior rhinoscopy examination revealed a deviated left nasal septum and a white mass in the left inferior meatus that had a purulent odour. However, in cases of inflammation around the rhinoliths, a differential diagnosis such as fungal sinusitis or neoplastic conditions such as ossifying fibroma or osteoma needs to be considered. However, this can be ruled out with imaging.⁸ On the other hand, the paranasal sinus CT scan can determine the location and size of the rhinolith and describe the complications caused by the rhinolith. The macroscopic appearance of rhinoliths can be a brown-black crust-covered mass in the inferior turbinate of the cavum nasal. Complications arising from rhinoliths can include sinusitis,

nasal deviation, oronasal fistula, and septal deviation.⁹ As in our case, we performed computed tomography of the paranasal sinuses, and the results revealed a foreign body in the inferior nasal meatus, with the complication seen in the form of sheathing of the sinuses that leads to sinusitis.

Rhinolith extraction is the only treatment for patients with rhinoliths, and the procedure can be performed under local or general anaesthesia. In our case, the rhinolith was removed using nasal forceps. Most rhinoliths can be drained through the anterior nares. Larger mass sizes need to be crushed first and removed as small pieces. A lateral rhinotomy is required if the mass is enormous, hard, and has an irregular surface.¹⁰

Rhinolith extraction was the primary treatment in the present case. Due to the presence of a gingivonasal defect, contributing to rhinolith formation, the gingivonasal defect was covered by transposition and rotation of the flap of the left nasal septum mucosa, cartilage, and gel foam. Our patient's first molar gingival defect was also filled with bone wax. Follow-up for one week showed that healing was good, the flap was in place, and there were no complications.

Conclusion

The successful diagnosis and treatment of a nasal foreign body depends on carefully examining the nasal cavity. The possibility of a fistula in the nasal cavity must be considered in chronic recurrent rhinorrhoea. In that case, rhinolith extraction was the primary treatment following covering the gingivonasal defect by transposition and rotation of the flap with excellence outcome and no complications in the one week.

Acknowledgement: The authors would like to thank Farhamna Academic for assisting in the preparation of this manuscript. Thanks to otorhinolaryngology-head and neck surgery department staff of the Hasanuddin University Medical Faculty who have assisted in providing treatment and monitoring variables. This research received no specific grant from any funding agency in the public, commercial, or not for profit sectors.

Consent: A formal informed and written consent was taken from the patient for publishing the case report. Identity would remain confidential.

Disclaimer: None.

Conflict of interest: None.

Funding disclosure: None.

References

1. Dewantara IPS, Ratnawati LM. Exogenous Rinolith: a case report. *Intisari Sains Medis*. 2020;11:1432–5.
2. Yip HM, Costello D, Hettige R. A calcified mass in the nose. *BMJ*. 2022 ;379:e068735. doi: 10.1136/bmj-2021-068735.
3. Kristianti A. Nasal corpus alienum (folded photo) in toddlers: early diagnosis and management. *J Pranata Biomed*. 2022; 2:11-23.
4. Çakabay T, Bezgín SÚ, Tarakçiođlu MC, Koçyđđıt M, Keskíneđe BS, Örtekin SG. Rhinolithiasis: Mineralogical, chemical composition, clinical and radiological features of rhinoliths. *Turk J Ear Nose Throat*. 2019; 29:52–3.
5. Dann L, Doody J, Howard R, Blackburn C, Russell J, Barrett M. Nasal foreign bodies in the paediatric emergency department. *Ir J Med Sci*. 2019; 188:1401–5. doi: 10.1007/s11845-019-02000-z.
6. Baranowski K, Al Aaraj MS, Sinha V. Nasal Foreign Body. [Online] [Cited 2023 August 11]. Available from: URL: <http://www.ncbi.nlm.nih.gov/books/NBK459279/>
7. Maheshwari N, Etikaala B, Syed AZ. Rhinolith: An incidental radiographic finding. *Imaging Sci Dent*. 2021; 51:333–6. doi: 10.5624/isd.20200126.
8. Seyhun N, Toprak E, Kaya KS, Dizdar SK, Turgut S. Rhinolithiasis, a rare entity: Analysis of 31 cases and literature review. *North Clin Istanbul*. 2021; 8:172–7. doi: 10.14744/nci.2020.32391.
9. Chacko SP, Shere DS, Shetty AK, Sheth RK, Patangrao HD. Giant Rhinolith in a Bizarre Form. *Int J Head Neck Surg*. 2022; 13:85–7. doi: 10.5005/jp-journals-10001-1533.
10. Çelik M, Olgun B, Altinitas A, Yegin Y, Kayhan FT. Evaluation of patients with nasal foreign body. *Haydarpasa Numune Med J*. 2018; 58:79–84. doi: 10.14744/hnhj.2018.35220.

Author Contribution:

FP, FP: Performed the examination and treatment procedure, writing, final approval.