

Comparison of the rate of complications in primary and secondary enucleation in patients with retinoblastoma

Rabeeah Zafar¹, Sumaira Altaf², Sorath Noorani³, Sidra Jabeen⁴, Shadab Hassan⁵

Abstract

Objective: To quantify pregnant women's knowledge of congenital abnormalities, their associated risk factors and preventative measures, and to determine the association of knowledge level with socio-demographic factors.

Method: The multi-centre, cross-sectional study was conducted from October 2023 to March 2024 in Quetta, Pakistan, after approval from the ethics review committee of the Quetta Institute of Medical Sciences, and comprised pregnant women aged at least 18 years who were attending antenatal clinics. Data was collected using a questionnaire. The participants' knowledge was assessed through 21 close-ended questions. The association of knowledge score with a range of socio-demographic factors was explored. Data was analysed using SPSS 26.

Results: Of the 640 mothers, 303(47.3%) were aged 25-34 years, 131(20.5%) had completed secondary school education, 540(84.4%) were housewives, 373(58.3%) were married within their families, and 447(69.8%) lived in urban areas. There were 349(54.5%) participants having moderate knowledge about birth defects, 207(32.3%) had high level of knowledge, and 84(13.1%) had poor knowledge. The knowledge level had significant association with education level ($p=0.001$) and residence area ($p=0.006$).

Conclusion: Pre-pregnancy counselling shall be made available at antenatal care centres. Maternal obesity and consanguinity shall be pointed out to pregnant women as risk factors for congenital anomalies.

Keywords: Congenital abnormalities, Pregnancy, Health knowledge, Attitudes, Practice, Risk factors, Antenatal care, Regression analysis. (JPMA 76: 704; 2026) DOI: <https://doi.org/10.47391/JPMA.23150>

Introduction

Retinoblastoma is the most common primary intraocular malignancy of developing retina.¹ It accounts for 2% of all childhood cancers affecting children usually up to 5 years of age, but late presentation has also been reported.^{2,3} The average incidence globally ranges between 1 in every 15,000-20,000 livebirths.⁴ The developing countries bear most of the retinoblastoma cases worldwide.⁵ According to 2013 population estimates, 43% global burden of retinoblastoma relates to 6 countries of the Asia-Pacific region, with Pakistan ranking at number 4 on the list.⁶ The annual crude incidence of retinoblastoma in Karachi has been reported to be 4.0/100,000 and 2.4/100,000 in children under the age of 5 and 10 years, respectively.⁷

Initially, enucleation was considered the sole life-saving treatment modality in retinoblastoma. Literature from as early as 2600BC exists, supporting evidence of enucleation being the oldest surgery in ophthalmology.⁸ Over the years, new diagnostic and treatment modalities have

^{1,2,5}Department of Paediatric Ophthalmology and Strabismus, Al-Shifa Trust Eye Hospital, Rawalpindi, Pakistan; ^{3,4}Department of Ophthalmology, Al-Shifa Trust Eye Hospital, Rawalpindi, Pakistan.

Correspondence: Rabeeah Zafar. e-mail: rabeeah.zafar11@yahoo.com

ORCID ID: 0000-0002-3610-3795

Submission completed: 06-02-2025 **1st Revision received:** 27-05-2025

Acceptance: 14-01-2026 **Last Revision received:** 13-01-2026

emerged in the management of retinoblastoma, with survival rate going up to 100% in developed countries owing to adequate resources and treatment facilities.⁹ A wide variety of globe-salvage techniques has been devised with fair success rate in recent times, thereby shifting the treatment goals from globe preservation to vision preservation.¹⁰ However, in other parts of the world, the current dilemma is late presentation, delayed diagnosis, treatment refusal, and an avid lack of awareness, all adding to the disease burden.^{4,6} This increases the chances of advanced retinoblastoma on diagnosis with usually no prospect of redeemable vision, thus limiting the treatment options, making enucleation inevitable in majority of such cases.⁶

In extensive retinoblastoma, like International Intraocular Retinoblastoma Classification (IIRC) groups D and E, globe is sacrificed considering the grave concerns for extraocular spread of tumour when there is no hope of salvageable sight in upfront enucleation. If the tumour is non-responsive to conservative local and systemic consolidative treatments, secondary enucleation is mandatory in order to preserve patient from metastatic disease and death.¹¹ Like every surgical procedure, enucleation also has some inherent potential to develop complications, which includes discharging socket, post-enucleation socket syndrome, implant-related issues, like

exposure, extrusion and migration into the orbit, to name a few.

The current study was planned to evaluate complications after primary and secondary enucleation in children with retinoblastoma.

Patients and Methods

The prospective cohort study was conducted from January 1, 2017, to December 31, 2022, at the Children Eye Hospital, Al-Shifa Trust, Rawalpindi, Pakistan. After approval from the institutional ethics review committee, the sample was raised using non-probability purposive sampling technique. The sample size was calculated using WHO calculator ($n = Z^2 \cdot p \cdot q / e^2$), taking $z = 1.96$, $p = 21\%$, $q = 79\%$ and $e = 7\%$.^{12,13}

Written Informed consent was obtained from the parents of all the patients. Those included were paediatric patients of all age groups irrespective of gender who underwent enucleation with orbital implant for group E retinoblastoma. In case of bilateral enucleation, only one of the two eyes was included. Only those patients were included who had a minimum follow-up duration of one year post-enucleation. The follow-up duration was based on literature indicating that most complications occur within the first 12 months post-enucleation.¹⁴

Patients were excluded in case of incomplete data or loss to follow-up. Also excluded were patients having enucleation done in other settings, and those having post-enucleation irradiated sockets.

All the patients were examined with indirect ophthalmoscope and a paediatric ocular imaging system (RetCam 3, Natus Medical Inc., Pleasanton, CA, United States) prior to surgery in order to confirm the eye to be enucleated. Enucleation was done under aseptic measures by experienced surgeons for better outcomes. A 360° limbal peritomy was done. Tenon's layer was dissected away from sclera and muscles, leaving as much conjunctiva and tenon as possible. All recti were isolated with muscle hooks and secured with 6-0 Vicryl® suture (Ethicon Inc., Somerville, NJ, USA) just behind their insertion except for medial rectus, which was sutured 4mm from its insertion point. They were later transected and retracted with bulldog forceps to avoid damage to the muscles. A longer 4mm stump of medial rectus was left behind to be grabbed by artery forceps to aid in axial pulling of the globe during nerve transection. Obliques were transected to be retracted into the orbit. A long-tipped scissor was introduced medially in orbit with the aim of resecting a longer length of optic nerve (>10mm). While stringing the optic nerve to reach near the optic canal, the tip of the

scissor was used to cut the optic nerve while simultaneously pulling the globe up with the other hand. Soft tissue attachments were released once the globe was prolapsed from the socket after transecting the optic nerve. Haemostasis was maintained by applying digital pressure against the bone of posterior socket for several minutes. A polymethyl methacrylate (PMMA) orbital implant (Saifee LAB® pvt. Ltd., Lahore, Pakistan) of size appropriate for the individual socket was wrapped in single layer of polypropylene meshwork (Surgical Mesh®, Ethicon Inc., Somerville, NJ, USA) and placed in posterior sub-tenon space. Recti were sutured with the meshwork on the anterior surface of the implant. Tenon layer was closed over the implant with interrupted sutures using 5-0 ETHIBOND EXCEL® (Ethicon Inc., Somerville, NJ, USA). Conjunctiva was closed with continuous sutures. The length of the resected optic nerve was measured and the enucleated globe was sent for histopathological analysis by placing it in formalin solution and after proper labelling of the sample.

All the patients were scheduled as per departmental guidelines for the follow-up of enucleated patients. They were assessed for condition of the socket on the first post-operative (post-op) week, and then on second and fourth week, followed by monthly evaluations depending upon the status of the retinoblastoma and chemotherapy schedule. Patient data was recorded in the hospital's computerised medical record system on every visit for future correlation.

Data was analysed using SPSS 26. Mean ± standard deviations were calculated for continuous variables. Frequencies and percentages were calculated for categorical data. Comparisons between categorical variables were made using post-stratification chi-square test. $P \leq 0.05$ was considered statistically significant. Odds ratios (ORs) with 95% confidence interval (CI) were calculated for risk factors associated with complications using univariate logistic regression analysis.

Results

Of the 172 patients with histopathologically confirmed retinoblastoma who underwent enucleation during the study period, 39(23%) were excluded for not meeting the inclusion criteria. Of the remaining 133(77%) patients with mean age 28.1 ± 19.1 months, 77(58%) were boys and 56(42%) were girls. Overall, 74(56%) patients had primary enucleation, 59(44%) had secondary enucleation, 79(59%) had unilateral disease and 54(41%) had bilateral retinoblastoma. Family history was positive in 23(17%) patients.

Mean age at presentation in primary enucleation cases was 28.9 ± 18.15 months and it was 26.96 ± 20.51 months in

secondary cases. Difference between age at presentation between primary and secondary enucleation cases was statistically not significant ($p=0.535$). Overall mean age at enucleation was 30.89 ± 19.14 months; 29.74 ± 18.07 months in primary and 32.90 ± 20.66 months at secondary enucleation ($p=0.784$).

Most common presentation was leucocoria in 72(54%) patients, followed by buphthalmos and proptosis 19(14%)

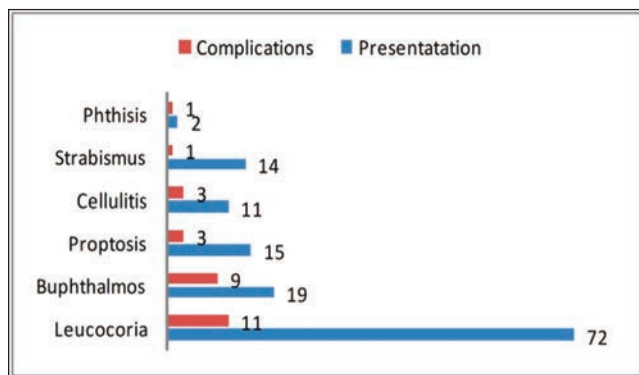


Figure: Distribution of complications (n=28) with respect to the mode of presentation (n=133).

Table-1: Types of complications in primary and secondary enucleation in comparison to systemic chemotherapy.

Complications	n (%)	Type of Enucleation n (%)		p-value	Systemic Chemotherapy n (%)		p-value
		Primary	Secondary		Yes	No	
Conjunctival Prolapse	5 (3.8)	02 (40)	03 (60)	0.473	04 (80)	01 (20)	0.505
Implant Exposure	9 (6.8)	05 (55.5)	04 (44.4)	0.996	06 (66.6)	03 (33)	0.974
Implant Extrusion	2 (1.5)	01 (50)	01 (50)	0.872	02 (100)	0	0.308
Discharging Socket	5 (3.8)	02 (40)	03 (60)	0.473	04 (80)	01 (20)	0.505
Pre-septal Cellulitis	4 (3)	02 (50)	02 (50)	0.818	03 (75)	01 (25)	0.705
Recurrence	3 (2.3)	03 (100)	0	0.118	03 (100)	0	0.210

$p \leq 0.05$ calculated using Pearson's chi-square test.

Table-2: Distribution of complications with respect to patients' demographic data.

Variables	Total n (%)	Type of Enucleation n (%)		Analysis		Complications n (%)		Analysis		
		Primary	Secondary	p-value	OR	Yes	No	p-value	OR	
Gender	Male	77 (58)	74 (55.6)	59 (44.4)	0.955	1.008 (0.753-1.350)	28 (21.05)	105 (78.9)	0.025	0.625 (0.385-1.013)
		56 (42)	31 (55.3)	25 (44.6)			17 (30.3)	39 (69.6)		
Laterality	Unilateral	79 (59)	51 (64.5)	28 (35.4)	0.012	1.45 (1.066-1.978)	15 (18.9)	64 (81)	0.480	0.879 (0.603-1.282)
		54 (41)	23 (42.5)	31 (57.4)			13 (24)	41 (75.9)		
Enucleated Eye	Right eye	71 (53.38)	38 (53.5)	33 (46.4)	0.599	0.918 (0.669-1.261)	20 (28.1)	51 (71.8)	0.031	1.471 (1.083-1.997)
		62 (46.6)	36 (58.0)	26 (41.9)			81 (12.9)	54 (87.1)		
Family History	Yes	42 (31.6)	21 (50)	21 (50)	0.374	0.797 (0.484-1.313)	07 (16.6)	35 (83.3)	0.399	0.750 (0.374-1.505)
		91 (68.4)	53 (58.2)	38 (41.7)			21 (23.1)	70 (76.9)		
Systemic Chemotherapy	Yes	88 (66.2)	29 (33)	59 (67)	<0.001	0.392 (0.295-0.521)	22 (25)	66 (75)	0.118	1.250 (0.980-1.594)
		45 (33.8)	45 (100%)	0			06 (13.3)	39 (86.6)		
Extraocular Disease at Presentation	Yes	59 (44.4)	02 (3.3%)	57 (96.6)	<0.001	0.028 (0.007-0.110)	14 (23.7)	45 (76.2)	0.499	1.167 (0.759-1.796)
		74 (55.6)	72 (97.3%)	02 (2.7)			14 (18.9)	60 (81)		
HRF on Histopathology	Yes	51 (38.3)	28 (54.9%)	23 (45.1)	0.893	0.971 (0.630-1.496)	16 (31.3)	35 (68.6)	0.021	1.714 (1.127-2.608)
		82 (61.6)	46 (56.1)	36 (43.9)			12 (14.6)	70 (85.3)		
Complications	Yes	28 (21.05)	15 (53.5)	13 (46.4)	0.804	0.920 (0.476-1.779)	15 (20.2)	59 (79.7)	0.804	0.953 (0.649-1.400)
		105 (78.9)	59 (56.1)	46 (43.8)			13 (22)	46 (78.0)		
Enucleation Type	Primary	74 (55.6)	74 (55.6)	74 (55.6)			15 (20.2)	59 (79.7)		
		59 (44.4)	59 (44.4)	59 (44.4)			13 (22)	46 (78.0)		

p value calculated using Pearson's chi-square test; 95% confidence interval (CI) calculated from odds ratio (OR) using Pearson's chi-square test; HRF: High-risk features.

and 15(11%), respectively. Complications were observed in 28(21.1%) patients, and, among them, 11(39%) were in cases with leucocoria and 9(25%) with buphthalmos (Figure).

Extraocular extension of retinoblastoma was found in 59(44%) patients on initial magnetic resonance imaging (MRI) scan. Out of these, 57(96%) patients underwent secondary enucleation after receiving systemic chemotherapy. Histopathology revealed that high-risk features (HRFs) were present in 51(38%) eyes. Among these, 28(55%) had primary enucleation, with 1(3.6%) enucleated globe showing resected margin of the optic nerve involved. The remaining 23(45%) patients underwent secondary enucleation. Intravenous chemotherapy was received by 88(66%) patients. Among these, 59(67%) patients underwent secondary enucleation. In 29(33%) patients with primary enucleation, chemotherapy was initiated in order to control the spread of the disease due to presence of HRFs on histopathology.

Of the 28(21.1%) complications, the most common was implant exposure 9(32.14%) | 5(55.6%) primary and 4(44.4%) secondary cases. This was followed by conjunctival prolapse and discharging socket 5(3.8%) each (Table 1). Mean age at complication was 36.6 ± 20.89 months. In 17(61%) cases with complications, enucleation was performed at age <30 months. Complications were observed in 15(54%) patients in primary, and 13(46%) in secondary cases with a ratio of 1.2:1 ($p=0.804$). The difference in

terms of mean age at complication was statistically not significant ($p=0.477$) between primary and secondary cases. The median follow-up period was 12 months (interquartile range [IQR]: 6-12 months), while mean duration was 10.4 ± 3.2 months (range: 1-12 months). Complications in 18(64%) of the cases were observed in the initial 6 months of enucleation, while 10(36%) cases developed complications 6-12 months post-enucleation (Table 1)

Univariate logistic regression analysis showed that female gender (OR: 1.6, 95% CI: 1.109-2.410, $p=0.02$), bilateral retinoblastoma (OR: 1.2, 95% CI: 0.748-1.891, $p=0.48$), intravenous chemotherapy (OR: 1.2, 95% CI: 0.980-1.594, $p=0.11$), HRFs on histopathology (OR: 1.7, 95% CI: 1.127-2.608, $p=0.02$), and extraocular disease at presentation (OR: 1.1, 95% CI: 0.759-1.796, $p=0.49$) were associated with greater odds of developing complications after enucleation (Table 2).

Regarding geographical demographics, 54(40.6%) of the patients belonged to Punjab, 61(45.9%) to Khyber Pakhtunkhwa (KP), 2(1.5%) to Balochistan, 3(2.3%) to Sindh, 6(4.5%) to Azad Jammu and Kashmir (AJK), and 4(3%) to Gilgit-Baltistan (GB), while 3(2.3%) were foreigners. However, 14(25.6%) patients from Punjab, 10(16.4%) from KP, 1(50%) from Balochistan, 2(33.3%) from AJK, and 1(25%) from GB presented after developing complications.

Discussion

Various local studies have mentioned the presentation patterns, outcomes of various treatment modalities, and histopathology data regarding retinoblastoma.¹⁵ In the current study, 28(21.5%) eyes developed complications compared to 18%¹², 7.8%,¹⁶ 13.2%¹⁷ and 18%¹⁸ reported earlier from other regions.

The current study showed that implant exposure was the most commonly encountered complication in 32% eyes. Ye et al. and Lang et al. observed an even greater proportion of implant exposure in their respective studies (70% and 63%, respectively).^{17,18}

The current study reported increased odds of complications in patients who received chemotherapy during the course of the disease, which was similar to earlier observations.^{17,18} Mouritset al. also observed increased incidence of implant-related complications in sockets with additional treatment, like chemotherapy and radiotherapy, due to orbital volume deficiency in irradiated sockets (17% vs 8% without additional treatment).¹⁶ The current study did not evaluate irradiated eyes due to inherent bias of radiotherapy that causes complications in enucleated sockets. Unfortunately, no local data is available

till date to compare the statistics of complications arising after enucleation in Pakistani population.

A wide range of implant materials are available worldwide.¹⁹ Mourits et al. and Lang et al. compared different types of implant materials and sizes for possible complications in post-enucleated sockets, with implant exposure being the most prevalent complication.^{16,18} Mourits et al. observed less exposures or extrusions in acrylic (4.9%) vs hydroxyapatite group (12.7%).¹⁶ Yang et al. proposed favourable outcomes with polypropylene and larger implants.²⁰ In the current study, only PMMA implants were inserted with size matching individual orbital volume without taking the size of implant into account for possible complications, marking it a limitation of the study. Another limitation of this study is the small follow-up time of one year, which was similar to Verhoekx et al.¹⁴ but Yang et al. had 10 years of follow-up for exposure of implant.²⁰

The current study reported more complications when enucleation was carried out at an early age and in female patients, which was similar to the observation reported by Lang et al.¹⁸ This perhaps can be explained on the basis of variations in orbital anthropometric values with respect to gender and age.²¹

The current study had comparable presentation pattern of retinoblastoma to other foreign and local studies.^{22,23} The most prevalent presentation was leucocoria in 72(54%) eyes, and 11 out of 28 eyes developing complications were those that presented with leucocoria (39%).

In the current study, extraocular retinoblastoma was present in 44% eyes on initial MRI, which is in complete agreement with Zia et al. (43.5%).²⁴ An unfortunate but pertinent observation is that most of the studies done so far on retinoblastoma in Pakistan had higher proportion of patients with advanced disease on presentation.^{15,24,25}

The current study reported HRF in 51(38.3%) eyes on histopathology compared to 43(60%) eyes reported by Yaqoob et al.²⁵ Both the studies observed choroidal invasion as the most common feature (36% and 55%, respectively). Only one eye had optic nerve resected margin involved in both the studies. No local study has addressed the outcomes of enucleated sockets with HRFs on histopathology so far, which is an important risk factor that leads to complications after enucleation (OR: 1.7, $p=0.02$). No mortality was observed during the follow-up period.

The current study has limitations as it was conducted at a single tertiary care eye centre using non-probability purposive sampling technique with limited generalisability of the findings. Moreover, only univariate logistic regression

was performed, while multivariate logistic regression was not applied, which limited the ability to control for confounding variables, such as demographic or clinical characteristics.

Large-scale, multi-centre clinical trials with a long-duration follow-up and Kaplan-Meier survival analysis are recommended to compare the outcomes of enucleated eyes in retinoblastoma patients in Pakistani population.

Conclusion

Complications were found in more than one-fifth of the retinoblastoma patients studied. Systemic chemotherapy, younger age at enucleation, female gender, HRFs on histopathology, and advanced disease at presentation played a vital role, and need serious consideration in this regard.

Disclaimer: None.

Conflict of Interest: None.

Source of Funding: None.

References

- Rojanaporn D, Attaseth T, Dieosuthichat W, Leelawongs K, Pakakasama S, Anurathapan U, et al. Clinical Presentations and Outcomes of Retinoblastoma Patients in relation to the Advent of New Multimodal Treatments: A 12-Year Report from Single Tertiary Referral Institute in Thailand. *J Ophthalmol* 2020;2020:e4231841. doi: 10.1155/2020/4231841.
- Siegel RL, Miller KD, Fuchs HE, Jemal A. Cancer statistics, 2022. *Ca Cancer J Clin* 2022;72:7-33. Doi: 10.3322/caac.21708.
- Meel R, Kashyap S, Bakhshi S, Singh Bajaj M, Wadhvani M. Retinoblastoma in Children Older than 6 Years of Age. *Ocul Oncol Pathol* 2020;6:395-404. doi: 10.1159/000509040.
- Abdallah E, Abdullahi SU, Abdulqader RA, Adamou Boubacar S, Ademola-Popoola DS, Adio A, et al. Global Retinoblastoma Presentation and Analysis by National Income Level. *JAMA Oncol* 2020;6:685-95. doi: 10.1001/jamaoncol.2019.6716.
- Bhakta N, Force LM, Allemanni C, Atun R, Bray F, Coleman MP, et al. Childhood cancer burden: a review of global estimates. *Lancet Oncol* 2019;20:e42-53. doi: 10.1016/S1470-2045(18)30761-7.
- Jain M, Rojanaporn D, Chawla B, Sundar G, Gopal L, Khetan V. Retinoblastoma in Asia. *Eye (Lond)* 2019;33:87-96. doi: 10.1038/s41433-018-0244-7.
- Adhi MI, Kashif S, Muhammed K, Siyal N. Clinical pattern of Retinoblastoma in Pakistani population: Review of 403 eyes in 295 patients. *J Pak Med Assoc* 2018;68:376-80.
- Moshfeghi DM, Moshfeghi AA, Finger PT. Enucleation. *Surv Ophthalmol* 2000;44:277-301. doi: 10.1016/s0039-6257(99)00112-5.
- Tomar AS, Finger PT, Gallie B, Mallipatna A, Kivelä TT, Zhang C, et al. A Multicenter, International Collaborative Study for American Joint Committee on Cancer Staging of Retinoblastoma: Part I: Metastasis-Associated Mortality. *Ophthalmology* 2020;127:1719-32. doi: 10.1016/j.ophtha.2020.05.050.
- Ueda T, Koga Y, Yoshikawa H, Tanabe M, Yamana K, Oba U, et al. Survival and ocular preservation in a long-term cohort of Japanese patients with retinoblastoma. *BMC Pediatr* 2020;20:37. doi: 10.1186/s12887-020-1923-7.
- Zhao J, Feng ZX, Wei M, Liu G, Solarte CE, Li B, et al. Impact of Systemic Chemotherapy and Delayed Enucleation on Survival of Children with Advanced Intraocular Retinoblastoma. *Ophthalmol Retina* 2020;4:630-9. doi: 10.1016/j.oret.2020.02.015.
- Lee V, Subak-Sharpe I, Hungerford JL, Davies NP, Logani S. Exposure of primary orbital implants in postenucleation retinoblastoma patients. *Ophthalmology* 2000;107:940-5. doi: 10.1016/s0161-6420(00)00016-6.
- Lwanga SK, Lemeshow S. Sample size determination in health studies: a practical manual. Geneva, Switzerland: World Health Organization; 1991. [Online] 1991 [Cited 2026 January 30]. Available from URL: <https://apps.who.int/iris/handle/10665/40062>
- Verhoekx JSN, Tse WHW, Rengifo Coolman A, van Kinderen YB, Wubbels RJ, Paridaens D. Complications Following Enucleations and Subsequent Oculoplastic Surgeries. *Ophthalmic Plast Reconstr Surg* 2018;34:320-3. doi: 10.1097/IOP.0000000000000966.
- Shaheen N, Inayat N, Bashir S, Sheikh UN, Bakar MA, Rehman P. Survival outcomes of unilateral retinoblastoma based on pathological risk stratification-experience at a tertiary care centre in Pakistan. *Ecancermedalscience* 2022;16:1360. doi: 10.3332/ecancer.2022.1360.
- Mourits DL, Moll AC, Bosscha MI, Tan HS, Hartong DT. Orbital implants in retinoblastoma patients: 23 years of experience and a review of the literature. *Acta Ophthalmol* 2016;94:165-74. doi: 10.1111/aos.12915.
- Ye H, Chen R, Xiao W, Lian X, Yang H. Polyester 5-0 suture for porous implant placement after retinoblastoma enucleation: analysis of 120 sockets. *BMC Ophthalmol* 2023;23:30. doi: 10.1186/s12886-023-02787-7.
- Lang P, Kim JW, McGovern K, Reid MW, Subramanian K, Murphree AL, et al. Porous orbital implant after enucleation in retinoblastoma patients: indications and complications. *Orbit* 2018;37:438-43. doi: 10.1080/01676830.2018.1440605.
- Chen XY, Yang X, Fan XL. The Evolution of Orbital Implants and Current Breakthroughs in Material Design, Selection, Characterization, and Clinical Use. *Front Bioeng Biotechnol* 2022;9:e800998. doi: 10.3389/fbioe.2021.800998.
- Yang MK, Lee MJ, Kim N, Choung H, Khwarg SI. Outcomes of enucleation and porous polyethylene orbital implant insertion in patients with paediatric retinoblastoma: a long-term follow-up study. *Br J Ophthalmol* 2022;106:502-9. doi: 10.1136/bjophthalmol-2020-317934.
- Malik TG, Moin M, Afzal MA, Akhtar FK, Alam R. Orbital and periorbital anthropometric variations and effect of age and gender on these variables. *Ophthalmol J* 2022;7:61-4. DOI: 10.5603/OJ.2022.0009.
- Tan RJ, Umerez DC, Alindayu JI, Conjares JM, Go DA, Paulino RG. Retinoblastoma in South Asia: A scoping review. *Asian Pac J Cancer Care* 2021;6:493-500. DOI:10.31557/APJCC.2021.6.4.493.
- Moez Uddin M, Farooque U, Aziz MZ, Yasmin F, Qureshi F, Saeed Y, et al. Different Types of Clinical Presentations and Stages of Retinoblastoma Among Children. *Cureus* 2020;12:e10672. doi: 10.7759/cureus.10672.
- Zia N, Hamid A, Iftikhar S, Qadri MH, Jangda A, Khan MR. Retinoblastoma Presentation and Survival: A four-year analysis from a tertiary care hospital. *Pak J Med Sci* 2020;36:S61-6. doi: 10.12669/pjms.36.ICON-Suppl.1720.
- Yaqoob N, Mansoor S, Aftab K, Kaleem B, Hamid A, Jamal S. High risk histopathological factors in retinoblastoma in upfront enucleated eyes: An experience from a tertiary care centre of Pakistan. *Pak J Med Sci* 2022;38:369-74. doi: 10.12669/pjms.38.ICON-2022.5787.

Author Contribution:

RZ: Concept, data collection, analysis, writing and final approval.

SA: Concept, overall supervision and final approval.

SN: Concept, writing and final approval.

SJ & SH: Drafting, reviewing and final approval.