

## Cavernous Malformations of the Brain: Natural History and Surgical Outcomes

Noman Ahmed<sup>1</sup>, Zanib Javed<sup>2</sup>, Muhammad Shahzad Shamim<sup>3</sup>

### Abstract

Cerebral cavernous malformations (CCM) are rare, benign vascular anomalies of the central nervous system with a prevalence of 0.5–0.8%. While often discovered incidentally, they may present with seizures, headaches, focal neurological deficits, or intracranial haemorrhage. Sporadic cases typically involve solitary lesions, whereas familial forms are associated with multiple lesions and genetic mutations such as PDCD10. Supratentorial locations predominate, but brainstem, cerebellar, and spinal involvement are also observed.

Management depends on symptomatology and lesion site. Asymptomatic cases are generally observed with serial imaging, while symptomatic lesions may require intervention. Microsurgical resection remains the treatment of choice for patients with medically refractory seizures or recurrent haemorrhage, offering favourable long-term outcomes and high seizure control rates. Radiosurgery may be considered for deep or eloquent lesions where open surgery carries a higher risk, though its benefits are delayed. An individualized approach is essential to optimize neurological and functional outcomes in CCM.

**Keywords:** Cavernoma, Cavernous malformation, Seizure, ICH, Microsurgery, Radiosurgery

**DOI:** <https://doi.org/10.47391/JPMA.25-95>

### Introduction

Cavernomas or cerebral cavernous malformations (CCM) are rare benign vascular malformations of the central nervous system, with an overall prevalence of 0.5 to 0.8 percent.<sup>1</sup> A thin layer of endothelium lines these abnormal channels without an intervening neural tissue, and blood flows at a slow velocity, resulting in thrombosis and the formation of clots of variable ages.<sup>1,2</sup> CCM accounts for 5 to 10 percent of all intracranial vascular anomalies, with around 40 percent of the tumours being diagnosed incidentally.<sup>3</sup> Individuals diagnosed with this anomaly

<sup>1</sup>Resident Neurosurgery, Aga Khan University Hospital, Karachi; <sup>2</sup>Chief Resident, Neurosurgery, Aga Khan University Hospital, Karachi; M Shahzad Shamim: <sup>3</sup>Professor of Neurosurgery, Aga Khan University Hospital, Karachi.

**Correspondence:** Muhammad Shahzad Shamim.

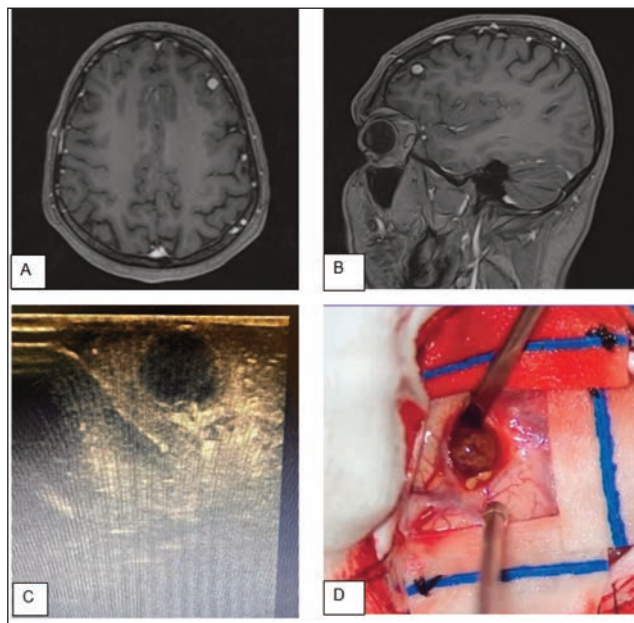
e-mail: [shahzad.shamim@aku.edu](mailto:shahzad.shamim@aku.edu)

ORCID ID: 0000-0001-8305-8854

remain asymptomatic mostly; however, 2 to 6 percent of the patients may present with an episode of bleeding at the time of initial presentation.<sup>4</sup> Additionally, patients may also present with other clinical features such as seizures or focal neurological deficits. According to one study, seizure was the most common presentation, accounting for 44.8 percent of the cases, followed by other symptoms like recurrent headaches (41.3%), focal deficits (13.7%), and other non-specific symptoms (6.8%).<sup>5</sup>

### Review of Evidence

Cavernous malformations can be sporadic or may present with a family history. Mostly, sporadic cases present as a single lesion, while there are multiple lesions in the familial cases. (Figure) It has been postulated that the mutations within the CCM3 interval and PDCD10 play a vital role in the development of familial cases of cavernous malformation.<sup>6</sup> CCM are commonly seen in the supratentorial compartment (92%). The common locations include the cerebral cortex in different cerebral lobes,



**Figure:** A and B: Preoperative MR brain with contrast images axial and sagittal sections showing a homogeneous enhancing lesion. C: Intraoperative ultrasound images of the same patient showing a hypoechoic well-circumscribed lesion near the surface. D: Intraoperative photograph of the lesion during resection showing a brownish firm spherical lesion. The lesion was confirmed as a cavernous malformation on histopathology.

followed by deep locations involving the basal ganglia, thalamus, or the intraventricular region. Amongst the infratentorial compartment (15%), the brainstem and the cerebellum are the sites of involvement, followed by the spinal cord (5%).<sup>7</sup> Brainstem CCM carry the highest morbidity and often present with haemorrhage.

According to a decision analysis by Rinkel et al., the 5-years outcome were similar for brainstem and non-brainstem cavernous malformation presenting with either intracerebral haemorrhage (ICH) or focal neurological deficits (FND). On the other hand, outcomes were better for individuals who underwent an intervention after presenting with seizures.<sup>8</sup> Additionally, this study concluded that neurosurgical excision had the best outcomes compared to conservative management or SRS for patients with ICH or FND.

Seizures, secondary to cavernous malformation, are linked to the presence of a hemosiderin ring around the lesion, which acts as an epileptogenic focus.<sup>9</sup> The location of the lesion does not correlate with the onset of seizure although the presence of seizures is more likely related to the presence of multiple CCM.<sup>11</sup> The study also reports the link between the development of epilepsy and CCM, with an approximate risk of 94% over 5 years. Patients with medically refractory seizures have significant benefit following surgical excision of CCM.<sup>12</sup> Lesionectomy can result in complete remission of seizures in 70-90 percent of the patients with sporadic seizures, or those lasting for less than a year.<sup>12</sup> It is important to note that with prolonged seizure duration, there is a decline in seizure control rate, advising earlier surgery in patients who fail to have seizure control with a single anti-epileptic drug.<sup>13</sup>

There are different treatment options available. This can range from a pure lesionectomy, involving resection of the lesion only; or it can be an extended lesionectomy with resection of the lesion along with the hemosiderin-laden parenchyma.<sup>14,15</sup> Some authors have also suggested the use of invasive EEG monitoring with lesionectomy followed by extended resections if the patient fails to respond. The use of electrocorticography has also been suggested for temporal lobe cavernous malformations, as it has been reported to improve overall outcomes by 72 to 100 percent.<sup>16</sup>

Stereotactic radiosurgery (SRS) is another treatment option available in certain cases of CCM. Evidence suggests that symptomatic CCM located in deep eloquent areas of the brain, where microsurgery is technically challenging, should be considered for SRS.<sup>17,18</sup> However, it takes at least 2 years to provide some beneficial outcome.<sup>19,20</sup>

Long-term results following an intervention are favourable, particularly for non-brainstem cavernous malformation. According to one study, neurological outcomes were better or the same after a follow-up period of 43 months in 100% and 75% of non-brainstem and brainstem CCM, respectively. Additionally, the post-operative long-term morbidity was 25% for brainstem and 0% for non-brainstem malformations.<sup>21</sup>

## Conclusion

Cavernous malformations are benign vascular anomalies that can remain clinically silent or present with seizures, haemorrhage, and focal neurological deficits. While asymptomatic lesions are best managed conservatively with close follow-up, symptomatic cases often require intervention. Current evidence favours microsurgical resection, particularly in patients with medically refractory seizures or recurrent haemorrhage. Radiosurgery remains an important alternative for lesions in eloquent or surgically inaccessible regions although its benefits are delayed.

## References

1. Acciarri N, Galassi E, Giulioni M, Pozzati E, Grasso V, Palandri G, et al. Cavernous malformations of the central nervous system in the pediatric age group. *Paed Neurosurg.* 2009;45:81-104.
2. Bilginer B, Narin F, Hanalioglu S, Oguz KK, Soylemezoglu F, Akalan NJCsNS. Cavernous malformations of the central nervous system (CNS) in children: clinico-radiological features and management outcomes of 36 cases. *Child's Nervous System.* 2014;30:1355-66.
3. Chen B, Lahl K, Saban D, Lenkeit A, Rauschenbach L, Santos AN, et al. Effects of medication intake on the risk of hemorrhage in patients with sporadic cerebral cavernous malformations. *Front Neurol.* 2023;13:1010170.
4. Gross BA, Du RJJ. Hemorrhage from cerebral cavernous malformations: a systematic pooled analysis. *J Neurosurg.* 2017;126(4):1079-87.
5. Aslan A, Börcek AÖ, Demirci H, Erdem MB. Cerebral cavernous malformation presenting in childhood: a single-centered surgical experience of 29 cases. *Clin Neurol Neurosurg.* 2020;194:105830.
6. Bergametti F, Denier C, Labauge P, Arnoult M, Boetto S, Clanet M, et al. Mutations within the Programmed Cell Death 10 Gene Cause Cerebral Cavernous Malformations. *Am. J. Hum. Genet.* 2005;76:42-51.
7. Rivera PP, Willinsky Ra Fau - Porter PJ, Porter PJ. Intracranial cavernous malformations. *Neuroimaging Clinics of North America*, 2003;13:27-40  
[https://doi.org/10.1016/s1052-5149\(02\)00060-6](https://doi.org/10.1016/s1052-5149(02)00060-6)
8. Rinkel LA, Salman RA-S, Rinkel GJ, Greving JP. Radiosurgical, neurosurgical, or no intervention for cerebral cavernous malformations: A decision analysis. *Int J Stroke.* 2019;14:939-45.
9. Awad I, Jabbour P. Cerebral cavernous malformations and epilepsy. *Neurosurgical focus.* 2006;21:e7.
10. Josephson CB, Leach JP, Duncan R, Roberts RC, Counsell CE, Al-Shahi Salman R. Seizure risk from cavernous or arteriovenous malformations: prospective population-based study. *Neurology.* 2011;76:1548-54.
11. von der Brölie C, von Lehe M, Raabe A, Niehusmann P, Urbach H, Mayer C, et al. Surgical resection can be successful in a large fraction of patients with drug-resistant epilepsy associated with multiple

- cerebral cavernous malformations. *Neurosurgery*. 2014;74:147-53; discussion 53.
12. Ferroli P, Casazza M, Marras C, Mendola C, Franzini A, Broggi G. Cerebral cavernomas and seizures: a retrospective study on 163 patients who underwent pure lesionectomy. *Neurol Sci*. 2006;26:390-4.
  13. Rosenow F, Alonso-Vanegas MA, Baumgartner C, Blümcke I, Carreño M, Gizewski ER, et al. Cavernoma-related epilepsy: review and recommendations for management--report of the Surgical Task Force of the ILAE Commission on Therapeutic Strategies. *Epilepsia*. 2013;54:2025-35.
  14. Chang EF, Gabriel RA, Potts MB, Garcia PA, Barbaro NM, Lawton MT. Seizure characteristics and control after microsurgical resection of supratentorial cerebral cavernous malformations. *Neurosurgery*. 2009;65:31-7; discussion 7-8.
  15. Poorthuis M, Samarasekera N, Kontoh K, Stuart I, Cope B, Kitchen N, et al. Comparative studies of the diagnosis and treatment of cerebral cavernous malformations in adults: systematic review. *Acta neurochirurgica*. 2013;155:643-9.
  16. San-Juan D, Díaz-Nuñez IC, Ojeda-Baldéz M, Barajas-Juárez VA, González-Hernández I, Alonso-Vanegas M, et al. Utility of electrocorticography in the surgical treatment of cavernomas presenting with pharmaco-resistant epilepsy. *Epileptic Disord*. . 2014;16:245-60.
  17. Gross BA, Batjer HH, Awad IA, Bendok BR, Du R. Brainstem cavernous malformations: 1390 surgical cases from the literature. *World Neurosurg*. 2013;80:89-93.
  18. Akers A, Al-Shahi Salman R, I AA, Dahlem K, Flemming K, Hart B, et al. Synopsis of Guidelines for the Clinical Management of Cerebral Cavernous Malformations: Consensus Recommendations Based on Systematic Literature Review by the Angioma Alliance Scientific Advisory Board Clinical Experts Panel. *Neurosurg*. 2017;80:665-80.
  19. Lu XY, Sun H, Xu JG, Li QY. Stereotactic radiosurgery of brainstem cavernous malformations: a systematic review and meta-analysis. *J Neurosurg*. 2014;120:982-7.
  20. Shanker MD, Webber R, Pinkham MB, Huo M, Olson S, Hall B, et al. Gamma Knife® stereotactic radiosurgery for intracranial cavernous malformations. *J Clin Neurosci*. 2022;106:96-102.
  21. Cornelius JF, Kürten K, Fischer I, Hänggi D, Steiger HJ. Quality of Life After Surgery for Cerebral Cavernoma: Brainstem Versus Nonbrainstem Location. *World Neurosurg*. 2016;95:315-21.
-